

Precocious Puberty Associated with an Adrenal Tumor: A case report

Zahra Razavi MD^{1, 2,*}, Alireza RastgooHaghi MD²

1. Associated Professor, Pediatric Endocrinologist, Pediatrics Department, Besat Hospital, Hamedan University of Medical Sciences, Hamadan, Iran

2. Assistant Professor Pathology Department, Besat Hospital,,Hamedan University of Medical Sciences, Hamadan, Iran

Corresponding author: Zahra Razavi, M.D. Pediatrics Department, Besat Hospital, Motahari Boulevard, Resalat Square, Hamedan, Iran. Email: razavi.zahra@rocketmail.com

Received: 25 May 2015

Accepted: 9 September 2015

Abstract

Adrenocortical tumors (ACTs) are extremely rare in infants. Pediatric ACTs are therapeutic and diagnostic challenge because histological criteria for distinguishing benign from malignant tumors seen in adults are not always reliable in children .The aim of this report was to present clinical features, hormonal profile, and histopathological characteristics of an infant with Adrenal tumors.

A 10-month-old boy with adrenocortical tumors (ACT) presented with restlessness and pseudoprecocious puberty. Plasma testosterone, dehydroepiandrosterone, and 17-OH progesterone were increased. An abdominal spiral computed tomography (CT) scan with intravenous contrast identified a well-defined left-sided suprarenal mass with areas of necrosis. Left adrenalectomy was performed. Immunohistochemical staining showed that tumor cells were strongly positive with inhibin and focal positive with vimentin. The diagnosis of adrenocortical carcinoma was made on the basis of immunohistochemistry. The postoperative course was uneventful.

This case emphasizes the importance of early consideration of an adrenocortical tumors causing pseudoprecocious puberty in infant. The final pathologic diagnosis should be based on imunohistochemical staining patterns.

Keywords: Adrenal Tumor, Adrenocortical carcinoma, Imunohistochemical staining, Pseudoprecocious puberty

Introduction

Adrenocortical tumors are rarely encountered in children. They constitute only about 0.2% of all pediatric neoplasms and account for 6% of all adrenal tumors in 0-21 y age group (1, 2). However, their incidence appears to vary substantially across different geographical areas. In Europe and the United States, the annual incidence of childhood adrenocortical tumor (ACT) ranging from 0.3–0.38 cases per million children. However, it is unusually high in southern Brazil, wherein it is about 10-15 times higher than that of pediatric ACT worldwide (3, 4). Different from those in adult, most pediatric adrenocortical tumors cause clinical signs. The most common presenting sign (Approximately 50-84.2%) is peripheral

Precocious puberty with or without Cushing syndrome (5-7). Because of the rarity of pediatric adrenocortical tumors, clinical courses, management, and therapy responses of these tumors are not well characterized. Although the most important point to be defined in pediatric age with an ACT is whether the mass is benign or malignant, the standard histopathological criteria of malignancy used in adults may not be reliable predictors for biologic behavior, recurrence, and outcome of pediatric ACTs (8). In this paper, a 10-month-old boy with adrenocortical tumor was presented as pseudoprecocious puberty. Other cases in the literature were also reviewed to raise awareness of potential diagnosis of

adrenocortical carcinoma in all infants with pseudoprecocious puberty.

Case presentation

A 10-month-old male infant was referred to Besat Hospital pediatric Endocrinology Clinic with complaints of restlessness and premature pubarche two month ago. The infant was the second child of healthy, non-consanguineous parents. He was born at term, after an uneventful pregnancy. At birth, His weight was 3400 g and the appearance of the genitalia was normal male. His neonatal, past and family medical history was unremarkable. A maternal history of hyperandrogenism was absent. His mother described that the infant had restlessness from 2 months age and had been frequently visited by physicians. Then, he gradually developed sexual pubic hair at the age of 8 months.

On physical examination, he was healthy appearing with an increase in facial hair, acne, and seborrhea dermatitis and protruding abdomen. There was no palpable abdominal mass. No other morphologic anomaly was found. The infant's body length was 72 cm (25th percentile) and his weight was 9.2 kg (25th percentile). His blood pressure was normal. Genital examination revealed mildly enlarged penis (penile length was 5.5 cm and; the width was 1.5cm) without testicular enlargement. Pubarche was Tanner stage 3.

Laboratory studies, including serum aldosterone, potassium, renin activity, uric acid, glucose, urine vanillyl mandelic acid (VMA), and urine homovanillic acid (HVA) levels were all in normal range. However, plasma levels of testosterone DHEA-S and 17-OH progesterone were high with mild hypercortisolism (Table I). Radiological imaging revealed normal scrotal ultrasonography (US). Whereas, abdominal US revealed a 67x64 x63mm hypoechoic mass with microcalcification on left side displacing

the left kidney inferiorly. An abdominal spiral computed tomography (CT) scan with intravenous contrast was performed showing a 79 x64 x 69 mm well-defined left-sided suprarenal mass with areas of necrosis. The origin of the mass was unclear. The patient underwent Laparotomy and tumor was completely resected with left adrenalectomy. Laparotomy revealed a left adrenal mass with an intact capsule and size 6.7cm weighing 230 g (Figure 1a). Histopathologically, the tumor was composed of polygonal cells with pleomorphic vesicular nuclei, occasionally prominent nucleoli and eosinophilic granular cytoplasm arranged in solid sheets and thick trabecular pattern. Focal areas of bizarre nuclei, multinucleated giant cells and necrosis were observed. Obviously, there was no evidence of capsular and vascular invasion (Figure 1b). Immunohistochemical staining (IHC) showed that tumor cells were positive for Vimentin and negative for Cytokeratin (Figure 1c,d). Based on these findings, the tumor histology was consistent with adrenocortical carcinoma. In accordance with 2013 Tumor Nodes Metastasis staging system, the tumor stage was T2N0M0. Postoperative period was uneventful and he was discharged on the 4th postoperative day. The infant is currently being followed up by endocrinologist and oncologist with regular hormone level assay and imaging study. In the postoperative second week, total testosterone level was 0.12 ng/ml, and 17-hydroxyprogesterone (17-OHP) level was 0.87 ng/ml and DHEA-S <0.1. Cortisol level returned to normal levels within 40 days following tumor resection. (1600 µg/ml :normal range 50-230 ng/ml). The patient was doing well and according to chest, abdominal CT and hormonal assay, he did not exhibit signs of tumor recurrence at the 4-month follow-up.

Table I. Pre-operative laboratory data of the present case

		Normal
Blood glucose	102mg/dL	
Sodium	141mEq/L	
Potassium	4.4	
LDH	2296	225-480
Testosterone	10.23 ng/ml	<2.49
17-OH progesterone	9.38	0.2-0.9ng/ml
Cortisol	355ng/ml(Method:ECL. Normal:50-230)	50-230
DHEA-SO4	>27 μ mol/L Method:ECL	2.0-61
Beta-HCG	Negative	0.0-5.0

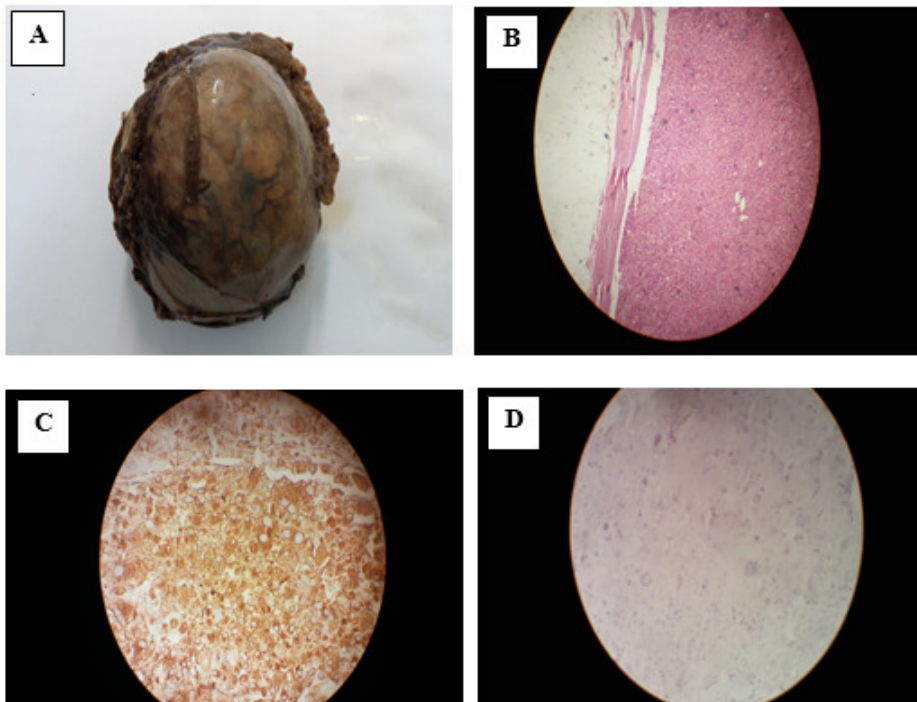


Figure1. A: Gross image of the tumor comprising the adjacent left adrenal, B: a diffuse proliferation of large, polygonal and eosinophilic neoplastic cells, C: Immunohistochemical results :all tumoral cells were immunireactive for vimentin and D: The tumoral cells were negative for cytokeratin

Discussion

Upon the review of the published literature, it seems that pediatric ACTs are heterogeneous and their management is still challenging because of the limited number of cases. Virilization is an important clue to the diagnosis of ACT (7, 9). This was a feature in the present case and his hormonal assay confirmed functioning adrenal tumor. This is consistent with other reports in the literature (10, 11). Kojh et al reported one-year-old girl who was diagnosed with Turner syndrome and virilizing adrenocortical tumor presented pubic hair and clitoromegaly. She was found to have a de novo TP53 gene mutation as well as a 45, X karyotype (12). Ghazizade et al described a two-years-old girl with right adrenal adrenocortical carcinoma presenting with virilization since birth (13). However, hormone secretion is not a discriminating feature between benign and malignant adrenocortical masses (2, 10). In this case, linear growth was normal and growth-promoting effect of androgen was not observed. It can be due to early diagnosis of tumor prior to result in increased transient linear growth, it also may be due to mild cortisol excess.

Evaluation of the cases published in literature indicates that ACT incidence is higher in female than male, particularly in those aged between 0-3 years and over 13 years (5, 6, 14). In the paper published by Michalkiewicz et al, girls predominated in the age groups of 0 to 3 years (ratio, 1.7:1) (5).

Appropriate treatment remains a continuing challenge in pediatric ACC. Total excision is the mainstay of treatment. For localized disease, surgery alone remains the only potentially curative therapeutic modality (2, 5, and 15). Accordingly, the patient underwent laparotomy and tumor was completely resected with left adrenalectomy. The role of radiotherapy and efficacy of adjuvant therapy including mitotane in pediatric have not been well defined and most

investigators did not demonstrate any improvement in outcome with chemotherapy (10, 11). There is agreement that clinical, laboratory, histopathological features, and biologic behavior of pediatric ACTs is quite different from their similar counterparts in the adult population (8). It is clear that unlike adult ACTs, the majority of pediatric patients have had clinically benign disease. This may be due to the fact that these tumors in early years of life arise from fetal adrenocortical cells with limited malignant potential (5). Additionally, the histological criteria for distinguishing benign from malignant tumors used in adults are not always reliable in children (2, 8, 15, and 16).

Based on previous related studies, tumor size is the most important prognostic factor (5, 6, 17). A report from Hanna et al found that all malignancies were more than 2.5 cm and mean tumors weight was 109 g. Pather S et al reported that histopathological features associated with poor prognosis included tumor weight >500 g and size >10.5 cm, while other investigators claim histological grade is more important (18). Mayer SK et al are more optimistic and believe that good prognosis can be expected with total excision, even about tumors larger than 5 cm (19). By contrast, Magro et al failed to confirm these findings (14).

The patient was diagnosed at the age of 10 months presented with virilization. He was found to have resectable tumor. Although, a poor prognostic factor was his tumor weight 230g with regard to age, male sex, clinical presentation, disease stage I and having resectable tumor, he could have favorable prognosis (20, 21).

Obviously, particular attention should be paid for monitoring of patients with ACT. Initially, abdominal CT or MRI plus chest CT should be performed every 3 months for the first two years. Imaging intervals may lengthen thereafter. Similarly, periodic checks of hormonal profiles are recommended initially every 3 months

during the first 2 yr, then every 6-12 months for at least 5 yr (22).

Conclusion: The importance of comprehensive evaluation of infant with precocious puberty is highlighted in the current study. The final diagnosis should be based on clinical manifestations, laboratory data, imaging, and pathology.

Conflict of interest

The authors declare no conflict of interest in this case report or in the production of this manuscript.

Acknowledgments

The authors thank Dr. Ghorbanpoor M. for providing laparotomy data. We also wish to thank the patient's parents for their valuable cooperation.

References

1. Shirata NK, Sredni ST, Castelo A, Santinelli A, Mendonça B, Montironi R, et al. Texture image analysis in differentiating malignant from benign adrenal cortical tumors in children and adults. *Anticancer Res*. 2009 Aug;29(8):3365-8
2. Ciftci AO, Senocak ME, Tanyel FC, Büyükpamukçu N. Adrenocortical tumors in children. *JPediatr Surg*. 2001 Apr;36(4):549-54
3. Ribeiro R, Figueiredo B. Childhood adrenocortical tumours. *Eur J Cancer*. 2004;40:1117-26
4. Figueiredo BC, Sandrini R, Zambetti GP, Pereira RM, Cheng C, Liu W, et al. Penetrance of adrenocortical tumours associated with the germline TP53 R337H mutation. *J Med Genet*. 2006;43(1):91-6. Epub 2005 Jul 20
5. Michalkiewicz E, Sandrini R, Figueiredo B, Miranda EC, Caran E, Oliveira-Filho AG, et al. Clinical and outcome characteristics of children with adrenocortical tumors: a report from the International Pediatric Adrenocortical Tumor Registry. *J Clin Oncol*. 2004;22(5):838-45.
6. Chen QL, Su Z, Li YH, Ma HM, Chen HS, Du ML. Clinical characteristics of adrenocortical tumors in children. *JPediatr Endocrinol Metab*. 2011;24(7-8):535-41
7. Cacciari E, Cicognani A, Pirazzoli P, Paolucci G, Mancini A, Tassinari D, et al. Adrenocortical tumours in children: our experience with nine cases. *Acta Endocrinol Suppl (Copenh)*. 1986;279:264-74
8. Erickson LA, Rivera M, Zhang J. Adrenocortical carcinoma: review and update. *Adv Anat Pathol*. 2014;21(3):151-9
9. Mittal R, Ramadan DG, Khalifa NM, Khalifa SO, Mazidi Z, Zaki M. Adrenocortical tumors in children: a Kuwait experience. *Gulf J Oncolog*. 2012;(12):38-46
10. Almarzouq A, Asfar S, Hussain S, Al-Hunayan A, Aldousari S. Giant nonfunctioning adrenocortical carcinoma: a case report and review of the literature. *BMC Res Notes*. 2014 ;31(7):769.
11. Hanna AM, Pham TH, Askegard-Giesmann JR, Grams JM, Iqbal CW, Stavlo P, et al. Outcome of adrenocortical tumors in children. *JPediatr Surg*. 2008;43(5):843-9
12. Ko JH, Lee HS, Hong J, Hwang JS. Virilizing adrenocortical carcinoma in a child with Turner syndrome and somatic TP53 gene mutation. *Eur J Pediatr*. 2010;169(4):501-4
13. Ghazizadeh F, Ebadi M, Alavi S, Arzanian MT, Shamsian B, Jadali F. Adrenocortical carcinoma presenting with heterosexual pseudoprecocious puberty shortly after birth: case report and review. *Ecancer medical science*. 2013; 7: 289.
14. Magro G, Esposito G, Cecchetto G, Dall'Igna P, Marcato R, Gambini C, et al. Pediatric adrenocortical tumors: morphological diagnostic criteria and immunohistochemical expression of matrix metalloproteinase type 2 and human leucocyte-associated antigen (HLA) class II antigens. Results from the Italian Pediatric Rare Tumor (TREP)

- Study project. *HumPathol.* 2012;43(1):31-9.
15. Schulick RD, Brennan MF. Long-term survival after complete resection and repeat resection in patients with adrenocortical carcinoma. *AnnSurgOncol.* 1999;6(8):719-26
16. Wieneke JA, Thompson LDR, Heffess CS. Adrenal cortical neoplasms in the pediatric population: A clinicopathologic and immunophenotypic analysis of 83 patients. *Am J SurgPathol.* 2003;27:867-81.
17. Dehner LP, Hill DA. Adrenal cortical neoplasms in children: why so many carcinomas and yet so many survivors?. *PediatrDevPathol.* 2009;12(4):284-91.
18. Pather S, Rowe B, BylDV. Adrenal cortical carcinoma in a child, a rare cause of paediatric endocrinopathy: case report and literature review. *FetalPediatrPathol.* 2013;32(4):259-64.
19. Mayer SK, Oligny LL, Deal C, Yazbeck S, Gagné N, Blanchard H. Childhood adrenocortical tumors: Case series and reevaluation of prognosis—A 24-year experience. *Journal of Pediatric Surgery*, 1997; 32 (6): 911-915.
20. McAteer JP, Huaco JA, GowKW. Predictors of survival in pediatric adrenocortical carcinoma: a Surveillance, Epidemiology, and End Results (SEER) program study. *JPediatr Surg.* 2013;48(5):1025-31. doi: 10.1016/j.jpedsurg.2013.02.017.
21. Rodriguez-Galindo, C, Figueiredo, B.C., Zambetti, G.P, Ribeiro, R.C. Biology, clinical characteristics, and management of adrenocortical tumors in children (Review). *Pediatric Blood and Cancer* 2005;45, (3): 265-273
22. Allolio B, Fassnacht M. . Clinical review: Adrenocortical carcinoma: clinical update. *JClinEndocrinolMetab.* 2006;91(6):2027-37.