

## Primary kaposiform hemangioendothelioma of ulna

Sami Sam Hajjaliloo MD<sup>1</sup>, Azra Izanloo MSc<sup>2</sup>, Masoud Mirkazemi MD<sup>1,\*</sup>

1. Bone and Joint Reconstruction Research Center, Shafa Orthopedic Hospital, Iran University of Medical Sciences, Tehran, Iran.

2. Razavi Cancer Research Center, Razavi Hospital, Imam Reza International University, Mashhad, Iran

\*Corresponding author: Dr Masoud Mirkazemi, MD, Bone and Joint Reconstruction Research Center, Shafa Orthopedic Hospital, Iran University of Medical Sciences, Tehran, Iran. E-mail: masoud.dr2003@gmail.com.

Received: 07 November 2018

Accepted: 25 December 2018

### Abstract

Kaposiform hemangioendothelioma (KHE) is a rare vascular neoplasm that can be potentially low malignant and mainly affects infants and adolescents. This tumor usually is seen in the skin, soft tissue, and retroperitoneum. This study is a case of KHE in the long bone of the ulna. The subject was a 7-year-old female patient with osteolytic lesion in the forearm without cutaneous lesions. Histologically, the neoplasms comprised of nodules of spindle-to oval-shaped cells that grew in an infiltrative fashion. The results of 2-year follow-up of the patient after en bloc resection were desirable and no recurrence was observed. This is the first study to report a case of KHE of the bone in Iran.

**Keywords:** Bone, Hemangioma, Hemangioendothelioma, Kaposiform

### Introduction

Primary neoplasms of the liver are rare in Kaposiform hemangioendothelioma (KHE) was first introduced by Zukerberg (1) in 1993 as a rare aggressive vascular tumor in infancy and early childhood. World Health Organization classifies KHE as a vascular neoplasm of intermediate malignancy because the pattern has local infiltrate growth, and low-grad histomorphological manifestations (2, 3) The tumor mainly affects skin and soft tissue (75%) but it sometimes occurs in retroperitoneum (about 18%) (4). To the best of our knowledge, about eight cases of KHE mass in bones have been reported (4-6). Out of which only four cases were in extra craniofacial area, including humerus (4, 5), ulna and radius (6), and femoral (4). The aim of the present study was to report KHE in the forearm.

### Case report

The patient was a 7-year-old girl who suffered from stiffness in the forearm and aggressive mass, which had lasted for six months. She referred to outpatient clinic in Tehran, Iran (2014). In the clinical

examination, no sign of overlying skin, erythema, or discoloration was observed. However, a little tenderness of mass was noticed. In the radiography, the bony lesion of proximal ulna with bone trabeculation and degradation of cortex, and periosteal reaction were observed with soft tissue extension (Figure 1). The routine blood investigation was normal. Lung CT Scan was normal. Bone scan with MDP-TC showed high uptake in tumor local; and metastasis was not found. The patient underwent open incisional biopsy; and aneurysmal bone cyst was reported, which was not fully compatible with the radiologic view. The en bloc resection of the lesion with him cortical resection and curettage performed for the patient while pathological results confirming KHE. The tumor was characterized by infiltrative irregular nodules and oval cells growing in a dense hyaline stroma. Nodules comprised of a mixture of small, round, and capillary-sized vessels which were supported by large feeder blood vessels. In some areas, vessels resembled a capillary hemangioma.

There were fascicles of spindle cells with slit-like blood vessels within it, which were reminiscent of Kaposi sarcoma (Figure 3). Scattered epithelioid or glomeruloid nests include cells with abundant eosinophilic granular cytoplasm, hemosiderin, and small vacuoles. Cytologic atypia was slight and mitotic activity was weak. Since the surgery margin of tumor was not contaminated, no other adjuvant therapy was considered for the patient. In the 2-years follow-up, the patient did not reveal any symptoms of local recurrence and distance metastatic.

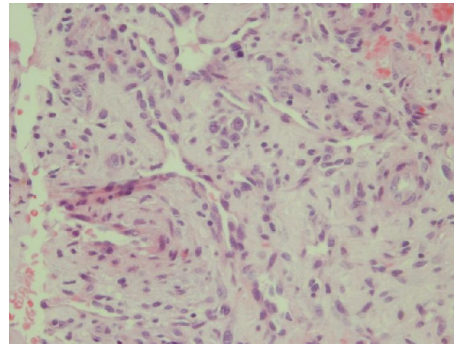


Figure 3. Characteristic appearance of KHE with attenuated vessels and slit-like openings that resemble Kaposi sarcoma (H&E, ×400).

### Discussion

KHE is a local invasive tumor which is often arising from the skin or soft tissue, especially in childhood (7). In the present case, the tumor appeared primarily in the forearm without any skin changes. Radiography depicted lytic lesion with periosteal reaction, which was similar to chondroblastoma. In most cases, radiographic images display expansile mass with ill-defined margins, which often penetrate the adjacent soft tissue (8). It is said that T2-weight images in MRI reveal KHE in a range of high to intermediate signal intensity; whereas, T1-weight images display low intensity. The imaging modality of choice is for vascular tumors of the head and neck (9). Since the MRI of the present case showed a similar view, it can be recommended as imaging modality choice for KHE of bone. As we know, ABC can develop secondary to other tumors. So, KHE can be misdiagnosed as ABC. It can be even seen with the KHE pathology lam. Histologically, the initial biopsy reported aneurysmal bone cyst which was incompatible with radiography, but in the biopsy after en bloc resection, the tumor was reported with infiltrative nodules of tightly-packed primitive vessels, which were reminiscent of capillary hemangioma along with slit-like blood vessels, indicating Kaposi sarcoma.

It should be noted that bone KHE could be misdiagnosed as juvenile hemangioma,

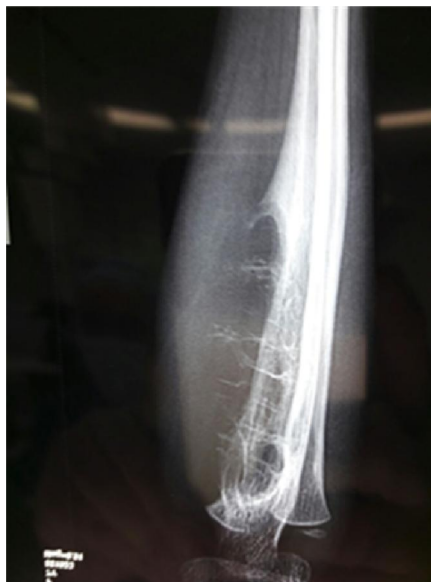

Figure 1. X-ray image showing bone tumor in ulna that destructs the one cortex and fine bony trabeculation the extend to soft tissue.

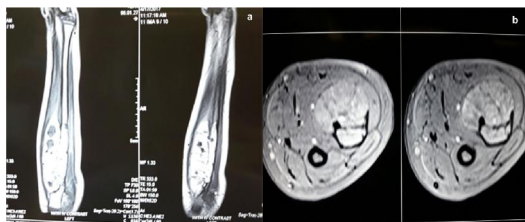


Figure 2. In axial and coronal MRI, the heterogeneous lesions of hyper intense signal in T1 and T2 were more consistent with vascular mass.

which is one of most common vascular tumor of bone (10). One of great challenges of KHE is its treatment. So far, KHE treatment has been limited because of the relative rarity of this neoplasm. The follow-up of patients with KHE has shown that complete surgical excision of tumors, if possible, is the most effective treatment, especially in patients who have not responded to drug treatment (11). In the present case, surgical treatment was also effective for the patient. In general, this paper reported a case of KHE in the long bone in form of an initial mass without skin changes or dependence on Kasabach-Merritt phenomenon in a young girl with a two-year follow-up. The patient was treated with en bloc resection and the results were satisfactory. Accordingly, it is recommended to pay attention to Kasabach-Merritt phenomenon which is characterized by thrombocytopenia, microangiopathic hemolytic anemia, and mild consumptive coagulopathy and associated with KHE. KHE with KMP has a high mortality rate of up to 50%. (12), but it has not been seen in KHE of limbs yet. Metastatic events can be also the cause of death.

## Conclusion

KHE is a rare vascular of bone. Given that ABC can be developed secondary to other tumors, KHE can be misdiagnosed as ABC. It can be even seen with the KHE pathology lam. It is recommended to that decision about this tumor is based on imaging and clinical symptoms. Multiple biopsies from different tumor sites can be done, If needed.

## Conflicts of interest

The authors declare no conflict of interest.

## References

1. Zukerberg LR, Nickoloff BJ, Weiss SW. Kaposiform hemangioendothelioma of infancy and childhood. An aggressive neoplasm associated with Kasabach-Merritt syndrome

and lymph angiomas. *Am J Surg Pathol* 1993; 17: 32-8.

2. Weiss SW, Goldblum JR. *Enzinger and Weiss's Soft Tissue Tumors*. 4th ed. St Louis. MO: Mosby; 2001.

3. Fletcher CDM, Unni KK, Mertens F. *Pathology and Genetics of Tumors of Soft Tissue and Bone*. Lyon: IARC Press; 2002.

4. Ma J, Shi QI, Jiang ShJ, Zhou HB, Zhou XJ. Primary kaposiform hemangioendothelioma of a long bone: Two cases in unusual locations with long-term follow up. *Int Pathol* 2011; 61: 382-386.1 382.

5. Mac-Moune Lai F, To KF, Choi PC, Leung PC, Kumta SM, Yuen PP, et al. Kaposiform hemangioendothelioma: Five patients with cutaneous lesion and longfollow-up. *Mod Pathol* 2001; 14: 1087-92.

6. Lai FM, Allen PW, Yuen PM, Leung PC. Locally metastasizing vascular tumor: Spindle cell, epithelioid, or unclassified hemangioendothelioma. *Am J Clin Pathol* 1991; 96: 660-63.

7. Drolet BA, Trenor CC, Brandão LR, Chiu YE, Chun RH, Dasgupta R, et al. Consensus-derived practice standards plan for complicated Kaposiform hemangioendothelioma. *J Pediatr* 2013; 163(1): 285-291.

8. Lee C.H, Jaw T.S, Yang S.F, Wu D.K. Kaposiform hemangioendothelioma arising from the maxillary sinus: a case report. *Kaohsiung J Med Sci* 2010; 26(3): 154-157.

9. L.K. Wonga B, N.Y. Lee V, Tikka T, Kimd D, Dwivedi R. Kaposiform haemangioendothelioma of the head and neck. *Crit Rev Onco Hematol* 2016; 104: 156-168.

10. Lyons LL, North PE, Mac-Moune Laiw F, Stoler MH, Folpe AL, Weiss SW. Kaposiform hemangioendothelioma: a study of 33 cases emphasizing its pathologic, immunophenotypic, and biologic uniqueness from juvenile hemangioma. *Am J Surg Pathol* 2004;28:559-68

11. Jiang R.S, Hu R. Successful treatment of Kasabach-Merritt syndrome arising from kaposiform hemangioendothelioma by systemic corticosteroid therapy and surgery. *Int J Clin Oncol* 2012; 17:512-516.

12. Subash A, Senthil G, Ramamoorthy R, Appasamy A, Selvarajan N. Kaposiform hemangioendothelioma with Kasabach-Merritt phenomenon in a neonate of life- and limb-threatening nature: A case report. *J Indian Assoc Pediatr Surg* 2015; 20(4): 194-196.