

Case Report

Malignant Lymphoma of Lacrimal Apparatus in the 7 Year Old Girl

Besharati MR MD¹, Taghipour Zahir S MD², Hashemi A MD³, Eshaqhiyeh Z MD⁴

- 1- Department of Ophthalmology, Shahid Sadoughi university of medical sciences, Yazd, Iran
- 2- Department of pathology, Shahid Sadoughi university of medical sciences, Yazd, Iran
- 3- Department of Pediatrics, Hematology, Oncology and Genetics Research Center, Shahid Sadoughi University of Medical Sciences and Health Services, Yazd, Iran.
- 4- Medical student

Received: 5 July 2011
Accepted: 24 October 2011

Abstract

Background

Involvement of lacrimal apparatus by Non Hodgkin lymphoma as a first manifestation is extremely rare and only three cases have been reported in children. The purpose of this report is to determine the clinical characteristic of patient with primary involvement of lacrimal apparatus with lymphoma.

Case presentation

A 7-year-old girl with history of tearing, gradually progressive periorbital redness and painless swelling over right lacrimal apparatus for almost 40 days was referred for treatment in our clinic. Orbital computed tomography revealed lacrimal apparatus mass. Histopathological examination demonstrated B cell type NHL. Following three cycles of cyclophosphamide, doxorubicin hydrochloride, vincristine and prednisone (CHOP regimen) and radiotherapy, the patient was discharged with good condition.

Conclusion

Although, the primary lacrimal apparatus lymphoma is extremely rare in children but malignant lymphoma should be taken under consideration in acute dacriocystitis.

Keywords

Lymphoma, Non-Hodgkin, Orbit, Lacrimal Apparatus, Dacryocystitis

Correspondence Author

Shokouh Taghipour Zahir ,AP,CP

Email: shokouh_zahir@yahoo.com

Address: Shahid Sadoughi general hospital, pathology ward, Yazd, Iran

Tel:00983518113615

Mobile: 00989133531471

Introduction

The lacrimal excretory system is prone to infection and inflammation for various reasons. Acute dacryocystitis is heralded by the sudden onset of pain and redness and swelling in the medial canthal region (1). Acquired dacryocystitis is primarily a disease of females and is most common in patients older than 40 years. The etiology of dacryocystitis includes many causes but Leukemic infiltration is very rare especially in children (2). Overall, 55% of lacrimal sac tumors are malignant including epithelial (%75) and nonepithelial (%25) tumors (3). Herein we describe a child with involvement of lacrimal apparatus and paranasal sinus with Non Hodgkin's lymphoma as first manifestation of the disease.

Case report

A 7-year-old girl presented with one month history of tearing and gradually progressive periorbital redness and painless swelling over right lacrimal sac similar to acute dacryocystitis. Patient didn't complain any itching, discharge or blurred vision. She was prescribed systemic antibiotic by a ophthalmologist 2 weeks before of attendance in our clinic. Then she was referred to hospital due to non significant clinical improvement. Ocular examination showed pattern of right acute dacryocystitis with painless, red swelling of periorbita most prominent over lacrimal sac and medial canthal tendon. In palpation a relative firm irregular mass detected from below medial canthal tendon to malar region (Fig.1A). She didn't have purulent discharge and regurgitation test was negative. Only positive Systemic examination finding was palpable lymphadenopathy in anterior cervical chain. Orbital computed tomography revealed significant enlargement of soft tissue in anteromedial aspect of right orbit and inferior eyelid which cause mini lateral displacing the globe without bony erosion (Fig.1B).

She underwent incisional biopsy of Lacrimal sac region. Received specimen consists of one piece of cream coloured tissue Measuring 4x2x2 cm .Microscopic examination shows tumoral lesion composed of neoplastic cells which have a round hyperchromatic nuclei with variation in size both small and medium size and irregular nuclear borders. The neoplastic cells invaded bundles of skeletal muscle tissue with perineural invasions. Large areas of necrosis with numerous mitotic figures were presented (Fig.1C). Neoplastic cells were positive for CD20 and CD45 and negative for desmin, CD30, and CD15. So based on H&E staining method and immunohistochemical findings the final diagnosis was malignant lymphoma, B cell type. Complete blood count revealed anemia (Hb:10,3 gr/dl), WBC:6700, Plt:350,000 per μ l. other laboratory tests and abdominal sonography were normal. Chest CT showed two sub pleural opacity due to lung involvement. In bone marrow aspiration neoplastic lymphoid cells were not seen. The patient was managed by 3 cycles of CHOP chemotherapy regimen. 14 days after surgery, fistula formation detected in medial canthal area (Fig.1D). CT scan of paranasal sinuses showed, diffuse homogenous opacity of the right maxillary sinus and involving bilateral ethmoidal air cells. Fistula sealed during chemotherapy without any special medication.

Discussion

In acquired dacryocystitis, obstruction of the lower part of the nasolacrimal system frequently is present. Pathologic changes found in the lacrimal apparatus are related primarily to the etiology of the disease. A number of different malignant processes can involve the lacrimal sac but are unusual, and lymphomas of the lacrimal sac are quite rare (4). Less than 5% of non-Hodgkin's lymphoma occurs initially in the orbit (5). Majority of lymphomas involving the lacrimal sac are secondary to systemic lymphoreticular malignancy (6). Karesh et al. reported four cases with a history of well-differentiated, small cell lymphoma or chronic

lymphocytic leukemia presented with either acute or chronic dacryocystitis or epiphora due to lymphomatous infiltration of the lacrimal sac. All patients underwent both dacryocystorhinostomy with lacrimal sac biopsy and histopathology evaluation (7). Different manifestation of primary lacrimal sac lymphoma is epiphora, painless swelling, recurrent mass and dacryocystitis. Our case differed in that; she had acute symptom simulating acute dacryocystitis and involvement of paranasal sinuses. To date, in three reported cases primary non-Hodgkin's lymphoma of lacrimal apparatus had been described in children (8-10). Our patient is the youngest case of primary lacrimal sac lymphoma that reported. In a similar study, De Palma et al. reported the case of a 72-year-old woman with diffuse large B-cell lymphoma of the lacrimal sac. An acute infectious etiology was suspected and antibiotic therapy was given. When she finally presented with a rapidly growing lesion, she underwent echography and computed tomography followed by incisional biopsy. Results of histopathology and immunohistochemical evaluation showed a primary, diffuse, large B-cell non-Hodgkin lymphoma of the lacrimal sac, but his case was too old compared to our (11). Abrishami et al report a 35 years old female with presentation of Lacrimal drainage obstruction as an early presentation of lacrimal sac lymphoma, (12) but it was different in age and presentation with our case. In addition, Yip CC et al. reported that Biopsies of the lacrimal sac obtained during dacryocystorhinostomies (DCR) were positive for leukemia or lymphoma in 11 patients (15 LDS). Ten patients had previously diagnosed leukemia or lymphoma; the interval between the diagnosis of systemic disease and DCR averaged 5.8 years. The median age at the time of LDS involvement was 72 years (range, 49 to 85 years). Its survey was different with our study in age, presentation and management (13).

Conclusion

Although, the primary lacrimal sac lymphoma is extremely rare especially in childhood, but we should consider malignant lymphoma as differential diagnosis in few acute dacryocystitis with non specific characteristic presentation.

References

1. Kanski Jack J. clinical Ophthalmology A Systematic Approach 6th ed. Butterworth Heinemann Elsevier 2007; 163-164.
2. Skuta G L, Cantor B, Weiss S. Basic and clinical science course. section 7. Orbit, Eyelids, and Lacrimal system. San Francisco American Academy of Ophthalmology . 2009-2010; 294-295.
3. Montalban A, Liétin B, Louvrier C, Russier M, Kemeny JL, Mom T, et al. Malignant lacrimal sac tumors. Eur Ann Otorhinolaryngol Head Neck Dis. 2010Nov;127(5):165-72.
4. Ryan SJ, Font RL. Primary epithelial neoplasms of the lacrimal sac. Am J Ophthalmol. 1973 Jul;76(1):73-88.
5. Gilchrist GS. Lymphoma. In: Behrman RE, Kliegman RM, Jenson HB. Nelson Textbook of Pediatrics. 16th ed. Philadelphia, Pa: WB Saunders & Co; 2000:1548-1552.
6. Flanagan JC, Stokes DP. Lacrimal sac tumors. Ophthalmology. 1978 Dec;85(12):1282-7.
7. Karesh JW, Perman KI, Rodrigues MM. Dacryocystitis associated with malignant lymphoma of the lacrimal sac. Ophthalmology. 1993 May;100(5):669-73.
8. Köksal Y, Kiratli H, Varan A, Akçören Z, Büyükpamukçu M. Primary lacrimal sac non-Hodgkin's lymphoma in a child. Int J Pediatr Otorhinolaryngol. 2005 Nov;69(11):1551-3.
9. Carlin R, Henderson JW. Malignant lymphoma of the nasolacrimal sac. Am J Ophthalmol. 1974 Sep;78(3):511-3.
10. Scheffler AC, Shields CL, Shields JA, Demirci H, Maus M, Eagle RC Jr. Lacrimal sac lymphoma in a child. Arch Ophthalmol. 2003 Sep;121(9):1330-3.
11. de Palma P, Ravalli L, Modestino R, Grisanti F, Casillo F, Marzola A. Primary lacrimal sac B-cell immunoblastic lymphoma simulating an acute dacryocystitis. Orbit. 2003 Sep;22(3):171-5.
12. Abrishami M, Aletaha M, Bagheri A and Salour H. Lacrimal drainage obstruction as an early presentation of lacrimal sac lymphoma. Bina J Ophthalmol 2006; 11(3): 391-396.
13. Yip CC, Bartley GB, Habermann TM, Garrity JA. Involvement of the lacrimal apparatus by leukemia or lymphoma. Ophthal Plast Reconstr Surg. 2002 Jul;18(4):242-6.

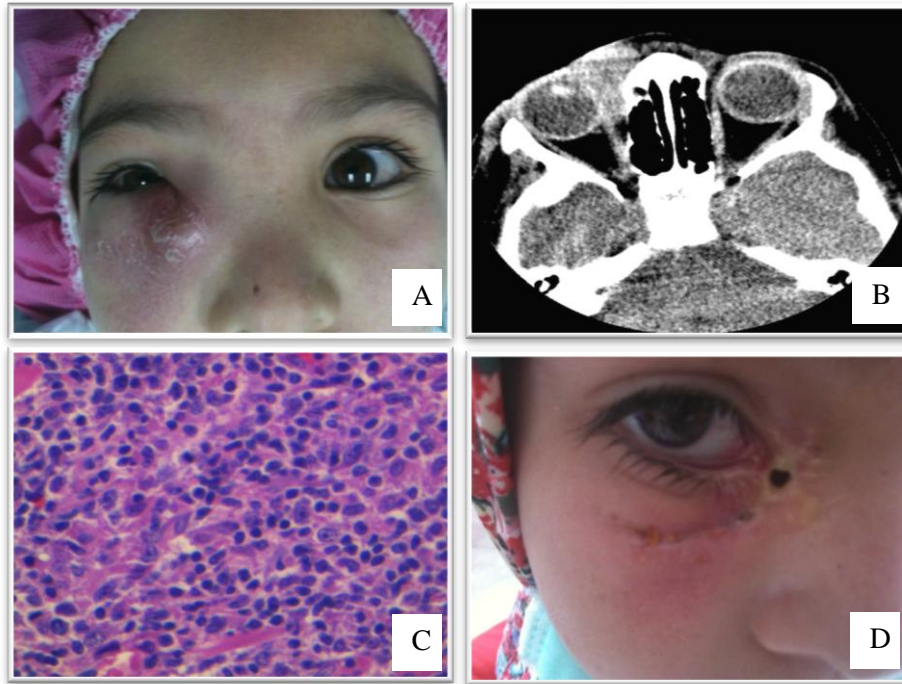


Fig1:A 7-year-old girl with primary malignant lymphoma of lacrimal apparatus. (A) a relative firm irregular mass below medial canthal tendon to malar region.(B) computerised tomograph of the orbit showing significant enlargement of soft tissue in anteromedial aspect of right orbit and inferior eyelid which cause mini lateral displacing the globe without bony erosion.(C) neoplastic cells with a round hyperchromatic nuclei with variation in size both small and medium size and irregular nuclear borders.(D)14 days after surgery, fistula formation detected in medial canthal area.