

## Case Report

### Large Meningioma in an Infant

Binesh F MD<sup>1</sup>, Aghili K MD<sup>2</sup>, Navabii H MD<sup>3</sup>, Roushan T MD<sup>4</sup>

1-Associate professor of Pathology, Shahid Sadoughi University of Medical Sciences and Health Services, Yazd, Iran

2-Assistant professor of Radiology, Shahid Sadoughi University of Medical Sciences and Health Services, Yazd, Iran

3-Medical student of Shahid Sadoughi University of Medical Sciences and Health Services, Yazd, Iran

4-Resident of Radiology of Shahid Sadoughi University of Medical Sciences and Health Services, Yazd, Iran

---

Received: 22 January 2012

Accepted: 10 April 2012

## Abstract

### Background

Histologically confirmed meningiomas in first year of life are quite rare. However, review of the sporadic cases in the literature reported meningioma in infants. Those have unique features in common.

### Case presentation

An 11 month-old Iranian male infant presented with a several weeks history of decrease in movement of his right sided upper and lower extremities. Brain MRI revealed a large well-defined extra axial, Dural-based mass lesion, which is contained solid and cystic components. It is originated from falx, and showed intense contrast enhancement. The patient underwent a central craniotomy. The mass was removed sub totally. Microscopic examination of the specimen revealed a meningioma. Radiotherapy was deferred because of the young age. Patient follow up at 4 months later showed that the child was well.

### Conclusion

Pediatric meningiomas show a higher frequency of cyst formation in compared with adult meningiomas. In addition, they show more frequent sarcomatous changes, which is male predominance. Absence of dural based attachment and higher incidence of intraventricular location were seen.

### Key words

Meningioma, Infant, Brain Neoplasms

---

### Corresponding Author

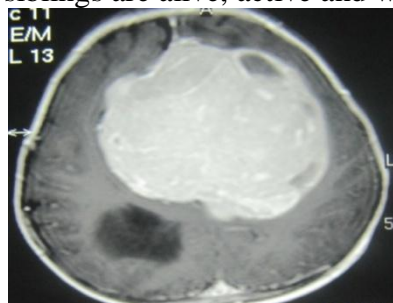
Binesh F MD, Associate professor of pathology, Shahid Sadoughi University of Medical Sciences and Health Services, Yazd, Iran. Email:Binesh44@yahoo.com.

## Introduction

Meningioma refers to a tumor which develops in the membranes surrounding the spinal cord and brain. Meningioma is the most common nonglial primary brain tumor that is most often benign and solid arising from the cranial meninges (1). They account for approximately 20% of all primary CNS tumors in adults. In contrast childhood meningiomas account for less than 3% of all primary CNS tumors (2). They can develop in any of the three layers of meninges. Meningiomas may occur in one, or in multiple sites. Some are slow growing (as most benign meningiomas are), while others grow quickly. The review of several series and case reports confirmed the existence of some characteristic differences of childhood intracranial meningioma, when compared with adulthood meningioma. These features include the slight predominance in male subjects, the high frequency of intraventricular location the frequent cystic forms and the common finding of absence of dural attachment. This report illustrates these differences.

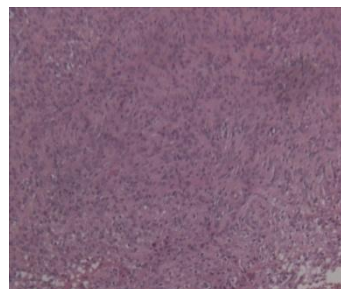
## Case presentation

An 11 month-Old Iranian male infant presented with a several weeks history of decrease in movement of his right sided upper and lower extremities. Previously he was able to perform every day activity with his limbs. He is the fourth child of non-consanguineous parents, the other three siblings are alive, active and well.



*Fig1.MRI revealed a large well-defined extraaxial, dural-based mass lesion, contained solid and cystic components, originate from falx and showed intense contrast enhancement*

The infant was born at term and the antenatal period was uncomplicated. The perinatal period was uneventful and the development was appropriate for age till the onset of the present symptoms. He was exclusively breast-fed. There was no family history of neurofibromatosis. Clinical examination revealed that the infant was afebrile and playful. His weight was 8 kgs, length 70 cm, head circumference 47cm, all at the 50th percentile for age and sex. There was no neurocutaneous stigma. Neurological examination revealed hypotonia in right upper and lower limbs with a motor power of 2/5 grade. The rest of the clinical examination was noncontributory. MRI revealed a large well-defined extra axial, dural-based mass lesion, contained solid and cystic components, originate from falx and showed intense contrast enhancement (fig-1). The patient underwent a central craniotomy. At operation the tumor was superficially connected to the dura. The mass was removed sub totally and sent for histologic examination. The specimen was consisted of a 30 mm nodule of firm cream tissue and separate fragments. Microscopic examination of specimens revealed a Meningioma (fig-2). Postoperative neurologic examination did not show any additional neurological deficit. Radiotherapy was deferred because of the young age. Patient follow up at 4 months later showed that the child was well.



*Fig2.Section shows that the tumoral cells have indistinct cytoplasm boundaries and are arranged in cellular whorls .(H&E x10)*

## Discussion

Meningiomas are the most common benign intracranial tumors, accounting for 15-30% of all primary intracranial tumors. Although overall meningiomas are more common in women, they tend to be more aggressive with a poorer prognosis in men as well in children (3, 4). It is well documented that malignant meningiomas and meningial sarcoma account for 28% of all primary meningial tumors in children (3, 4). Meningiomas constitute 1-4% of all childhood brain tumors (3, 4). Matson et al, reported only one patient among of 313 case of intracranial tumors (5) and only three children with meningioma out of 750 cases of intracranial tumors under 14 years of age. In Cushing and Eisenhardt's study there were only six cases among 313 patients with intracranial meningiomas (6). The average age at presentation was 11.6 year. The presented case was an 11-month old male infant. The incidence of males to females is equal in childhood meningioma. These lesions are frequently associated with neurofibromatosis (23-41%) (7) Our patient did not reveal any stigmata of NF. In children they may arise in unusual sites, where intraventricular location forms about 11-20%. In our case, the tumor was originated from falx. Some are slow growing (most benign meningiomas), while others grow quickly. Generally meningiomas are only symptomatic when they grow large, but depending on their specific location in the brain or spine, some may be more symptomatic than others. The presented case was admitted due to decrease in movement of his right sided upper and lower extremities. Diagnosis of meningioma is based on a report of symptoms, along with CT-scans and MRI. CT-scans can help to determine the extent of the tumor. MRI was initially thought to be poor on T2 WI unless it is nearly totally calcified, so it is the investigation of choice as it can show the

dural origin of the tumor in most cases. In our case, MRI showed a large well-defined extra axial, dural-based mass lesion, contained solid and cystic components, originate from falx and showed intense contrast enhancement. Compared with adult meningiomas, infantile meningioma shows the higher frequency of cyst formation. According to Amano et al. (8), the congenital meningioma has the potential of producing interstitial fluid to form cysts while for Pinna et al (9). Peritumoral cysts may be the final stage of peritumoral vasogenic edema with fluid collection around the tumor. Malignant forms of meningiomas in children are common in radiation induced meningiomas. Also radiation induced meningiomas show a female predominance and a short latency period, which seems directly related to the age at irradiation. The treatment of choice is surgery in children with typical meningiomas and complete removal results a good prognosis. Significant factors contributing to recurrence include the following 1-incomplete surgical resection 2-atypical and malignant histologic types 3-presence of nucleolar prominence 4-presence of more than 2 mitoses per 10 HPFs 5-heterogenous tumor contrast enhancement on CT-scan (10). Radiotherapy was advocated in histologically malignant meningiomas (11). Some studies showed a decrease in the recurrence rates of subtotally excised malignant meningiomas after radiotherapy (12). Our case underwent surgery and radiotherapy was deferred because of the young age. In conclusion compared with adult meningiomas, pediatric meningiomas show the following characteristics: a higher frequency of cyst formation, more frequent sarcomatous changes, male predominance, absence of dural based attachment and higher incidence of intraventricular location (13). Thus, even

though they are rare, pediatric meningiomas often pose a challenge to neurosurgeons.

### Acknowledgment

The authors are indebted to the staff of the radiology and pathology units at Shahid Sadoughi hospital, Yazd-Iran for their helps in preparation of CT-Scan & microscopic slides of this case.

### Conflict of Interest

None declared.

### References

- 1-Osborn AG. In: diagnostic Neuroradiology. St. Louis: Mosby & Year book, inc, 1994: 584-601.
- 2-Rushing EJ, Olsen C, Mena H, Rueda ME, Lee YS, Keating RF, et al. Central nervous system meningiomas in the first two decades of life: a clinicopathological analysis of 87 patients. J Neurosurg. 2005; 103(6):489-95.
- 3-Al-Mefty O (ed): Meningiomas. Surgical Management. Philadelphia: Saunders, 1991; 1(4).
- 4-Schmid H (ed): Meningiomas and Their Surgical Management. Philadelphia: Saunders, 1991.
- 5- Chan RC, Thompson GB. Intracranial meningiomas in childhood. Surg Neurol. 1984; 21(4):319-22.
- 6- Alp H, Ceviker N, Baykaner K, Orbay T. Giant meningioma in a fourteen-month-old infant. Surg Neurol. 1985; 24(1):77-9.
- 7- Turgut M, Ozcan OE, Bertan V. Meningiomas in childhood and adolescence: a report of 13 cases and review of the literature. Br J Neurosurg. 1997; 11(6):501-7.
- 8-Amano K, Miura N, Tajika Y, Matsumori K, Kubo O, Kobayashi N, et al. Cystic meningioma in a 10-month-old infant. J Neurosurg 1980; 52(6): 829-33.
- 9- Pinna G, Beltramello A, Buffatti P, Signorini G, Colombari R, Bricolo A, et al. Cystic meningiomas--an update. Surg Neurol. 1986; 26(5):441-52.
- 10- Castillo G: Meningioma, Brain. e Medicine. Aug 2004.
- 11-Alvarez F, Roda JM, Pérez Romero M, Morales C, Sarmiento MA, Blázquez MG : Malignant and atypical meningiomas: A reappraisal of clinical, histological, and computed tomographic features. Neurosurgery 1987; 20(5):688-94.
- 12-Skuiierud K, Löke AC: The prognosis in meningiomas. Acta Neuropatho 1974; 29(4):377-344.
- 13- Chan RC, Thompson GB: Intracranial meningiomas in childhood. Surg Neurol 1984 ; 21(4): 319-322.