

Genetics of Pediatric Bone Tumors: a Systematic Review

Mohammad Reza Sobhan, MD¹, Shadi Mostafavi, MD^{2*}, Mahta Mazaheri, MD, PhD^{3,4}, Hossein Neamatzadeh, MSc^{3,4}

1.Department of Orthopedic Surgery, Shahid Sadoughi University of Medical Sciences, Yazd, Iran

2.School of Medicine, Shahid Sadoughi University of Medical Sciences, Yazd, Iran

3.Department of Medical Genetics, Shahid Sadoughi University of Medical Sciences, Yazd, Iran

4.Mother and Newborn Health Research Center, Shahid Sadoughi University of Medical Sciences, Yazd, Iran

*Corresponding author: Shadi Mostafavi MD, School of Medicine, Shahid Sadoughi University of Medical Sciences, Yazd, Iran. E-mail: drmostafavi@yahoo.com

Received: 21 June 2016

Accepted: 20 August 2016

Abstract

Background: Understanding the differences in genetics of malignancies is crucial for therapeutic decisions. This systematic review was conducted to evaluate the current evidence on genetics of bone tumors in the context of pediatric cancer.

Material and Methods: We performed a systematic review of the literature published on genetics of pediatric bone tumors, using PubMed, Google scholar, Science Citation Index and Embase. The search profiles used were: pediatric/childhood malignant bone tumors, pediatric/ childhood bone cancer/neoplasm, osteosarcoma/bone sarcoma/Ewing's sarcoma and risk factors/etiology. Inclusion criteria were as follows: focused upon biology and genetics mechanism of primary bone tumors and published in the last 15 years in English.

Results: A total of 278 articles were searched for relevancy, determined by article title, abstract, and full copy. After screening the titles and abstracts, 239 articles were excluded because they were the same articles and case reports. Finally, 39 articles were found that fulfilled all inclusion criteria.

Conclusion: This systematic review shows that many genetic studies have been performed on the genetics basis of pediatric bone tumors. The knowledge base formed by this review should facilitate more informative future research. It is important that orthopedics and other specialists be aware about genetics basis of pediatric bone tumors.

Keywords: Bone Tumor, Pediatric Tumors, Ewing sarcoma, Osteosarcoma, Rhabdomyosarcoma

Introduction

Cancer is, next to accidents, the second most common cause of childhood death in developed countries (1,2). Childhood cancers are a diverse group of tumors that differ from the cancers that arise in adulthood. Childhood cancers are broadly defined as cancers developing in individuals less than 20 years of life. Childhood cancers can be more finely grouped into infant cancer which occurs at less than 1 year of age and adolescent cancer between the ages of 15-19 (3). The total incidence of childhood cancer varies little throughout the world. In Europe, approximately 1 in 5-600 children develop a malignant disease before the age of fifteen (4). Childhood cancers (<15 years)

are broadly classified on the basis of their anatomic location rather than common molecular, cellular or genetic features. Compared to other malignancies, primary malignant bone tumors are fairly rare in childhood (5). Primary bone tumors are the sixth most common neoplasm occurring in children and constitute approximately 6% of all childhood malignancies. According to the Surveillance, Epidemiology, and End Results program of the National Cancer Institute, the average annual incidence of bone malignancies in the United States is 8.7 per million children younger than 20 years (6).

The two most common types of malignant bone tumors are osteosarcoma and Ewing's sarcoma, accounting for 56% and

34% of bone tumors in children, respectively (7). Of these, 57% of tumors are found in the long bones of the lower extremities. There is a significant difference in location incidence between osteosarcoma and Ewing's sarcoma. Ewing's sarcoma is more prevalent in the central body axis (45%), while only affecting the lower extremities 29% of the time. However, 78% of osteosarcomas are found in the lower extremities (8).

The purpose of this review is merely to help to organize the understanding about genetics of pediatric bone tumors.

Materials and Methods

Search Strategy

A comprehensive literature search was performed using PubMed, Medline, Web of Knowledge, and Google Scholar to identify eligible studies that were published before April 2016. Articles were sought with the following key words: "pediatric" or "childhood malignant bone tumors", "pediatric" or "childhood bone cancer" or "neoplasm", "osteosarcoma" or "bone sarcoma", "Ewing's sarcoma", "Osteosarcoma", "Ewing's sarcoma", "Alveolar Rhabdomyosarcoma", "Dermatofibrosarcoma Protuberans", "Synovial sarcoma", and "Congenital fibrosarcoma". In addition, studies were identified by a manual search of the reference lists of reviews and retrieved studies. We included all the biology and genetics mechanism of primary bone tumors. All eligible studies were retrieved and their bibliographies were checked for other relevant publications. When the same sample was used in several publications, only the most complete study was included following careful examination. Inclusion criteria: All studies were included if they met the following criteria: focused upon biology and genetics mechanism of primary bone tumors and published in the last 15 years in English. Major reasons for exclusion of studies were as follows: (1) not for genetics research and (2) duplicate of previous publication.

Results

Figure 1 graphically illustrates the trial flow chart. A total of 278 articles regarding childhood cancer were identified. After screening the titles and abstracts, 197 articles were excluded because they were the same articles, review articles, and case reports. Finally, 81 articles had addressed the genetics. Many other research efforts in this regard had been made through theses and reported in non-ISI and non-PubMed English journals; thus, further search by Google gave us 4 more relevant articles.

Osteosarcoma

Osteosarcoma is the most common malignant tumor of the bone, accounting for 5% of childhood tumors in the United States with approximately 900 new cases diagnosed each year (11). Osteosarcoma is the most frequent bone cancer in children under the age of 20. The median age of onset for patients with osteosarcoma is 14 years, with approximately 70%-75% of OSA cases occurring between the ages of 10 and 25 years (12). There is a small predisposition of this disease for males, with a 1.5:1 male to female ratio (13).

Osteosarcoma is characterized by tumor cell production of defective osteoid, or immature bone, which forms the basis for differentiating OS from other tumors of the bone. The most common location is the distal femur, which is affected in 45% of cases, followed by 15% in the proximal tibia and 10% in the proximal humerus (14, 15).

The etiology of osteosarcoma is essentially unknown (14). Also, the pathogenesis of osteosarcoma and the role of the osteosarcoma in bone microenvironment are not fully understood. However, certain genes have been implicated in the pathogenesis of osteosarcoma. Tumour suppressor gene mutations of p53, RB and mdm2 gene are frequently identified in OSA.

Studies on osteosarcoma, conducted in human discovered gene alterations

including: TP53, IGF-1/IGF 1RF, HGF/MET, ERBB-2/HER-2, Phosphatase and tensin homolog (PTEN), RB, CDKN2A, SIS/PDGF, matrix metalloproteinases (MMPs), Ezrin (EZR), COX-2, VEGF, and TERT (11).

Most OS tumors present with complex chromosomal abnormalities and considerable heterogeneity and as a consequence understanding the somatic drivers of OS has been difficult. In addition, the rarity of OS has made the identification of risk factors particularly challenging (11, 17). The hereditary cancer syndromes associated with OS included Retinoblastoma, Li Fraumeni, Rothmund-Thompson, Werner, and Bloom due to mutations in the DNA repair and metabolism genes RB1, TP53, RECQL4, WRN, and BLM genes, respectively (17-20). Additionally mutations in this set of genes are frequently mutated in sporadic OS tumors (18). Given the clear role of DNA repair and metabolism genes in both hereditary OS risk and sporadic OS mutagenesis as well as preliminary data from genetic epidemiological studies, we hypothesized that common polymorphic variants, SNPs with mild effects in TP53, RB1, RECQL4, WRN, BLM and their molecular pathways lead to increased risk of developing sporadic OS. Rothmund-Thompson patients develop striking skeletal abnormalities, short stature, and abnormal nails and teeth (19). Precise estimates of the risk of OS in Werner and Bloom syndrome do not exist due to the rare nature of the diseases, but multiple case reports of OS occurring in patients with these syndromes supports an association (19, 20).

Ewing's sarcoma

Bone sarcomas are divided into different tumors, with a peak incidence in late childhood/adolescence for both OS and Ewing's sarcoma, as opposed to chondrosarcoma, which is essentially a tumour of adulthood (21, 22). Ewing's sarcoma (ES) is a rare malignancy with a

strong pediatric predilection, typically presenting as a bone tumor. It was first described by James Ewing in 1921 as a "diffuse endothelioma of bone", believing that it arose from the blood vessels of the bone tissue (22).

The causes of ES are unknown. Bone sarcomas in general are most often seen associated with rapid growth in younger persons. It might be an explanation that rapid proliferating cells are more exposed for neoplastic transformation, which can trigger the disease (23). Ewing sarcoma of bone represents the second most common primary malignant tumor of bone in children and adolescents. Overall rates of tumors of bones are approximately 40 new cases per year in Norway, and of these Ewing's sarcoma accounts for approximately 5-10. The median ages at diagnosis was between 14 and 15 years, with 95% of cases reported between the ages of 4 and 25 years (24). In an analysis of the European Intergroup Cooperative Ewing's Sarcoma study (EICESS) study group database, 20% of patients were over 20 years. And with advances in the molecular diagnosis of otherwise undifferentiated sarcomas, the reported incidence in young adults is increasing (25). ES shows a slight male predilection (male-to-female ratio, 1.5:1) (25, 26). There is a difference in the racial incidence of this tumor. Data from the Surveillance Epidemiology and End 5 Results (SEER) database, reporting an ES incidence 9-fold in Caucasians compared to African Americans, support the existence of an underlying genetic predisposition (27).

In the early 1980s, Ewing's sarcoma and the peripheral Primitive neuroectodermal tumor (PNET) were both found to contain the same reciprocal translocation between chromosomes 11 and 22, t(11;22) (28,29). They have been grouped into a class of cancers entitled Ewing's Sarcoma Family of Tumor (ESFT), which include additional Extrasosseus Ewing's sarcoma, neuroepithelioma, atypical Ewing's sarcoma, and Askins tumor (tumor of the

chest wall). In recent years, molecular techniques have been commonly used to diagnose ES because it often exhibits specific chromosomal translocations. Reverse transcription polymerase chain reaction (RT-PCR) and fluorescent in situ hybridization (FISH) are very useful methods for detecting fusion genes (31). Microscopically, ES demonstrates glycogen-rich, small round-like “blue” cells with little cytoplasm. Formation of pseudorosettes may also be seen, indicating neuroectodermal differentiation. Mitotic activities are low (28,31). Immunohistochemistry shows positive vimentin (biomarker), O13, CD99 (sensitive, not specific) and FLI-1, and is negative for a panel of antibodies.^{13, 17} Diagnostic genetic studies show translocations, most frequently t(11;22) (q24; q12) with EWSR1-FLI1 gene fusion. FISH or reverse transcriptase–polymerase chain reaction (RT-PCR) has greatly facilitated diagnosis and delineation of ES (31). A study on integrated multimodal genetic testing reported that use of all methods capable of detecting EWSR1 rearrangements has value in the workup of suspected cases of ES. Findings in integrated clinicopathologic, cytogenetic, FISH and RT-PCR analyses of 32 pediatric patients with ES: - Cytogenetics detected t(11;22) (n = 14) and t(21;22) (n = 1) in 15 (46.9%) patients. FISH detected EWSR1 rearrangements in 27 (96.4%) of 28 patients tested. RT-PCR was positive in 27 (84.4%) of 32 patients, including 24 EWSR1-FLI1 and 3 EWSR1-ERG. RT-PCR defined breakpoints and fusion partners in 7 cases with EWSR1 rearrangements detected by FISH. Additionally, the Sanger sequencing further delineated breakpoints in 21 (77.8%) of 27 RT-PCR positive cases (32). Conventional cytogenetic analysis provided a global view but had a lower detection rate and longer turnaround time than other methods. FISH is a rapid method and theoretically can detect all EWSR1 rearrangements, but it cannot

identify all partners and is not completely specific for ES (33). RT-PCR and sequencing are more sensitive and useful in identifying fusion partners and refining breakpoints; however, these methods can be compromised by poor RNA preservation and primer design.²⁴ The ES-defining chromosomal translocation fuse the 5' end of the EWSR1 Ewing sarcoma breakpoint region 1 gene on chromosome 22 to the 3' portion of a gene of the ETS transcription factor family (33,34), including FLI1 (90%) and ERG (>5%) and in and in ETV4, or FEV. The function of the Ewing sarcoma gene (EWSR1) is not well understood. The gene FLI1 from chromosome 11 is involved in turning other genes on and off. This new fused gene, called EWS-FLI1 or EWSR1-FLI1 (Ewing sarcoma breakpoint region 1-Friend leukaemia virus integration 1, (translocation (11;22)(q24;q12)), encodes an altered fusion protein that regulates other genes that can give rise to cancers when inappropriately expressed (35,36).

ES represents morphologically heterogeneous tumors but they all have one common feature which is nonrandom chromosomal translocation involving the EWS gene and one of the members of the ETS family of transcription factors (37). Approximately 85% of ES tumors have the t(11;22)(q24;q12) chromosomal abnormality (38). The pathognomonic genetic aberration in ESFT fuses the EWS gene (also known as EWSR1, Ewing sarcoma breakpoint region 1) to one of five ETS transcription factors: FLI1, ERG, ETV1, ETV4, or FEV. FLI1 (Friend leukemia virus integration 1) is the fusion partner in approximately 85% of cases and ERG in about 10%, while ETV1, ETV4, and FEV each account for less than 1% (39). In very rare cases, FUS combines with ERG or FEV and EWS is juxtaposed to non-ETS genes (30). This translocation leads to in frame fusion of the EWSR1 (also known as EWS) gene on chromosome 22 to the FLI1 gene on chromosome 11 and encodes the

EWS/FLI1 fusion protein. EWS/FLI1 contains the amino-terminus of EWS fused, in frame, to the carboxyl-terminus of FLI1 transcription factor (46). In ES cases lacking EWS/FLI1, there are alternative translocations present that fuse EWS to other ETS family transcription factors, like ERG (5% cases), ETV1, ETV4, FEV and others (41,42), which all most likely mimic EWS/FLI1 (52-55). Moreover, the presence of the fusion enabled easy differential diagnosis by performing PCR and thus distinguishing ES from other histo/morphologically similar tumors such as neuroblastomas, rhabdomyosarcomas and giant cell tumors (43).

Alveolar Rhabdomyosarcoma

Rhabdomyosarcoma (RMS) is a pediatric cancer of mesenchymal origin and is the most common soft tissue sarcoma in children. RMS is the most common pediatric soft tissue sarcoma, accounting for 5–7% of all malignancies in children and adolescents less than 20 years of age (44,45). These tumors are generally divided into two major subgroups: embryonal (ERMS), representing the more favorable prognosis with an overall survival rate of 82%, and alveolar (ARMS), with a reduced overall survival rate of 65%. This poorer responsiveness of ARMS is evident even for treatment regimens that combine radiation therapy, combination chemotherapies and surgery (44). In addition to histologic differences, ARMS is distinguished from ERMS by the presence of specific chromosomal translocations present in the majority of ARMS tumors (45). ARMS accounts for 20-30% of all RMS tumors. Therefore ARMS represents 1% of all malignancies among children and adolescents, and has an annual incidence of 1 per million. Many ARMS tumors occur in older children and young adults - this age association characterizes the more prevalent PAX3-FKHR-positive subset of ARMS (46). In contrast, PAX7-FKHR-positive ARMS as well as fusion-negative tumors tend to

occur in younger children. The overall 5-year survival rate is 60%, although it is only 30% for those with metastatic disease (47). Current therapy for RMS is similar to that for ES, employing a combination of adjuvant intensive chemotherapy with surgery and/or radiation to the primary and metastatic sites of disease.

Alveolar RMS has recurrent reciprocal translocations that are absent in embryonal tumours. These translocations, t(2;13)(q35;q14) and t(1;13)(p36;q14), generate the fusion genes PAX3-FOXO1 and PAX7-FOXO1, respectively. The PAX3-FOXO1 fusion protein, created by the t(2;13) chromosomal translocation, is present in most cases of alveolar rhabdomyosarcoma (48). The translocation severs the transcriptional transactivation domain of PAX3 but preserves both of its two DNA binding domains. The FOXO1 gene is disrupted in a large intron that bisects its DNA binding domain. The chromosomal rearrangement creates a chimeric protein containing the transcriptional activation domain of FOXO1 and the DNA binding elements of PAX3, under the control of the PAX3 promoter (49,50). It is notable that this translocation event also destroys one allele of both the PAX3 and the FOXO1 genes (51).

Dermatofibrosarcoma Protuberans

Dermatofibrosarcoma protuberans is associated with a rearrangement (translocation) of genetic material between chromosomes 17 and 22 (52). This translocation, written as t(17;22), fuses part of the COL1A1 gene from chromosome 17 with part of the PDGFB gene from chromosome 22. The translocation is found on one or more extra chromosomes that can be either the normal linear shape or circular. When circular, the extra chromosomes are known as supernumerary ring chromosomes (53). Ring chromosomes occur when a chromosome breaks in two places and the ends of the chromosome arms fuse

together to form a circular structure. Other genes from chromosomes 17 and 22 can be found on the extra chromosomes, but the role these genes play in development of the condition is unclear (52-54). The translocation is acquired during a person's lifetime and the chromosomes containing the translocation are present only in the tumor cells. This type of genetic change is called a somatic mutation.

In normal cells, the COL1A1 gene provides instructions for making part of a large molecule called type I collagen, which strengthens and supports many tissues in the body. The PDGFB gene provides instructions for making one version (isoform) of the platelet derived growth factor (PDGF) protein (55,56). By attaching to its receptor, the active PDGFB protein stimulates many cellular processes, including cell growth and division (proliferation) and maturation (differentiation).

The COL1A1-PDGFB fusion gene is found in more than 90 percent of dermatofibrosarcoma protuberans cases. In the remaining cases, changes in other genes may be associated with this condition (57). These genes have not been identified. The abnormally fused COL1A1-PDGFB gene provides instructions for making an abnormal combined (fusion) protein that researchers believe ultimately functions like the PDGFB protein (58). The gene fusion leads to the production of an excessive amount of protein that functions like the PDGFB protein. In excess, this fusion protein stimulates cells to proliferate and differentiate abnormally, leading to the tumor formation seen in dermatofibrosarcoma protuberans (57).

Synovial sarcoma

Synovial sarcoma, an aggressive soft tissue tumor with high rate of local recurrence and distant metastasis is currently hypothesized to originate from mesenchymal stem cells (59). It occurs most commonly in young patients,

representing about 10% of soft tissue sarcomas in all age groups and about 15-20% in adolescents and most frequently presents as a painless deep-seated tumor in the extremity of a young adult patient (60,61). Histologically, synovial sarcoma is characterized by biphasic or monophasic spindle cell histology, defined respectively by the presence or absence of (glandular) epithelial differentiated areas (62). Despite improved management of local disease, still more than half of synovial sarcoma patients die of chemotherapy-resistant metastatic disease. The prevalent metastatic pattern is hematogenous and in some cases lymphatic (61,62).

Synovial sarcoma is also a well-known "translocation-associated tumor" with characteristic balanced translocation between SSX located on chromosomes X and SYT on chromosome 18, t(X;18) (p11.2;q11.2), represented in more than 95% of the cases (63,64). At least 95% of all SSs bear a unique chromosomal translocation, which results in a fusion of the SYT gene on chromosome 18 with either the SSX1 gene or the SSX2 gene or, more rarely, the SSX4 gene on the X chromosome (63). Because these gene fusions are highly specific for SS, their detection with molecular genetics allows the pathologist to render a correct diagnosis (64).

SYT and SSX are thought to bind to other chromatin remodeling complexes or transcription factors to be transported in to nuclei where they exert their functions (65,66). The fusion of the SS18 (previously known as SYT) gene on 18q11.2 to either one of three highly homologous SSX genes (SSX1, SSX2 or SSX4) on Xp11.2 is a hallmark of SS (67). The majority carry the SS18-SSX1 and SS18-SSX2 fusions with the former variant being nearly twice as common as the latter. The lower frequency of the SS18-SSX4 fusion type and absence of fusions involving the other SSX genes may be due to these genes being located in genomic regions less prone to

rearrangement (depending on chromatin structure and repeat content) and/or due to lower transforming ability of the resultant fusion products (68). The higher frequency of SSX1 fusions compared to SSX2 may be attributed to a slightly higher oncogenic advantage leading to in vivo selection or due to differences in chromatin structure around SSX1 and SSX2 (69).

Congenital Fibrosarcoma

Unlike synovial sarcoma, which is extremely rare in young children, fibrosarcoma may be seen in both infants and older children. A unique form of congenital fibrosarcoma is well described in newborn infants and is considered to be a histologically low-grade tumor (70,71).

Congenital (infantile) fibrosarcomas (CFSs) is a pediatric spindle cell tumor of the soft tissues that usually presents before the age of 2 years. CFSs are uncommon soft tissue tumors, principally arising in the extremities, which are also diagnosed generally in the first year of life (70,72). CFSs have broad histological overlap with CMNs, and their clinical course is relatively benign, especially in comparison with the aggressive clinical behavior of histologically similar fibrosarcomas in adult patients (72).

The fibrosarcoma subcategory (ICCC IXb) includes the following diagnoses (incidence rates for the younger than 20 year old population are provided in parentheses): dermatofibrosarcoma (1.0 per million), malignant fibrous histiocytoma (0.8 per million), fibrosarcoma (0.6 per million), malignant peripheral nerve sheath tumor (0.6 per million), and infantile fibrosarcoma (0.2 per million) (73,74). Each of these soft tissue sarcomas, save infantile fibrosarcoma, occurs in adults as well as in children (73). With the exception of infantile fibrosarcoma, each of these diagnoses occurred at higher incidence among the 15-19 year old population than among any of the younger age groups (74). Infantile fibrosarcomas, which are known

for their excellent outcome with surgery alone (73), occurred only in the younger than 5- year age group (74).

These tumors are associated with trisomies of chromosome 8,11,17, and 20. In infants with huge, unrespectable tumors, there have been some reports that preoperative chemotherapy may permit eventual nonmutilating surgical resection. Fibrosarcomas in older children, in contrast, must be treated with a more aggressive surgical approach. Fibrosarcomas are also common as secondary, radiation-induced neoplasms (75).

The main karyotypic aberration associated with CFS is the t(12;15)(p13;q25) rearrangement that fuses the transcription factor ETV6 (ets variant 6, also known as TEL) to the receptor tyrosine kinase NTRK3 (neurotrophic tyrosine kinase receptor type 3, also known as TRKC) (76). Though first identified in CFS, the ETV6-NTRK3 fusion is not unique to this malignancy. Expression has also been observed in congenital mesoblastic nephroma (78), secretory breast carcinoma, and acute myelogenous leukemia (79). The fusion links the sterile alpha motif (also known as pointed or helix-loop-helix) oligomerization domain of ETV6 to the kinase domain of NTRK3. This allows the protein to self-associate independent of ligand binding, resulting in an auto-phosphorylated, constitutively active kinase (78).

ETV6-NTRK3 is able to transform NIH-3T3 cells, which requires both the ETV6 oligomerization domain and NTRK3 kinase domain (78). ETV6-NTRK3 mediated cellular transformation is also dependent on IGF1R signaling as the absence of IGF1R or inhibition of the downstream PI3K and MAPK pathways prevented anchorage-independent growth in soft agar (77,78). Analogous experiments have been performed in breast epithelial cells, yielding similar results. Blocking the IGF1R pathway also inhibits ETV6-NTRK3 transformation of breast

epithelial cells and treatment of transformed cells with a dual specificity IGF1R/IR (insulin receptor) inhibitor results in decreased tumor growth in vivo (80). Additionally, expressing the fusion in the Eph4 mammary epithelial line resulted in tumors that retained epithelial markers (81). This contrasts to transformations of NIH-3T3 and Scg6 mammary myoepithelial cells those display mesenchymal features, which show little or no evidence of differentiation (80,81). These results suggest the ETV6-NTRK3 fusion does not drive differentiation, but activates lineage-independent oncogenic pathways (76,79).

Conclusion

This systematic review shows that many genetic studies have been performed on the genetics basis of pediatric bone tumors. It is important that orthopedics and other specialists be aware about genetics basis of pediatric bone tumors. The knowledge base formed by this review should facilitate more informative future research. Additional studies of the biologic mechanisms underlying genetic basis pediatric bone tumors are necessary to allow more definitive and reliable conclusions.

Conflict of interest

All authors declare that they have no conflict of interest.

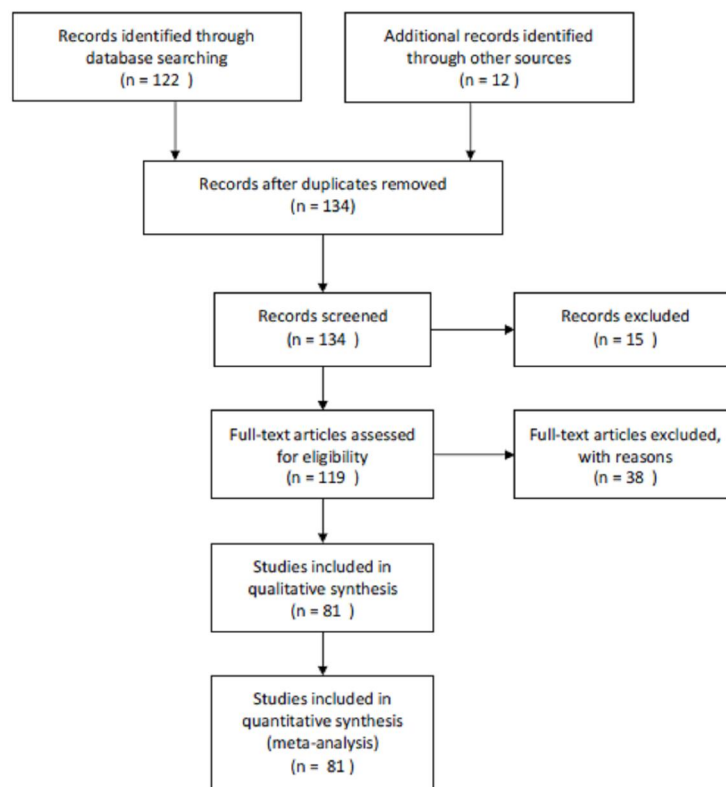


Figure1. Flow chart displaying literature search and study selection.

References

1. Goyal S, Roscoe J, Ryder WD, Gattamaneni HR, Eden TO. Symptom interval in young people with bone cancer. *Eur J Cancer* 2004;40(15):2280-6.
2. Jones PG. Malignant disease in childhood: the problems in general practice. *Aust Fam Physician* 1977;6(3):234-237.
3. Basta NO, James PW, Gomez-Pozo B, Craft AW, McNally RJ. Survival from childhood cancer in northern England, 1968-2005. *Br J Cancer* 2011;105(9):1402-8.
4. Schmiegelow K. Cancer in childhood and inheritance. *Ugeskr Laeger* 2006;168:2373-2376.
5. Bruijnzeels MA, Foets M, van der Wouden JC, van den Heuvel WJ, Prins A. Everyday symptoms in childhood: occurrence and general practitioner consultation rates. *Br J Gen Pract* 1998;48:880-4.
6. Hay AD, Heron J, Ness A. The prevalence of symptoms and consultations in pre-school children in the Avon Longitudinal Study of Parents and Children (ALSPAC): a prospective cohort study. *FAM Pract* 2005; 22:367-74.
7. Caudill JS, Arndt CA. Diagnosis and management of bone malignancy in adolescence. *Adolesc Med State Art Rev* 2007;18(1):62-78.
8. Ries LAG, Smith MA, Gurney JG, Linet M, Tamra T, Young JL, Bunin GR (Eds). *Cancer Incidence and Survival among Children and Adolescents: United States SEER Program 1975-1995*, National Cancer Institute, SEER Program. NIH Pub. No. 99-4649. Bethesda, MD, 1999.
9. Ertmann RK, Siersma V, Reventlow S, Soderstrom M. Infants' symptoms of illness assessed by parents: impact and implications. *Scand J Prim Health Care* 2011; 29:67-74.
10. Kaatsch P. Epidemiology of childhood cancer. *Cancer Treat Rev* 2010; 36:277-85.
11. Mueller F, Fuchs B. Comparative Biology of Human and Canine Osteosarcoma. *Journal of Veterinary Internal Medicine* 2007;164, 155-164.
12. Bielack SS, Kempf-Bielack B, Delling G, Exner GU, Flege S, Helmke K, et al. Prognostic factors in high-grade osteosarcoma of the extremities or trunk: an analysis of 1,702 patients treated on neoadjuvant cooperative osteosarcoma study group protocols. *J Clin Oncol* 2002;20(3):776-90.
13. Canadian Cancer Society's Steering Committee: *Canadian Cancer Statistics 2009*. Toronto: Canadian Cancer Society, 2009.
14. Withrow SJ, Powers BE, Straw RC, Wilkins RM. Comparative aspects of osteosarcoma. Dog versus man. *Clin Orthop Relat Res* 1991;(270):159-68.
15. Kager L, Zoubek A, Pötschger U, Kastner U, Flege S, Kempf-Bielack B, et al. Primary metastatic osteosarcoma: presentation and outcome of patients treated on neoadjuvant Cooperative Osteosarcoma Study Group protocols. *J Clin Oncol* 2003;21(10):2011-8.
16. Link MP, Goorin AM, Miser AW, Green AA, Pratt CB, Belasco JB, et al. The effect of adjuvant chemotherapy on relapse-free survival in patients with osteosarcoma of the extremity. *N Engl J Med* 1986 314(25):1600-6.
17. Gokgoz N, Wunder JS, Mousses S, Eskandarian S, Bell RS, Andrulis IL. Comparison of p53 mutations in patients with localized osteosarcoma and metastatic osteosarcoma. *Cancer* 2001;92(8):2181-9.
18. Wang LL, Gannavarapu A, Kozinetz CA, et al. Association between osteosarcoma and deleterious mutations in the RECQL4 gene in rothmund-thomson syndrome. *J Natl Cancer Inst* 2003; 95(9):669-74.

19. Draper GJ, Sanders BM, Kingston JE. Second primary neoplasms in patients with retinoblastoma. *Br J Cancer* 1986; 53(5):661-71.
20. Goto M, Miller RW, Ishikawa Y, Sugano H. Excess of rare cancers in werner syndrome (adult progeria). *Cancer Epidemiol Biomarkers Prev* 1996;5(4):239-46.
21. Weiss SW, Goldblum JR, eds. *Enzinger and Weiss's Soft tissue tumors*. 5th ed., Mosby Elsevier: Philadelphia.
22. Huvo AG. *Bone tumors: diagnosis, treatment and prognosis*. 2. Philadelphia, PA: W.B. Saunders Company; 1991.
23. Balarajan R, Acheson ED. Soft tissue sarcomas in agriculture and forestry workers. *J Epidemiol Community Health* 1984;38(2):113-116.
24. Mitelman F, Johansson B, Mertens F. The impact of translocations and gene fusions on cancer causation. *Nat Rev Cancer* 2007;7(4):233-45.
25. Helman LJ, Meltzer P. Mechanisms of sarcoma development. *Nat Rev Cancer* 2003;3(9):685-94.
26. Ladanyi M, Antonescu CR, Leung DH, Woodruff JM, Kawai A, Healey JH, et al. Impact of SYT-SSX fusion type on the clinical behavior of synovial sarcoma: a multi-institutional retrospective study of 243 patients. *Cancer Res* 2002;62(1):135-40.
27. Ladanyi M, Antonescu CR, Dal Cin P, eds. *Cytogenetics and molecular genetic pathology of soft tissue tumours*. 5th ed. Enzinger and Weiss's *Soft tissue tumors* ed. G.J. Weiss SW. 2008, Mosby Elsevier: Philadelphia.
28. Wunder JS, Czitrom AA, Kandel R, Andrulis IL. Analysis of alterations in the retinoblastoma gene and tumor grade in bone and soft-tissue sarcomas. *J Natl Cancer Inst* 1991;83(3):194-200.
29. Yoo J, Lee HK, Kang CS, Park WS, Lee JY, Shim SI. p53 gene mutations and p53 protein expression in human soft tissue sarcomas. *Arch Pathol Lab Med* 1997;121(4):395-9.
30. Mitelman F, Johansson B, Mertens F. *Mitelman Database of Chromosome Aberrations in Cancer*. URL: <http://cgap.nci.nih.gov/Chromosomes/Mitelman>. 2009.
31. Coindre JM, Terrier P, Guillou L, Le Doussal V, Collin F, Ranchère D, et al. Predictive value of grade for metastasis development in the main histologic types of adult soft tissue sarcomas: a study of 1240 patients from the French Federation of Cancer Centers Sarcoma Group. *Cancer* 2001;91(10):1914-26.
32. Warren M, Weindel M, Ringrose J, Venable C, Reyes A, Terashima K, et al. Integrated multimodal genetic testing of Ewing sarcoma-a single-institution experience. *Hum Pathol* 2013;44(10):2010-9.
33. Potratz J, Jürgens H, Craft A, Dirksen U. Ewing sarcoma: biology-based therapeutic perspectives. *Pediatr Hematol Oncol* 2012;29(1):12-27.
34. Letourneau PA, Shackett B, Xiao L, Trent J, Tsao KJ, Lally K, et al. Resection of pulmonary metastases in pediatric patients with Ewing sarcoma improves survival. *J Pediatr Surg* 2011 Feb;46(2):332-5.
35. Potratz J, Dirksen U, Jürgens H, Craft A. Ewing sarcoma: clinical state-of-the-art. *Pediatr Hematol Oncol* 2012;29(1):1-11.
36. Huvo A. *Bone Tumors, diagnosis, treatment and prognosis*, Saunders 1990;2:523-42.
37. Potikyan G, Savene RO, Gaulden JM, France KA, Zhou Z, Kleinerman ES, et al. EWS/FLI1 regulates tumor angiogenesis in Ewing's sarcoma via suppression of thrombospondins. *Cancer Res* 2007;67:6675-84.
38. Riggi N, Suvà ML, Suvà D, Cironi L, Provero P, Tercier S, et al. EWS-FLI-1 expression triggers a Ewing's sarcoma initiation program in primary human mesenchymal stem cells. *Cancer Res* 2008;68:2176-85.

39. Herrero-Martín D, Osuna D, Ordóñez JL, Sevillano V, Martins AS, Mackintosh C, et al. Stable interference of EWS-FLI1 in a Ewing sarcoma cell line impairs IGF-1/ IGF-1R signalling and reveals TOPK as a new target. *Br J Cancer* 2009; 101:80-90.
40. Fuchs B, Inwards C, Scully SP, Janknecht R. hTERT is highly expressed in Ewing's sarcoma and activated by EWS-ETS oncoproteins. *Clin Orthop Relat Res* 2004; 64-8.
41. Zanini C, Giribaldi G, Mandili G, Carta F, Crescenzo N, Bisaro B, et al. Inhibition of heat shock proteins (HSP) expression by quercetin and differential doxorubicin sensitization in neuroblastoma and Ewing's sarcoma cell lines. *J Neurochem* 2007;103:1344-54.
42. Martins AS, Ordoñez JL, García-Sánchez A, Herrero D, Sevillano V, Osuna D, et al. A pivotal role for heat shock protein 90 in Ewing sarcoma resistance to anti-insulinlike growth factor I receptor treatment: in vitro and in vivo study. *Cancer Res* 2008; 68:6260-70.
43. Martins AS, Mackintosh C, Martin DH, Campos M, Hernandez T, Ordoñez JL, et al. Insulin-like growth factor I receptor pathway inhibition by ADW742, alone or in combination with imatinib, doxorubicin or vincristine, is a novel therapeutic approach in Ewing tumor. *Clin Cancer Res* 2006; 12:3532-40.
44. Young JL, Ries LG, Silverberg E et al. Cancer incidence, survival, and mortality for children younger than age 15 years. *Cancer* 1986;58:598-602.
45. Kramer S, Meadows AT, Jarrett P et al. Incidence of childhood cancer: experience of a decade in a population-based registry. *J Natl Cancer Inst* 1983; 70:49-55.
46. <http://atlasgeneticsoncology.org/Tumor/s/AlvRhabdomyosarcID5194.html>
47. Sun X, Guo W, Shen J, Mankin H, Hornicek F, Duan Z. Rhabdomyosarcoma: Advances in Molecular and Cellular Biology. *Sarcoma*. 2015; 2015:1-14.
48. Folpe AL, Goldblum JR, Rubin BP, Shehata BM, Liu W, Dei Tos AP, Weiss SW. Morphologic and immunophenotypic diversity in Ewing family tumors: a study of 66 genetically confirmed cases. *Am J Surg Pathol* 2005;29(8):1025-33.
49. Sumegi J, Streblow R, Frayer RW. Recurrent t(2;2) and t(2;8) translocations in rhabdomyosarcoma without the canonical PAX-FOXO1 fuse PAX3 to members of the nuclear receptor transcriptional coactivator family. *Genes Chromosomes Cancer* 2010; 49(3):224-236.
50. Marshall AD, Grosveld GC. Alveolar rhabdomyosarcoma - The molecular drivers of PAX3/7-FOXO1-induced tumorigenesis. *Skelet Muscle* 2012;2(1):25.
51. Missiaglia E, Williamson D, Chisholm J, Wirapati P, Pierron G, Petel F, et al. PAX3/FOXO1 fusion gene status is the key prognostic molecular marker in rhabdomyosarcoma and significantly improves current risk stratification. *J Clin Oncol* 2012;30(14):1670-7.
52. McArthur GA, Demetri GD, van Oosterom A, Heinrich MC, Debiec-Rychter M, Corless CL, et al. Molecular and clinical analysis of locally advanced dermatofibrosarcoma protuberans treated with imatinib: Imatinib Target Exploration Consortium Study B2225. *J Clin Oncol* 2005;23(4):866-73.
53. Lemm D, Mugge LO, Mentzel T, Hoffken K. Current treatment options in dermatofibrosarcoma protuberans. *J Cancer Res Clin Oncol* 2009;135(5):653-65.
54. Dimitropoulos VA. Dermatofibrosarcoma protuberans. *Dermatol Ther* 2008;21(6):428-32.

55. Gisselsson D, Hoglund M, O'Brien KP, Dumanski JP, Mertens F, Mandahl N. A case of dermatofibrosarcoma protuberans with a ring chromosome 5 and a rearranged chromosome 22 containing amplified COL1A1 and PDGFB sequences. *Cancer Lett* 1998;133(2):129-34.
56. Kikuchi K, Soma Y, Fujimoto M, Kadono T, Sato S, Abe M, et al. Dermatofibrosarcoma protuberans: increased growth response to platelet-derived growth factor BB in cell culture. *Biochem Biophys Res Commun* 1993;196(1):409-415.
57. McArthur G. Molecularly targeted treatment for dermatofibrosarcoma protuberans. *Semin Oncol* 2004;31:30-6.
58. Eilber FC, Dry SM. Diagnosis and management of synovial sarcoma. *J Surg Oncol* 2008;97(4):314-20.
59. Spira AI, Ettinger DS. The use of chemotherapy in soft-tissue sarcomas. *Oncologist* 2002;7(4):348-59.
60. Siehl JM, Thiel E, Schmittl A, Hütter G, Deckert PM, Szelényi H, et al. Ifosfamide/liposomal daunorubicin is a well-tolerated and active first-line chemotherapy regimen in advanced soft tissue sarcoma: results of a phase II study. *Cancer* 2005;104(3):611-7.
61. Zagars GK, Ballo MT, Pisters PW, Pollock RE, Patel SR, Benjamin RS, et al. Prognostic factors for patients with localized soft-tissue sarcoma treated with conservation surgery and radiation therapy: an analysis of 1225 patients. *Cancer* 2003;97(10):2530-43.
62. Antonescu CR, Kawai A, Leung DH, Lonardo F, Woodruff JM, Healey JH, et al. Strong association of SYT-SSX fusion type and morphologic epithelial differentiation in synovial sarcoma. *Diagn Mol Pathol* 2000;9(1):1-8.
63. Guillou L, Coindre J, Gallagher G, Terrier P, Gebhard S, de Saint Aubain Somerhausen N, et al. Detection of the synovial sarcoma translocation t(X;18) (SYT;SSX) in paraffin-embedded tissues using reverse transcriptase-polymerase chain reaction: a reliable and powerful diagnostic tool for pathologists. A molecular analysis of 221 mesenchymal tumors fixed in different fixatives. *Hum Pathol* 2001;32(1):105-12.
64. Kawai A, Woodruff J, Healey JH, Brennan MF, Antonescu CR, Ladanyi M. SYT-SSX gene fusion as a determinant of morphology and prognosis in synovial sarcoma. *N Engl J Med* 1998; 338(3):153-60.
65. Kawaguchi S, Wada T, Ida K, Sato Y, Nagoya S, Tsukahara T, et al. Phase I vaccination trial of SYT-SSX junction peptide in patients with disseminated synovial sarcoma. *J Transl Med* 2005;3(1):1.
66. Barco R, Garcia CB, Eid JE. The synovial sarcoma-associated SYT-SSX2 oncogene antagonizes the polycomb complex protein Bmi1. *PLoS One* 2009;4(4):e5060.
67. Skytting B, Nilsson G, Brodin B, Xie Y, Lundeberg J, Uhlén M, et al. A novel fusion gene, SYT-SSX4, in synovial sarcoma. *J Natl Cancer Inst* 1999;91(11):974-975.
68. Agus V, Tamborini E, Mezzelani A, Pierotti MA, Pilotti S. Re: a novel fusion gene, SYT-SSX4, in synovial sarcoma. *J Natl Cancer Inst* 2001; 93(17):1347-1349.
69. Brodin B, Haslam K, Yang K, Bartolazzi A, Xie Y, Starborg M, et al. Cloning and characterization of spliced fusion transcript variants of synovial sarcoma: SYT/SSX4, SYT/SSX4v, and SYT/SSX2v. Possible regulatory role of the fusion gene product in wild type SYT expression. *Gene* 2001;268(1-2):173-182.
70. Parra Gordo ML, Soleto Roncero MJ, Terriza Rueda MD, Marcuello Olona P, Mariño Espuelas JM, Castaño Pascual A. Congenital fibrosarcoma of the chest wall. *An Pediatr (Barc)* 2004; 61:565-7.

71. Lam PM, Leung TM, Ng PC, Vlantis AC, Wong W, Lau TK. Congenital cervical fibrosarcoma with hydrops Fetalis. *Acta Obstet Gynecol Scand* 2004;83:773-6.
72. Miura K, Han G, Sano M, Tsutsui Y. Regression of congenital fibrosarcoma to hemangiomatous remnant with histological and genetic findings. *Pathol Int* 2002;52:612-8.
73. Miser J, Triche T, Kinsella T. Other soft tissue sarcomas of childhood. In *Principles and Practice of Pediatric Oncology* (Pizzo P, Poplack D, eds). Philadelphia: Lippincott-Raven Publishers, 1997;865-888.
74. Ries LAG, Smith MA, Gurney JG, Linet M, Tamra T, Young JL, Bunin GR (Eds). *Cancer Incidence and Survival among Children and Adolescents: United States SEER Program 1975-1995*, National Cancer Institute, SEER Program. NIH Pub. No. 99-4649. Bethesda, MD, 1999.
75. Lejeune J, Turpin R, Gautier M. Mongolism; a chromosomal disease (trisomy) *Bulletin de l'Academie nationale de medecine* 1959; 143:256-265.
76. Bourgeois JM, Knezevich SR, Mathers JA, Sorensen PH. Molecular detection of the ETV6-NTRK3 gene fusion differentiates congenital fibrosarcoma from other childhood spindle cell tumors. *Am J Surg Pathol* 2000;24(7):937-46.
77. Gisselsson D, Andreasson P, Meis-Kindblom JM, Kindblom LG, Mertens F, Mandahl N. Amplification of 12q13 and 12q15 sequences in a sclerosing epithelioid fibrosarcoma. *Cancer Genet Cytogenet* 1998;107(2):102-6.
78. Tognon C, Knezevich SR, Huntsman D, Roskelley CD, Melnyk N, Mathers JA, et al. Expression of the ETV6-NTRK3 gene fusion as a primary event in human secretory breast carcinoma. *Cancer Cell*. 2002;2(5):367-76.
79. Wai D, Knezevich S, Lucas T, Jansen B, Kay R, Sorensen P. The ETV6-NTRK3 gene fusion encodes a chimeric protein tyrosine kinase that transforms NIH3T3 cells. *Oncogene* 2000; 19(7):906-915.
80. Tognon CE, Somasiri AM, Evdokimova VE, Trigo G, Uy EE, Melnyk N, et al. ETV6-NTRK3-mediated breast epithelial cell transformation is blocked by targeting the IGF1R signaling pathway. *Cancer Res* 2011;71(3):1060-70.
81. Tognon CE, Somasiri AM, Evdokimova VE, Trigo G, Uy EE, Melnyk N, et al. ETV6-NTRK3-mediated breast epithelial cell transformation is blocked by targeting the IGF1R signaling pathway. *Cancer Res* 2011; 71(3):1060-70.