

Report of two unrelated cases of Familial Thrombotic Thrombocytopenic Purpura

Bahram Darbandi MD¹, Adel Baghersalimi MD^{1,*}, Pantea Hajireza MD²

1. Pediatric Diseases Research Center, Guilan University of Medical Sciences, Rasht, Iran.

2. Guilan University of Medical Sciences, Rasht, Iran

*Corresponding author: Dr. Adel Baghersalimi, Pediatrics Growth Disorders Research Center, 17 Shahrivar pediatric Hospital, Faculty of Medicine, Guilan University of Medical Sciences, Rasht, Iran. Email: Baghersalimi498@yahoo.com. ORCID ID: 0000-0002-2062-0448

Received: 15 March 2019

Accepted: 22 December 2020

Abstract

Thrombotic Thrombocytopenic Purpura (TTP) is a rare microangiopathic disorder characterised by the pentad of microangiopathic hemolytic anemia, thrombocytopenic purpura, neurologic abnormalities, fever, and renal disease. Decreased production and/or activity of ADAMTS13 is the cause of this disorder. ADAMTS13 is a metalloproteinase which is responsible of the cleavage of high weight multimers of von Willebrand factor. Its acquired form is usually seen in adults and is due to antibody formation against the enzyme. But even rarer familial and relapsing forms (Upshaw-Scholman syndrome) are due to enzyme underproduction and can be seen in pediatric age group. Here, the authors reported two unrelated cases of familial TTP from Guilan province in the north of Iran.

Key words: ADAMTS13, Hemolytic anemia, Thrombotic Thrombocytopenic Purpura

Introduction

Thrombotic Thrombocytopenic Purpura (TTP) is caused by reversible aggregation of platelets in small vessels with intermittent ischemia of internal organs (1). This syndrome is characterized by a pentad, fever, schistocytic haemolytic anemia, thrombocytopenia, neurologic and renal involvement. All of these findings may not be existed at the same time (2, 3).

Annual incidence is estimated to be 1-6 cases per million and it is more prevalent in females than males (ratio: 3 to 2) (1, 3). Before treatment era with plasma pheresis/transfusion, the mortality rate was exceeding 90%. But now TTP is a curable disease with these approaches (1). TTP has two main clinical forms; the more prevalent acquired form and chronic or relapsing form. Acquired TTP is due to antibody formation against ADAMTS13; a metalloproteinase responsible for cleavage of high weight von willebrand multimers. But congenital or relapsing form (Upshaw-Scholman syndrome) is a rare form of TTP which is caused by decreased production of

the enzyme (1, 3). Upshaw-Scholman syndrome occurs in Less than 5% of all acute TTP patients (4). Here the authors reported two unrelated cases of Familial (congenital) TTP from Guilan province, north of Iran.

Case Report

Case1

A five-year-old girl was visited for the first time when admitted to the pediatric hematology ward due to thrombocytopenia in November 2013. On physical exam, many petechiae and purpuric lesions over the limbs, face, and chest were seen. Same lesions were also obvious in oral mucosa. Patient was pale and had mild conjunctival icterus. Other physical examinations were normal. Except neonatal jaundice that required exchange transfusion, she had nine previous admissions with the same complaints. These complaints started from 15 months and repeated at 20, 26, 38, 47, 48, 49, and 50 months old (2 times), respectively. Since 1st hospitalization, she was labelled as immune thrombocytopenic purpura with unexplained anemia and

managed with IVIG, corticosteroids, and packed RBC transfusions. Her growth and development was good. Parents were close relatives (cousins) and her older sibling was apparently normal. Table I summarizes laboratory findings during admission. During hospitalization, the patient was treated with IVIG and high dose methylprednisolone infusions and packed RBC transfusion. In order to explain simultaneous anemia and thrombocytopenia; she underwent some investigations. Direct Coomb's test result was negative and Table I shows results of other investigations. A striking finding was noted in peripheral blood smear examination where many schistocytes and helmet cells along with absence of platelets were seen (Figure 1). These findings raised the suspicion for congenital type of TTP. Therefore, a sample for ADAMTS-13 antigen withdrawn and fresh frozen plasma (FFP) (10ml/kg) transfused. Finally, after transfusion of PC and FFP, (10 ml/kg) the patient discharged five days after admission with good condition. Unfortunately, the sample was missed during transportation to laboratory, but antigen level measured at about 3 weeks and 2 months after discharge indicated very low levels of ADAMTS-13 antigen (0.12, 0.05 respectively; normal range 0.6-1.6mg/ml) without detectable antibody level. Regular follow up (every 2-3 months interval) did not show any clinical or laboratory abnormality. For about 18 months, the patient was symptom free, but after an episode of gastroenteritis, she developed thrombocytopenia in April 2015. Despite progressive thrombocytopenia; she had no bleeding tendency. Table 1 shows CBC parameters before and after FFP (10ml/kg) transfusion and a dramatic response.

Case 2

Patient was an eight-year-old girl of related parents and with birth weight of 3100gr and without familial history of hematologic disorders. She was hospitalized due to icter on the second day of her birth and received phototherapy. In addition, she received

packed RBC due to severe schistocytic haemolytic anemia (Hb= 4.8 g/dl) confirmed by peripheral blood smear examination. Figure 2 shows peripheral blood smear of the patient in one of the episodes of anemia. UltraSonography performed on the fifth day of birth showed bilateral hydronephrosis grade 2. After several packed RBC transfusions due to persistence of anemia, bone marrow examination was performed for the patient at 1 month of age. Except erythroid hyperplasia, bone marrow showed no abnormality. Since third months, the patient had several episodes of severe thrombocytopenia with petechiae and purpura. Some of those episodes occurred after viral respiratory infections and consequently managed as ITP. Several bone marrow examinations were non-diagnostic. The patient developed seizure without any obvious cause for the first time at 12 months old. The clinical picture of the patient complicated at 22 months old with vomiting, vertigo, ataxia, and 2 episodes of seizures. Brain CT scan performed at that time was normal, but blood urea nitrogen and creatinine levels were increased. Right sided hemiparesis when she aged 2.5 and protracted headache that complicated with attacks of dysarthria since 6 years old where other amazing medical history of the patient. This constellation of symptoms raised suspicion to congenital type of TTP, level of ADAMTS13 measured in January 2015 was 0.06% without detectable antibody level. Since that time and with the diagnosis of congenital type of TTP; patient is on regular FFP transfusion program (10 ml/kg; every 3 weeks). With regular transfusion program, hematologic and neurologic complications of the patient improved except moderate thrombocytopenia without bleeding tendency.

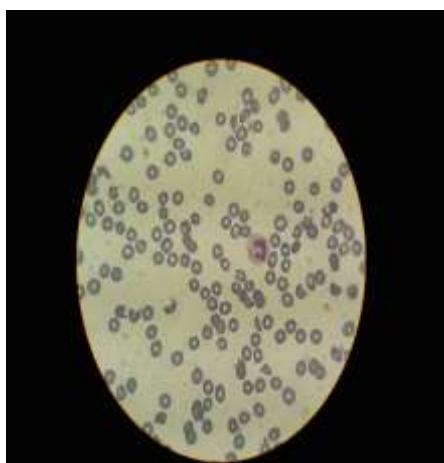


Figure 1: Peripheral blood smear of the case 1

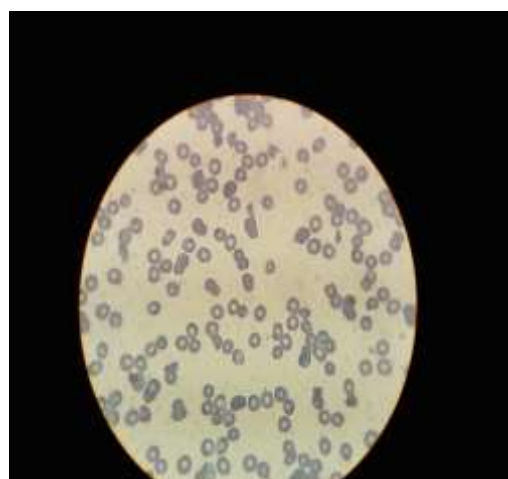


Figure 2: Peripheral blood smear of the case 2

Table 1: Laboratory data of the case 1

Lab data of previous admission	On admission	Before FFP transfusion	On discharge	
WBC	$5.6 \times 10^3/\text{L}$	$5.4 \times 10^3/\text{L}$	$5.6 \times 10^3/\text{L}$	
Hb	9.2 g/dl	5.7 g/dl	9.8 g/dl	
PLT	$<10 \times 10^9/\text{L}$	$<10 \times 10^9/\text{L}$	$152 \times 10^9/\text{L}$	
BUN	16 mg/dl	14 mg/dl	16 mg/dl	
Cr	0.5 mg/dl	0.6 mg/dl	0.6 mg/dl	
AST	38 U/L	36 U/L	36 U/L	
ALT	23 U/L	20 U/L	25 U/L	
LDH	2430 U/L	3400 U/L	960 U/L	
Lab data of recent admission	One day before FFP transfusion	On the day of FFP transfusion	One day after FFP transfusion	One week after FFP transfusion
WBC	$8.9 \times 10^3/\text{L}$	$8.3 \times 10^3/\text{L}$	$7.5 \times 10^3/\text{L}$	$5.6 \times 10^3/\text{L}$
RBC	3.7×10^6	3.4×10^6	4×10^6	5.1×10^6
Hb	9.6 g/dl	9.2 g/dl	9.8 g/dl	12.3 g/dl
PLT	$80 \times 10^9/\text{L}$	$30 \times 10^9/\text{L}$	$142 \times 10^9/\text{L}$	$430 \times 10^9/\text{L}$

WBC: White blood cell; Hb: Hemoglobin; PLT: Platelet; BUN: Blood urea nitrogen; Cr: Creatinine; AST: Aspartate aminotransferase; ALT: Alanin aminotranferase; WBC: White blood cell; RBC: Red blood cell. FFP: fresh frozen plasma

Discussion

Congenital TTP also known as Schulman-Upshaw syndrome (OMIM 274150) is a life-threatening disease, associated with the deficiency of the von Willebrand factor-cleaving protease (ADAMTS-13) due to mutations in the corresponding gene. The spectrum of clinical phenotype in congenital TTP is wide, encompassing neonatal-onset disease and adult-onset disease, forms with a single disease episode and chronic-relapsing forms (5). Congenital TTP is a rare disorder, with over 100 patients described worldwide, but this is likely to be an underestimate (3).

Clinical spectrum of the congenital TTP vary greatly. Fujimura et al. reviewed clinical presentation of 43 Japanese cases of congenital TTP; severe neonatal jaundice that requires exchange blood transfusion has been hallmark and was present in 18 of 43 (42%) patients (6). In other study conducted by Fujimura and colleagues, 29 (79%) of the 37 patients misdiagnosed as immune thrombocytopenic purpura (ITP) during childhood due to low platelet count (6). Stroke may be seen during neonatal period and episodes of thrombocytopenia and microangiopathic hemolysis weeks to years later can occur. Fever, infections, diarrhea, trauma, surgery and pregnancy may be the precipitating factors (8). Acute renal failure is other important finding and reported in 11% of the patients (9, 10).

With the best of our knowledge, this is the first case series report of congenital TTP from Guilan province in the north of Iran. These two patients from distinct families also have distinct presentations. While case 1 have experienced relatively milder course with a fixed history of thrombocytopenia and schistocytic haemolytic anemia, case 2 have had a more aggressive pattern. Our approach for these two cases were also distinct; while case 2 managed with regular FFP transfusion program, we did not believe that this program is justified for case 1 so we decided to treat the patient during episodes of anemia or thrombocytopenia. Unfortunately we were

unable to check ADAMTS-13 gene mutation in our cases.

Conclusion

All of the symptoms of TTP may or may not be seen simultaneously, so we recommend that in any patient with the diagnosis of ITP or haemolytic anemia who do not respond to standard treatment, TTP (congenital or acquired) should be considered.

Conflicts of Interest

There is no conflict of interest.

References

1. Wilson DB. The Acquired Platelet Defects. Hematology and Oncology of Infancy and Childhood. 8th Edition. Philadelphia, Elsevier: 2015: 1092-1106.
2. Scott JP, Montgomery RR. Thrombotic Thrombocytopenic Purpura. Nelson Textbook of Pediatrics. 19th Edition. Philadelphia: Elsevier 2011:1718-1719
3. Scully M, Hunt BJ, Benjamin S. Guidelines on the Diagnosis and Management of Thrombotic Thrombocytopenic Purpura and other Thrombotic Microangiopathies. British J Haematol 2012; 158: 323-335
4. Schneppenheim R, Hovinga JA, Becker T. A common origin of the 4143insA ADAMTS13 mutation. Thromb Haemos 2006; 96(07):3-6.
5. Lotta LA, Garagiola I, Palla R, Cairo A. ADAMTS13 mutations and polymorphisms in congenital thrombotic thrombocytopenic purpura. Hum Mut 2010; 31(1):11-19.
6. Fujimura Y, Matsumoto M, Isonishi A. Natural History of Upshaw-Schulman Syndrome based on ADAMTS-13 gene analysis in Japan. J Thromb Haemost 2011; 9:283-301.
7. Fujimura Y, Matsumoto M, Kokame K. Pregnancy-induced thrombocytopenia and TTP, and the risk of fetal death, in Upshaw-Schulman syndrome: a series of 15 pregnancies in 9 genotyped patients. Br J Haematol 2009; 144: 742-54.

8. Tsai HM. The Kidney in Thrombotic Thrombocytopenic Purpura. *Minerva Med* 2007; 98(6): 731–747.
9. Levy GG, Nichols WC, Lian EC. Mutations in a member of the ADAMTS gene family cause thrombotic thrombocytopenic purpura. *Nature* 2001; 413:488–494.
10. Shibagaki Y, Matsumoto M, Kokame K. Novel compound heterozygote mutations (H234Q/R1206X) of the ADAMTS13 gene in an adult patient with Upshaw-Schulman syndrome showing predominant episodes of repeated acute renal failure. *Nephrol Dial Transplant* 2006; 21:1289–1292