

## Severe phenotype of an Iranian patient with methemoglobinemia type II due to a novel mutation in the CYB5R3 gene

Jamal Manoochchri MSc<sup>1</sup>, Hamed Reza Goodarzi PhD<sup>1</sup>, Mojtaba Jafarinia PhD<sup>1</sup>, Hossein Jafari Khamirani MSc<sup>2</sup>, Seyed Mohammad Bagher Tabei PhD<sup>2,\*</sup>

1. Department of Genetics, Marvdasht Branch, Islamic Azad University, Marvdasht, Iran

2. Department of Medical Genetics, Shiraz University of Medical Sciences, Shiraz, Iran

\*Corresponding author: Dr. Mohammad Bagher Tabei, Associate Professor, Shiraz University of Medical Sciences, Shiraz, Iran. Maternal-Fetal Medicine Research Center, Shiraz University of Medical Sciences, Shiraz, Iran. Tabeismb@sums.ac.ir. ORCID ID: 0000-0001-9923-6969

Received: 09 February 2021

Accepted: 30 July 2021

### Abstract

Methemoglobinemia is a rare autosomal recessive genetic disease caused by disruptive mutations in the CYB5R3 gene (MIM: 250800). Herein, a novel mutation is reported in an Iranian patient affected with methemoglobinemia type II. In this case study, the patient is precisely described according to the thoroughly carried-out examinations and workups. In so doing, the peripheral blood sample was collected to evaluate the methemoglobin level and NADH-CYB5R3 activity test. Moreover, whole-exome sequencing (WES) was recruited to identify the mutation leading to this disorder. Subsequently, Sanger sequencing was employed to confirm the detected mutation. Magnetic Resonance Imaging was also performed to explore the structure of the brain. As identified by the blood test, the methemoglobin level increased up to 25%, and the NADH-CYB5R3 enzyme activity showed to be 13.8 IU/g of Hb. A novel homozygous mutation in CYB5R3 (NM\_001171661: g.23435C>T, c.181C>T, p.R61X, rs1210302322) was identified as the cause of the Methemoglobinemia type II in the proband. This nonsense mutation alters arginine to the stop codon at position 61 of protein in the FAD-binding domain that results in a truncated protein. The MRI revealed brain atrophy and corpus callosum hypoplasticity. It was established that this variation can lead to Methemoglobinemia. The proband demonstrates Methemoglobinemia type II phenotype such as cyanosis, severe mental retardation, microcephaly, as well as developmental delay. The brain MRI revealed brain atrophy and corpus callosum hypoplasticity.

The cyanosis symptom is managed by daily ascorbic acid uptake.

**Keywords:** CYB5R3 gene; Methemoglobinemia; NADH-cytochrome b5 reductase deficiency

### Introduction

Methemoglobinemia happens due to an increased level of methemoglobin. It is characterized by decreased oxygen-carrying capacity of red blood cells resulting in cyanosis and hypoxia. This condition occurs through three mechanisms: abnormal hemoglobin (Hb M) triggered by  $\alpha$ -globin or  $\beta$ -globin chain variation, environmental exposure to many toxic or oxidant agents that contribute to toxin-induced oxidation, and deficiency of methemoglobin reductase enzymes such as NADH-cytochrome b5 reductase 3(1).

In normal circumstances, approximately one percent of hemoglobin is found as

methemoglobin. Increased circulating levels of methemoglobin up to 25% induce patients to become symptomatic. When methemoglobin amounts to 70% of total hemoglobin, it can lead to vascular collapse, coma, and even death. Autosomal recessive hereditary methemoglobinemia (RHM) is a rare condition induced by homozygote or compound heterozygote mutation in the CYB5R3 gene. RHM with pleiotropic tissue effects divides into two categories: type I and type II. The CYB5R3 gene encodes NADH-cytochrome b5 reductase 3. This enzyme is involved in the oxidation-reduction reaction; it catalyzes the transfer of

reducing equivalents from NADH to cytochrome b5. Ultimately, cytochrome b5 can act as an electron donor and reduce methemoglobin to hemoglobin (2). The structure of the NADH-CYB5R3 enzyme consists of two functional domains joined by a flexible hinge. The FAD-binding domain locates in the N-terminal of the protein, but the NADH-binding domain exists in the C-terminal. These two domains are linked by a small linker domain which is a requisite part of the maintenance of the enzyme structure (4).

The CYB5R3 gene is located on chromosome 22q13, spans more than 32 kb of DNA, and contains nine exons (3). This gene produces two isoforms of NADH-cytochrome b5 reductase by alternative promoter/splicing: membrane-bound isoform anchored to the cytoplasmic face of the endoplasmic reticulum, mitochondrial outer membrane, and plasma membrane is expressed in all cells, and soluble isoform which is only expressed in erythrocytes. These two isoforms are the same except for the N terminal of the enzymes involved in anchoring to the membrane bilayer (5).

Membrane-bound isoform includes an extra exon upstream of the first exon of the soluble isoform (1). The membrane-bound isoform contains 300 amino acids consisting of catalytic and membrane-binding domains; it functions in some physiological processes such as fatty acid elongation and desaturation, cholesterol biosynthesis, hydroxylation of steroid hormones, CYP-450-mediated detoxification, and drug metabolism. The soluble isoform consists of 275 amino acid residues. It is produced from the transcript without exon one, so it contains merely the catalytic domain and plays a role in methemoglobin reduction (6). Mutations in the CYB5R3 scattered throughout the gene, and those that trigger incorrect splicing, disturbance of the active site, or truncation of the enzyme are generally associated with type II, which is a more severe category (2). Methemoglobinemia

type I is attributed to defects in the soluble isoform that is restricted to erythrocytes and mostly presents no clinical demonstrations other than cyanosis; it is, therefore, a well-tolerated form although patients may manifest associated symptoms such as shortness of breath and mild fatigue, subsequently. In RHM type II, both the soluble and membrane-bound isoforms of the enzyme are disrupted thus affecting erythrocytes and all body tissues. Type II methemoglobinemia is, therefore, generalized and associated with more severe conditions than cyanosis, including mental retardation, myelination defects, microcephaly, generalized dystonia, and other neurologic symptoms that may be related to the main role of the cytochrome b5 system in the desaturation of fatty acids (7). In the present study, a 6-year-old female is reported with a novel pathogenic variant (NM\_001171661: c.181C>T, p.R61X), a nonsense mutation, causing a severe form of RHM II. Cyanosis, severe mental retardation, microcephaly, developmental delay, growth retardation, headache, hypertonia, and mild fatigue have all been observed in the proband. The patient is homozygous for mutation.

## Case Report

In this case study, the proband was physically examined meticulously. Additional suitable laboratory and diagnostic tests were carried out. The peripheral blood sample was collected for supplementary studies. The parents of the proband were examined for the concerns related to the purpose of the study. Written informed consent was obtained from each subject individually or, in the case of minors, from their parents. This study was approved by the Ethical Committee of Shiraz University of Medical Sciences. This article was couched in accordance with the CARE statement (8).

## DNA extraction

Genomic DNA was extracted from the patient's peripheral white blood cells using

QIAamp DNA Blood Mini Kit according to the manufacturer's protocol.

### Exome sequencing

Whole exome sequencing (WES) was performed on the genomic DNA extracted from the patient's white blood cells using HiSeq 3000/4000 SBS Kit.

### Data analyzes

The raw data, converted by HiSeq X, were lined up against the human reference genome (hg19) by the Burrows-Wheeler Aligner (9). The single-nucleotide polymorphisms (SNPs) were called by the GATK software (Genome Analysis ToolKit). Variants were also annotated using ANNOVAR(10). All variants were classified into five categories including pathogenic, likely pathogenic, variants of unknown clinical significance (VUS), likely benign, and benign based on the standards for the interpretation of sequence variations recommended by ACMG. The candidate gene phenotypic features were compared with the patient's phenotype. Core phenotypes of the mutations were obtained from the OMIM database and utilized to acquire a gene list of the virtual panel by the OMIM database (OMIM # 250800).

### Sanger sequencing

This pathogenic variant was confirmed by Sanger sequencing. To amplify the fragments containing the mutated sites of the genome, PCR was conducted. In so doing, the researcher utilized the PCR Master Mix-BLUE (25 µL), 70 ng of DNA, 1 µL of forward primer (F CYB5R3 E5: AGTGAAGGCATGGAGGCA), 1 µL of reverse primer (R CYB5R3 E5: CTGCAAGCCCCTGAGGAA), 2.5 µL of DMSO, and 19 µL deionized water. The primers were designed using Oligo Primer Designer (11). (Table I. PCR primers used in this study). The DNA was amplified deploying the following thermocycling steps: 95 °C for 15 min; 35 cycles of 95 °C for 30 sec; 62 °C for 30 sec; 72 °C for 5 sec; and 72 °C for 5 min.

### Case data

The proband is a 6-year-old Iranian female born to consanguineous parents with RHM II. (Figure 1. Pedigree of the family illustrating the inheritance of the pathogenic variant in this family). The patient suffering from cyanosis and hypoxia at birth was, therefore, considered for further investigation. In addition, she showed signs of RHM II patients including developmental delay, severe mental retardation, microcephaly, growth retardation, hypertonia, and difficulty in speech. In addition, the patient complained about headaches and mild fatigue. She also showed signs of developmental milestones and language developmental delay; her first word appeared when she was four years old. Also, growth delay was notable in the patient. She now takes daily ascorbic acid for her condition which has ameliorated her cyanosis symptoms.

A novel variant (NM\_001171661: c.181C>T, p.R61X) was detected as the cause of the severe phenotype in the subject. This nonsense mutation converts arginine to stop codon at position 61 of protein at the FAD-binding domain. (Figure 2. The position of proband mutation). This premature stop codon results in a truncated protein that can be degraded by the Nonsense-Mediated Decay (NMD) mechanism. The proband is homozygous for this mutation whereas her parents are unaffected heterozygotes who carry (NM\_001171661: c.181C>T) pathogenic variant of the CYB5R3 gene. (Figure 3. Electropherogram of the family) The blood test displayed MetHb saturation percentage increasing up to 25%. NADH-CYB5R3 enzyme activity test proved to be 13.8 IU/g of Hb. (Table II. Blood test results in this study). The MRI of her brain taken at 11 months revealed brain atrophy and corpus callosom hypoplasticity. (Figure 4. The brain MRI of the proband).



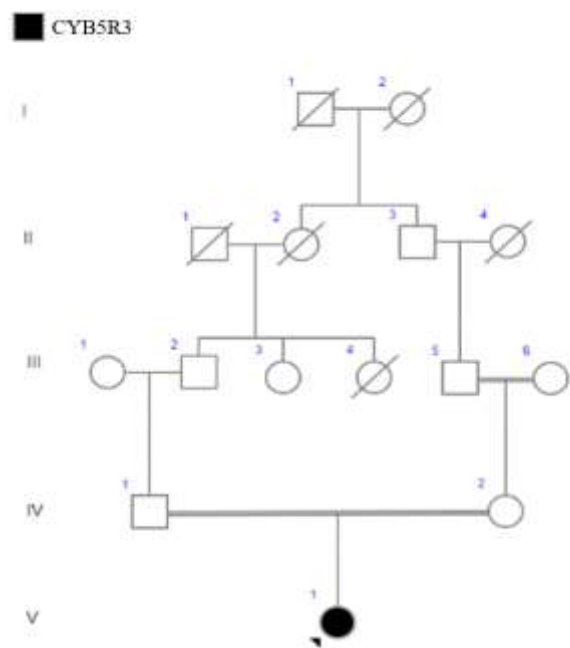


Figure 1. Pedigree of the family illustrating the inheritance of the pathogenic variant in the family. Proband is V-1.

10	20	30	40	50
MGAQLSTLGH	MVLFPVWFLY	SLLMKLFQRS	TPAITLESPO	IKYPLRLIDR
60	70	80	90	100
↓				
EIISHDTRRE	RFALPSPQHI	LGLPVGQHIY	LSARIDGNLV	VRPYTPISSD
110	120	130	140	150
DDKGEVDLVI	KVYFKDTHPK	FPAGGKMSQY	LESMQIGDTI	EFRGPSGLLV
160	170	180	190	200
YQGKGKFAIR	PDKKSNPIIR	TVKSVGMIAG	GTGITPMLQV	IRAIMKDPDD
210	220	230	240	250
HTVCHLLFAN	QTEKDILLRP	ELEELRNKHS	ARFKLWYTLD	RAPEANDYGQ
260	270	280	290	300
GFVNEEMIRD	HLPPPEEEPL	VLMCGPPPMI	QYACLPNLDH	VGHPTERCFO

Figure 2. *CYB5R3* protein sequence(12). Gray highlights demonstrate the FAD-binding domain (40-152) and the arrow shows the position of proband mutation (p.R61X).

[Downloaded from ijpho.ssu.ac.ir on 2024-05-04]

[DOI: 10.18502/ijpho.v11i4.7173]

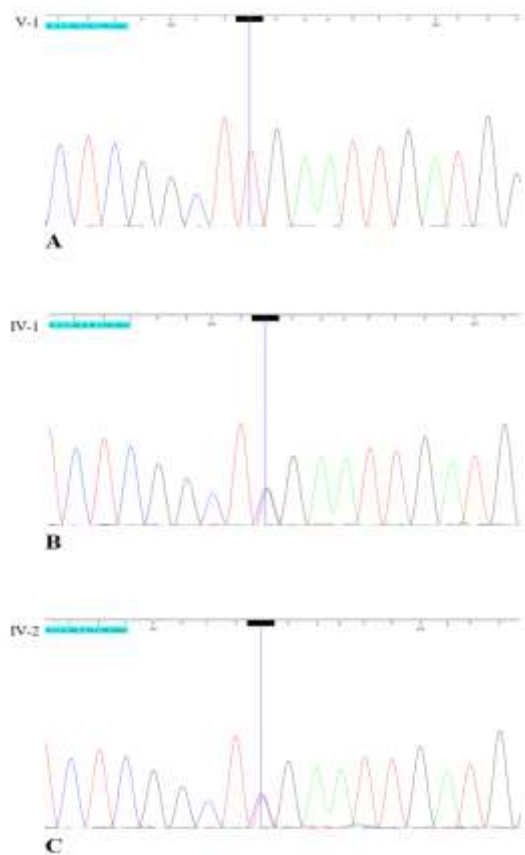


Figure 3. Electropherogram of the family. A; electropherogram of the proband (individual V-1). B; electropherogram of the individual IV-1. C; electropherogram of the individual IV-2.

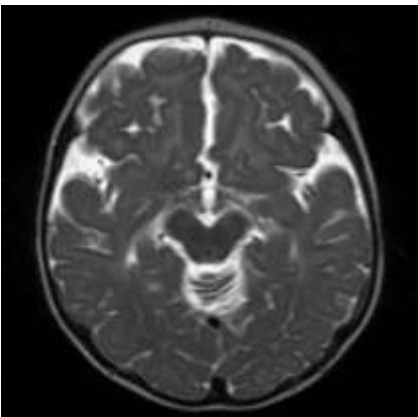


Figure 4. The brain MRI of the individual V-1 (without contrast): Brain atrophy is notable. The corpus callosum is hypoplastic.

Table I. PCR primers were used in this study

Gene	Primer	Sequence (5'-3')	Direction	Reference
<i>CYB5R3</i>	F <i>CYB5R3</i> E5	AGTGAAGGCATGGAGGCA	Forward	(11)
	R <i>CYB5R3</i> E5	CTGCAAGCCCCTGAGGAA	Reverse	

Table II: Laboratory results of the participants

Subject	Age	Gender	Variation in <i>CYB5R3</i>	Genotype	Inheritance	Hb (g/dl)	HCT (%)	RBC ( $\times 10^3$ )	WBC ( $\times 10^3$ )	PLT ( $\times 10^3$ )	MetHb/Hb (%)	NADH- CYB5R3 enzyme activity
<b>individual V-1 (proband)</b>	6 Years	female	g.23435C>T, c.181C>T, p.R61X, rs1210302322	Homozygous	AR	12.8	42	6.3	5.8	410	24.97	13.8
<b>individual IV-1</b>	33 Years	male	g.23435C>T, c.181C>T, p.R61X, rs1210302322	Heterozygous	AR	13.3	40.1	5.15	8.6	270	5.6	21.6
<b>individual IV-2</b>	28 Years	female	g.23435C>T, c.181C>T, p.R61X, rs1210302322	Heterozygous	AR	11.2	34	4.4	6.4	340	4.1	20.6

.Hb; hemoglobin, HCT; Hematocrit, RBC; red blood cell, WBC; white blood cell, PLT; platelets, AR; Autosomal dominant.

## Discussion

Recessive hereditary methemoglobinemia is a rare disorder caused by CYB5R3 mutation. About 70 variations, ranging from benign to pathogenic, all over this gene have been reported, nearly 40 of which are pathogen including different types of mutations such as missense, nonsense, frameshift, inframe Indel, and splice site. Importantly, missense mutations are the most prevalent ones (13). Some of these mutations lead to a truncated product or incorrect mRNA splicing. RHM II is associated with a defect in enzymatic activity resulting from truncated mutations whereas RHM I mostly relates to missense mutations. However, no definite pattern is known to predict RHM type based on mutation types (14). Molecular analyses have revealed some of the mutations being common in both types of RHM. For example, the V252M mutation in the NADH-binding domain can generate both types of RHM (15). Also, an intermediate phenotype with milder neurological manifestations reflects the clinical variability of this condition. These findings suggest that genetic, metabolic and, even environmental factors bear the potential to determine the severity of the phenotypes of each type of RHM (14,16). Cyanosis is a common symptom in both types of RHM that is manifested at birth while neurological phenotype appears about five months later. Consequently, identifying cyanosis symptoms such as blue skin or brown blood is the only approach for its early diagnosis (2). Therefore, the exact incidence of congenital methemoglobinemia, being rare, remains to be known (17). RHM II is even rarer than the other type, i.e., RHM I, and life expectancy tends to decrease in these patients. Brain developmental deficiency, encephalopathy, and progressive microcephaly are observed in all patients with RHM II. Other neurological symptoms such as developmental delay, seizures, epilepsy, alteration in the white matter of the brain,

and dystonia can be identified in RHM type II. Aphasia, failure to thrive, scoliosis, and strabismus are also observed in some of the patients (18,19). Daily consumption of ascorbic acid or methylene blue can help treat cyanosis symptoms in both types of RHM (20,21). Furthermore, ascorbic acid therapy can improve motor skills features in RHM II patients (22). The current case presented severe neurologic problems such as severe mental retardation, developmental delay, microcephaly, aphasia, and hypertonia. In addition, growth retardation, developmental milestones delay, and language developmental delay were notable. Furthermore, brain atrophy and corpus callosum hypoplasticity were observed following MRI. The patient manifested cyanosis and hypoxia at birth being managed by ascorbic acid treatment following the diagnosis of RHM II, however, not improving her motor skills defects. The methemoglobin level increased up to 25%. This case appeared to have a novel variant (NM\_001171661: c.181C>T, p.R61X) in the CYB5R3 gene. Due to the severity of the subject's phenotypes and the nature of mutation leading to a truncated protein that is probably degraded by the NMD mechanism, this mutation can develop a severe form of RHM II. The etiology of RHM is unclear and poorly known; no treatment for encephalopathy associated with this condition and neurological deterioration has to date been identified. Further studies are thus needed to provide better information about the etiology, diagnosis, and effective treatment of RHM.

## Conclusion

In this case study, an Iranian patient with phenotype was described connected with RHM II. This report introduced a novel pathogenic variation (NM\_001171661: c.181C>T, p.R61X) in the CYB5R3 gene that can trigger severe symptoms as was observed in this case. This new mutation was confirmed by Sanger sequencing.



## Funding

This study was financially supported by Fars Science and Research Branch, Marvdasht Islamic Azad University (Grant No. IR.SUMS.MED.REC.1399.170).

## Acknowledgements

The authors would like to thank the staff of the Comprehensive Medical Genetics Center (Shiraz, Fars province, Iran) for their kind assistance.

## Conflicts of Interest

There is no conflict of interest.

## References

- Siendones E, SantaCruz-Calvo S, Martín-Montalvo A, Cascajo M V, Ariza J, López-Lluch G, et al. Membrane-bound CYB5R3 is a common effector of nutritional and oxidative stress response through FOXO3a and Nrf2. *Antioxidants Redox Signal* 2014;21(12):1708–1725.
- Percy MJ, Lappin TR. Recessive congenital methaemoglobinaemia: Cytochrome b5 reductase deficiency. *Br J Haematol* 2008;141(3):298–308.
- Hudspeth MP, Joseph S, Holden KR. A novel mutation in type II methemoglobinemia. *J Child Neurol* 2010;25(1):91–93.
- Ward J, Motwani J, Baker N, Nash M, Ewer AK, Toldi G. Congenital methemoglobinemia identified by pulse oximetry screening. *Pediatrics* 2019;143(3):1-9.
- Gagnier JJ, Kienle G, Altman DG, Moher D, Sox H, Riley D, et al. The CARE Guidelines: Consensus-based Clinical Case Reporting Guideline Development. *Glob Adv Heal Med* 2013;2(5):38–43.
- Li H, Durbin R. Fast and accurate long-read alignment with Burrows-Wheeler transform. *Bioinformatics* 2010;26(5):589–95.
- Wang K, Li M, Hakonarson H. ANNOVAR: functional annotation of genetic variants from high-throughput sequencing data. *Nucleic Acids Res* 2010;38(16):e164.
- Rychlik W. OLIGO 7 primer analysis software. *Methods Mol Biol* 2007;402:35–60.
- Consortium TU. The Universal Protein Resource (UniProt). *Nucleic Acids Res* 2008;36(1):D190–195.
- Kopanos C, Tsiolkas V, Kouris A, Chapple CE, Albarca Aguilera M, Meyer R, et al. VarSome: the human genomic variant search engine. *Bioinformatics* 2019;35(11):1978–1980.
- Siendones E, Ballesteros M, Navas P. Cellular and Molecular Mechanisms of Recessive Hereditary Methaemoglobinaemia Type II. *J Clin Med* 2018;7(10):341-345.
- Percy MJ, Crowley LJ, Roper D, Vulliamy TJ, Layton DM, Barber MJ. Identification and characterization of the novel FAD-binding lobe G75S mutation in cytochrome b 5 reductase: An aid to determine recessive congenital methemoglobinemia status in an infant. *Blood Cells Mol Dis* 2006;36:81–90.
- Percy MJ, Barnes C, Crighton G, Leventer RJ, Wynn R, Lappin TR. Methemoglobin Reductase Deficiency: Novel Mutation Is Associated With a Disease Phenotype of Intermediate Severity. *J Pediatr Hematol Oncol* 2012;34(6):457–60.
- Ewencyk C, Leroux A, Roubergue A, Laugel V, Afenjar A, Saudubray JM, et al. Recessive hereditary methaemoglobinaemia, type II: Delineation of the clinical spectrum. *Brain* 2008;131(3):760–771.
- Mannino EA, Pluim T, Wessler J, Cho MT, Juusola J, Schrier Vergano SA. Congenital methemoglobinemia type II in a 5-year-old boy. *Clin Case Reports* 2018;6(1):170–178.
- Stevens M, Frobisher C, Hawkins M, Jenney M, Lancashire E, Reulen R, et al. The British Childhood Cancer Survivor Study: Objectives, methods, population structure, response rates and initial descriptive information. *Pediatr Blood Cancer* 2008;50(5):1018–1025.