

Case Report

Unilateral Ptosis as Initial Manifestation of Acute Myeloid Leukemia

Besharati M R MD¹, Rezaee T MD², Hashemi A MD³, Taghipour Zahir S MD⁴

1. Department of Ophthalmology, Faculty of Medicine, Shahid Sadoughi University of Medical Sciences and Health Services, Yazd, Iran

2. Ophthalmology Resident, Shahid Sadoughi University of Medical Sciences and Health Services, Yazd, Iran

3. Department of Pediatrics, Hematology, Oncology and Genetic Research Center, Shahid Sadoughi University of Medical Sciences and Health Services, Yazd, Iran

4. Department of Pathology, Shahid Sadoughi University of Medical Sciences and Health Services, Yazd, Iran

Received: 16 June 2012

Accepted: 8 August 2012

Abstract

Background

In Acute Myeloid Leukemia (AML), malignant clones of immature myeloid cells (primarily blasts) proliferate, replace bone marrow, circulate in blood and invade other tissues. The unique presentation of unilateral ptosis and unilateral eyelid swelling in AML has been reported during the present study.

Case Report

A 7-year-old girl was encountered with progressively increasing unilateral right eyelid swelling and ipsilateral ptosis. There was no systemic manifestation of leukemia. Computed tomographic image reported right orbit anteromedial mass.

A high total leucocytic count in cell blood count with low platelet, the bone marrow aspirate and biopsy showing leukemic blast cells confirmed the diagnosis of AML. After diagnosis, an orbital MRI was done, which revealed a mass lesion antromedial of right orbit related to soft-tissue tumor. The patient was treated by chemotherapeutic drugs associated with intravenous steroids.

Conclusion

Unilateral ptosis and eyelid swelling is an initial manifestation of AML that has not been reported previously. A peripheral blood smear with bone marrow aspirate and biopsy helps in the early detection of AML. We should consider AML in any orbital mass with unknown origin.

Keywords

Leukemia, Orbital Neoplasm, Blepharoptosis

Corresponding Author

Rezaee T MD, Ophthalmology Resident, Shahid Sadoughi University of Medical Sciences and Health Services, Yazd, Iran

Introduction

Acute myeloid leukemia (AML) is uncommon in children, representing about 15% of all leukemia in the pediatric population (1). Granulocytic sarcoma (GS) is an orbital complication of acute myeloid leukemia (AML) with a tumor of immature hematopoietic precursor cells, localized in extra medullary tissues (2).

As several variants of acute AML have few or no cells of granulocytic lineage, the term myeloid sarcoma is currently preferred. The disease occurs primarily in children younger than 10 years of age.

Although in children, the orbit is a favored site for GS, other types of cancer are much more common in this location. Thus, a GS arising in the orbit may present a significant diagnostic dilemma when the mass precedes systemic findings of AML.

The diagnosis is made by clinical examination, computerized tomography and confirmed by hematological investigations. The treatment approach is based on chemotherapy associated with intravenous steroid therapy. During the present study, we have reported the case of a 7-year-old girl who was presented with unilateral ptosis, revealing acute myeloid leukemia.

Case report

A 7-year-old girl presented with a 1-month history of gradually progressive ptosis and eye lid swelling of the right eye after failing treatment for a presumed allergic reaction. She had no constitutional signs or symptoms. Her best-corrected visual acuity was 20/20 bilaterally.

On physical examination, she had unilateral right ptosis without any inflammatory signs.

Right inter palpebral fissure was 8mm with 1.5mm (Marginal light reflex distance) light reflex distance from upper eye lid margin (MRD 1) and left side was 11mm with 4.5mm MRD1. Levator excursion was measured 5mm and 12mm for right and left eye, respectively. Ocular motility was normal (Fig 1).

Computed tomography demonstrated an intra medial mass in right orbit. For more details, MRI without contrast was performed that defined a mass lesion antromedial of right orbit by greater diameter of 12 mm. There was no bone erosion or sinus or brain involvement.

The lacrimal gland, optic nerve, and extra ocular muscles were not involved; right lid edema was noted (Fig 2).

Excisional surgery was suggested but preoperative laboratory studies, including a complete blood count and white blood cell differential revealed thrombocytopenia (platelet 35000/mm³), anemia (hemoglobin 9.1 g/dl) and elevated white-blood cell count of 11800 /mm³, with many atypical lymphocytes and blasts on peripheral smear. Hence, bone marrow biopsy was done that demonstrated infiltration of bone marrow by myeloblasts (more than 30%) and more than 20% of non erythroid cells of monocytic origin. Eosinophils number also showed an increase, so our diagnosis was AML-M4 eo (Fig 3).

For definitive diagnosis flow cytometric analysis was also done.

Following diagnosis, the patient underwent chemotherapy with a combination of daunorubicin and cytosine arabinoside in two phases, an intensive phase for seven days and a maintenance phase. Chemotherapy was associated with intravenous steroid therapy.

Discussion

It is well known that AML can be seen initially with orbital involvement before the diagnosis of the underlying disease as occurred in our case (3). Soft-tissue accumulations of leukemic cells were referred to as granulocytic sarcoma (4). GS is an unusual manifestation of leukemia, seen in only about 5% of Caucasian cases of AML (5). It originally termed 'chloroma' because of the greenish hue resulting from the large amount of myeloperoxidase present, these tumors can also be gray, white, or brown, depending on the

oxidative state of this enzyme. Therefore, the more general term 'granulocytic sarcoma' (or occasionally 'myeloid sarcoma') is now employed.

The incidence of GS in Western literature appears to be decreasing, but there is significant geographic and racial variation. The orbit appears to be a favored site for GS in the pediatric population.

In a study of Turkish patients, ocular granulocytic sarcoma (OGS) occurred in 20 (36%) of 56 children with AML. Similarly, in a review of pediatric leukemia in Africa, almost half of the patients with AML had OGS. Importantly, there appears to be a very strong association of OGS with those AML cases demonstrating a t (8; 21) translocation, and the presence of the t (8; 21) in AML is associated with a good prognosis (6). GS is thought to occur in bone marrow and then spread via Haversian canals to penetrate periosteum and form a soft-tissue mass.

This would account for the typical location near bony structures. These tumors occur most frequently in the skull, sinuses, orbits, spine, ribs, sacrum, and sternum (7).

The occurrence of orbital myeloid sarcoma before the development of systemic leukemia is not uncommon and was reported in 29 of 33 cases (88%) in the largest study of orbital myeloid sarcoma by Zimmerman (8). The subsequent development of leukemia usually occurs within 5–12 months (9-10). The clinical features of orbital myeloid sarcoma can vary considerably. Proptosis is the most common presenting clinical sign (4, 6, and 11).

Various other presentations have been described including lacrimal gland involvement, eyelid tumor, ptosis, iris tumor, uveitis, conjunctival mass, and scleral mass (6, 12, 13). The diagnosis of orbital myeloid sarcoma can be challenging, particularly when there is no evidence of systemic leukemia. Retinoblastoma, the most common orbital

tumor in children, occurs within the globe. It is therefore, non-significant differential consideration in this case. After the exclusion of retinoblastoma, rhabdomyosarcoma is the most common orbital tumor in children, but it is usually located in the superior orbit (14). Metastatic neuroblastoma, Ewing's sarcoma, or histiocytosis usually demonstrates more osteolysis.

Although orbital lymphoma would be a likely diagnosis in an adult, lymphoma rarely occurs within the orbit in children. Inflammatory pseudotumor typically appears as inflammation of the dura around the optic nerve or extraocular polymyositis. Orbital hemangioma, the most common vascular tumor of the orbit, is typically retrobulbar and enhances strongly (15). At T1-weighted MRI, OGS, like many other soft-tissue tumors, is slightly hypersignal to gray matter, muscle, and bone marrow. At T2-weighted imaging, it is isosignal to white matter, muscle, and bone marrow (5). CT shows the mass to be isodense to muscle.

Homogeneous enhancement occurs with either modality (14). Clinical and hematological evidences raise suspicion of orbital myeloid sarcoma but the diagnosis is proven by biopsy. It is strongly suggestive if there are an elevated white blood cell count and peripheral (more than 5%) and medullar (more than 30%) blasts with the presence of an Auer Rod, which is pathognomonic for AML (16). Prognosis for patients with GS is better than for many other subtypes of AML (4), and preliminary reports suggest the prognosis is even better when the marrow contains less than 5% blasts (17). Thus, prompt diagnosis and initiation of therapy may be important for these cases.

Conclusion

OGS is an unusual tumor of the orbit, and can be seen prior to the recognition of systemic AML. The diagnosis of granulocytic sarcoma must be considered in any orbital mass of uncertain origin. It is based on clinical findings, imaging study

results and hematological findings. Early initiation of treatment may improve outcome of patients, and therefore a timely and correct diagnosis of OGS is important.

Acknowledgement

The authors would like to thank Research Center of Hematology and Oncology, Shahid Sadoughi University of Medical Sciences, Yazd, Iran, for their highly appreciated cooperation.

Conflict of Interest

We have no conflict of interest.

References

- 1-Cohen M Imaging of children with cancer. Mosby-Year Book, St Louis: 1992.
- 2-Bonig H, Gobel U, Nurnberger W. Bilateral exophthalmos due to retro-orbital chloromas in a boy with t(8;21)—positive acute myeloblastic acute leukemia. *Pediatric Hematol Oncol.*2002; 19(8):597-600.
- 3-Shields JA, Shields CL. Lymphoid tumors and leukemias. In: Atlas of orbital tumors. Lippincott Williams & Wilkins, Philadelphia PA, 1999; 316–340.
- 4-Hmidi K, Zaouali S, Messaoud R, Mahjoub B. Bilateral orbital myeloid sarcoma as initial Manifestation of acute myeloid leukemia. *IntOphthalmol* 2007; 27:373–377.
- 5-Pui MH, Fletcher BD, Langston JW. Granulocytic sarcoma in childhood leukemia: imaging features. *Radiology*1994; 190:698–702.
- 6-Stein-Wexler R., Wootton-Gorges S.L , West D.C. Orbital granulocytic sarcoma: an unusual presentation of acute myelocytic leukemia. *PediatrRadiol* 2003; 33: 136–139.
- 7-Schwyzzer R, Sherman GG, Cohn RJ,et al. Granulocytic sarcoma in children with acute myeloblastic leukemia and t(8,21). *Med PediatrOncol* 1998; 31:144–149.
- 8-Zimmerman LE, Font RL. Ophthalmologic manifestations of granulocytic sarcoma (Myeloid sarcoma or chloroma). The third Pan American Association of Ophthalmology and American Journal of Ophthalmology Lecture. *Am J Ophthalmol.*1975; 80(6):975-90.
- 9-Shields JA, Stopyra GA, Marr BP et al. Bilateral orbital myeloid sarcoma as initial sign of acute myeloid leukemia: case report and review of the literature. *ArchOphthalmol* 2003; 121(1):138–142.
- 10-Bulas RB, Laine FJ, Das Narla L. Bilateral orbital granulocytic sarcoma(chloroma) preceding the blast phase of acute myelogenous leukemia: CT findings. *PediatrRadiol* 1995;25:488–489.
- 11-Cavdar AO, Babacan E, Gozdasoglu S et al .High risk subgroup of acute myelomonocytic leukemia (AMML)with orbito-ocular granulocytic sarcoma (OOGS) in Turkish children: retrospective analysis of clinical, hematological,ultrastructural and therapeutic findings of thirtythreeOOGS. *ActaHaemat* 1989; 81:80–85.
- 12-GrossniklausHE,WojnoTH. Leukemic infiltrate appearing as periorbital cellulitis. *Arch Ophthalmol* 1990;108:484.
- 13-Jordan DR, Noel LP, Carpentier BF. Chloroma. *Arch Ophthalmol* 1991;109:734.
- 14-JakobiecFA. Granulocyticsarcoma. *Am J Neuroradiol* 1991;12:263–264.
- 15-BarkovichAJ. Pediatric neuroimaging. Lippincott-Raven, Philadelphia 1995;85-86.
- 16-Blanchard S, Labalette P, Jourdel D et al. Orbital granulocytic sarcoma revealing acute myeloblastic syndrome: a case study. *J FrOphtalmol* 2004;27(2):184–187.
- 17-Dusenbery KE, Arthur DC, Howells W,etal. Granulocytic sarcomas (chloromas) in pediatric patients with newly diagnosed acute myeloid leukemia (abstract). *Proc ASCO* 1996;15:369.

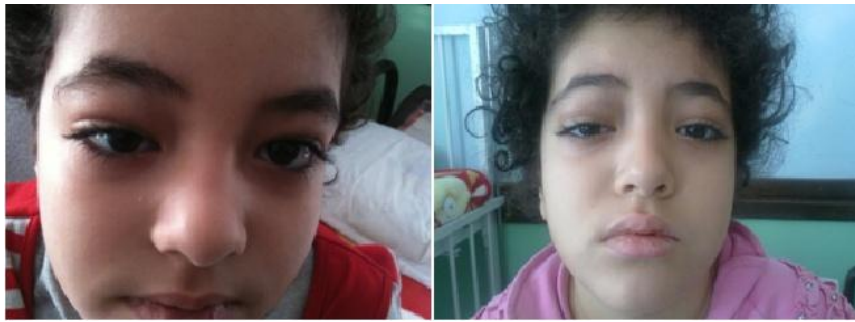

Figure 1. Right eyelid swelling and ptosis

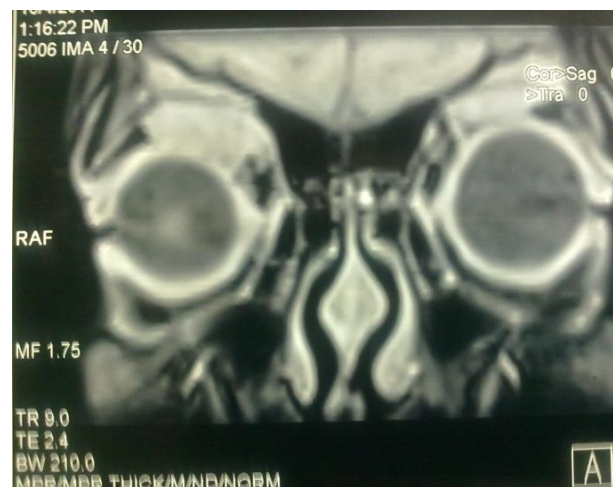


Figure 2. MRI imaging defines a mass lesion antero-medial of right orbit by greater diameter of 12 mm, There is no bone erosion or sinus or brain involvement. The lacrimal gland and extra-ocular muscles are not involved, right lid edema is noted.

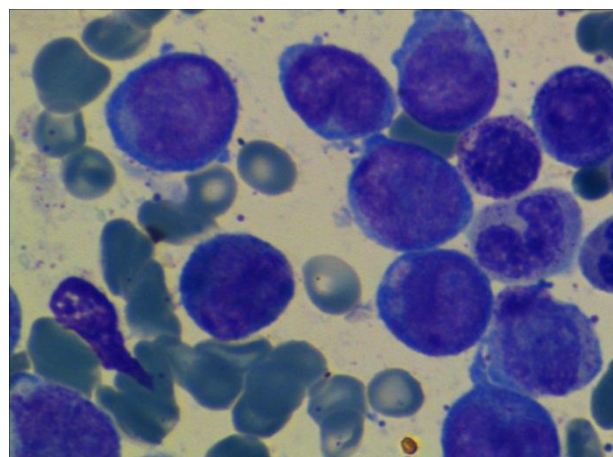


Figure 3. Bone marrow biopsy demonstrates infiltration of bone marrow by myeloblasts (more than 30%) and more than 20% of nonerythroid cells of monocytic origin, eosinophils were also increased in numbers