

Kikuchi Fujimoto Disease with Rare Demonstrations Associated with Lupus Erythematosus without Obvious Clinical Symptoms: A Case Report

Farzad Ferdosian MD^{1,2}, Fariba Binesh MD^{2,3}, Marzie Vaghefi MD^{1,*}, Ehsan Sanaei MD⁴

1. Department of Pediatrics, shahid sadoughi University of Medical Science, Yazd, Iran.

2. Hematology and Oncology Research Center, Shahid Sadoughi University of Medical Sciences, Yazd, Iran.

3. Department of pathology, shahid sadoughi University of Medical Science, Yazd, Iran.

4. Department of Internal medicine, shahid sadoughi University of Medical Science, Yazd, Iran.

*corresponding author: Dr Marzie Vaghefi, Resident of Pediatrics, Department of Pediatrics, shahid sadoughi University of Medical Science, Yazd, Iran. Email: : mh.vaghefi1991@gmail.com. Orchid ID: 0000-0002-8528-5329

Received: 24 February 2020

Accepted: 18 may 2020

Abstract

Kikuchi Fujimoto Disease (KFD), also known as necrotic histiocystic lymphadenitis, is a condition with unknown etiology. Probably, infectious, viral, and also autoimmune etiologies, especially lupus erythematosus, contribute to this disorder. The common signs are lymphadenopathy along with fever and leukopenia. Our case was a 13-year-old boy with fever of unknown origin. He underwent ordinary fever of unknown origin (FUO) investigations and the only positive finding on his examination was lymphadenopathic fever of posterior cervical chain. The results of primary tests and also cultures of blood and urine samples did not have any specific contribution to diagnosis of infectious causes. Besides, bone marrow aspiration and biopsy led to the exclusion of chances of lymphoma or other malignancies. Finally, diagnosis of KFD was confirmed by the use of dissection of cervical lymph nodes and also via immunohistochemical tests and simultaneous positive antinuclear antibody (ANA). Hence, the patient was put on suitable medical treatment for lupus. Given the rare demonstrations of this case, i.e., the male sex and fever of unknown origin, and also the positive ANA despite clear clinical symptoms of lupus, this case was presented to provide both proper education and make a faster and more appropriate diagnosis.

Keywords: Fever of unknown origin, Kikuchi Fujimoto Disease, Lupus erythematosus.

Introduction

KFD, also known as necrotic histiocystic lymphadenitis, was first reported in Japan in 1972. It is often reported in young women manifested by localized lymphadenopathy, usually in the cervical region (1-3). Other demonstrations of the condition include fever/pyrexia and leukopenia in %50 of the patients (4). The etiology of Kikuchi is unknown; yet, probable causes have been mentioned such as Epstein-Barr virus (EBV), Human T-cell Leukemia Type I, cytomegalovirus, brucellosis, yersinia, and para-influenza virus (5). Case studies have also referred to the role of autoimmune mechanisms in the creation of the disease. The condition has also been reported to co-occur with lupus (5). Theoretically, in lupus, apoptic cells

predispose to the expression of numerous nuclear antigens at the cell surface. In some patients, deficient ability to clear these new antigens, similar to what is seen in cases of deficiency of complement, leads to the creation of the initial nucleus of autoimmune lupus and concurrent Kikuchi (6). Some experts refer to Kikuchi as a kind of lupus with unusual demonstrations. Santana et al. found about 35 reports of association between lupus and Kikuchi through reviewing the available literature up to 2003 (7). No fully useful treatment has been recommended for this disease yet. Its demonstration may be fully benign and self-restraining, healing during 1-4 months. Since it is possible that some patients manifest demonstrations of lupus, it is advised that

most patients be followed up meticulously (8). The cause of introducing this patient was the rare demonstration of the disease in a boy, i.e., the male sex, who did not have clear clinical evidence of lupus or other autoimmune diseases.

Case Report

A 13-year-old boy presented with primary demonstration of prolonged fever since 21 days ago with exacerbation at the last hours of the day. He reported no history of diarrhea, vomiting, cough, dyspnea, urinary symptoms and limb or joint pain. He reported occasional abdominal pain and also reduced appetite and weight loss of almost 1 kg over the recent 21 days. He had no history of recent travel, contact with animals or tuberculosis patients and a long history of previous consumption of dairies. Moreover, he had a history of tonsillectomy at 5 years of age, complete vaccinations, and no history of risky sexual behavior. Over the last 21 days, he was hospitalized for 3 days in a treatment center for hydration and antibiotic therapy with ceftriaxone leading to a mild alleviation of fever. However, he was referred to Shahid Sadoughi Hospital in Yazd, central Iran, due to recurrence of fever of unknown origin (FUO). On examination, the vital signs were BP=100/70 mmHg, heart rate=80 bpm, respiration rate=18 per min, and oxygen saturation=%98 using pulse oximetry in ambient (room) temperature. The patient's body temperature was measured at 1-hour intervals and registered as 38.7 and 38.9°C. Head and neck examination showed numerous cervical lymphadenopathies of the right posterior chain (third and fourth cervical zones) measuring 1*1.5 cm. These lymph nodes were mobile with no adhesion to the surrounding tissue and slightly tender to palpation with firm contour. Moreover, right supraclavicular lymphadenopathies measuring 0.5*0.5 cm without adhesion and tenderness were reported. The cardiopulmonary examination was normal

and abdominal examination was not remarkable. The tests, presented to the physician by the patient, indicated normochromic anemia, normocytes, high lactate dehydrogenase (LDH), and high erythrocyte sedimentation rate (ESR) (Table I). Furthermore, test results on admission still revealed high ESR, and hepatic tests suggested high hepatocellular patterns (Table I). Coagulation tests showed normal urine analysis, smear, and stool culture and peripheral blood test was not remarkable.

Table I: Tests before and on admission completed for the patient

Tests	Previous hospitalization (22.9.2019)	On admission (23.9.2019)
WBC(diff)*10³	(neutrophil %55) 8.9	9.2
RBC*10⁶	4.55	4.2
Hb	11	10
Platelet	345000	331000
ESR	44	67
CRP	2 (positive)	4 (positive)
Wright	Negative	Negative
Coombs Wright	Negative	Negative
2ME	Negative	Negative
SGOT	34	243
SGPT	29	161
LDH	1200	1450

Chest x-rays had no remarkable demonstration. The ultrasonography of liver, gallbladder, spleen, pancreas, kidneys, and urinary ducts were normal. The portal vein flow and diameter were also normal. On the basis of prolonged fever and supraclavicular lymphadenopathy suspicious of lymphoma, the patient was candidate of bone marrow aspiration and biopsy (BMA & BMB) and the results were negative for malignancies and lymphomatous involvement. Complementary tests showed positive results of anti-toxoplasma and anti-cytomegalovirus IgG levels higher than 300 and 20, respectively. Yet, the immunoglobulin M (IgM) levels were negative for both. The viral markers of

hepatitis B and C and also human immunodeficiency viruses (HIV) were negative. Blood sample culture was also negative after 7 days. Besides, the result of bone marrow aspiration cultured in Bactec medium was negative. The IgM level against Epstein-Barr virus was negative, too. Considering the examinations and uncertainty about the definite diagnosis, biopsies of cervical lymph nodes were excised. The microscopic pathological examination revealed necrotic lymphadenitis with surrounding necrotic foci of histiocytes, lymphocytes, and immunoblasts (Figures 1,2). The results of immunohistochemical stains are displayed in Table II. The results of these stains and also the pathological findings of lymph node biopsies confirmed Kikuchi Fujimoto Disease. Complementary tests also reported positive antinuclear antibody (ANA). Given the simultaneous positive ANA and positive results of immunohistochemical tests, parenteral methyl prednisolone (30 mg /kg) maximum dose of 1 gr q24h was prescribed for the patient for 3 days. At the end of the parenteral dose, oral prednisolone 50 mg/day was continued. Besides, hydroxychloroquine 200 mg/day was administered. Weekly follow up showed that the patient's fever and lymphadenopathy had improved. Presently, prednisolone 40 mg/day and hydroxychloroquine 200 mg/day are administered.

Table II: Immunohistochemical findings of cervical lymph nodes

Finding	Cluster of differentiation(CD)
Multifocal positive	CD4
Positive in numerous lymphocytes	CD8
Diffusely positive	CD68
Positive in numerous lymphocytes	CD2
Positive in remnant follicles and scatteredly	CD20

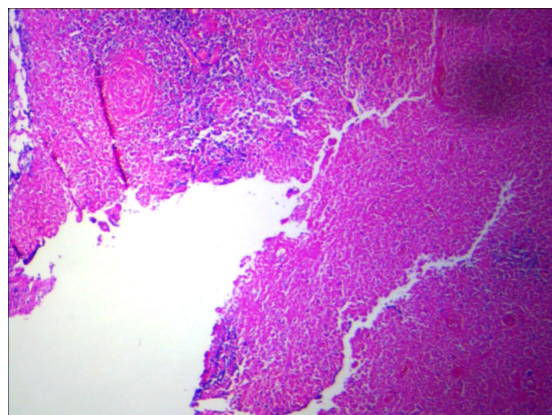


Figure 1. Section shows patchy areas of necrosis, irregularly shaped are randomly distributed.

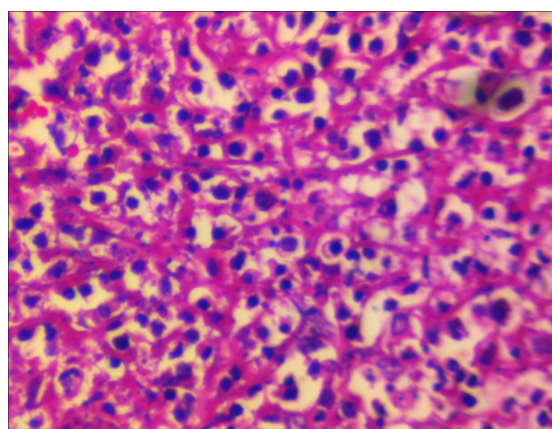


Figure 2. Section reveals that the cellular debris is actively phagocytosed by numerous histiocytes, cells with abundant cytoplasm and peripheral, compressed, crescentic nuclei resembling signet-ring cells.

Discussion

Kikuchi Fujimoto Disease (KFD) is an idiopathic disorder that occurs mostly in young women. Nonetheless, the case reported here was a 13-year-old boy and the rare demonstration of the diseases in a male patient justifies reporting his case (2). Furthermore, given the initial demonstration of the patient which was fever of unknown origin (FUO), it can be differentiated from similar cases that mostly present with lymphadenopathy. However, some similar studies mention fever as the main symptom in about half of the affected patients (2, 3, 11). One specific characteristic of this patient that somehow distinguished him from similar cases, was the absence of symptoms of lupus erythematosus

in spite of laboratory test evidence and high ANA. Similar studies refer to lupus as the main disorder among the autoimmune disturbances that are manifested in association with Kikuchi. The clinical signs and symptoms may demonstrate themselves concurrently with Kikuchi or after it (5-7). The patient reported in this case study did not have any of the clinical signs of lupus and only the autoimmune antibody test of ANA was positive. The important differential diagnosis of KFD may include lymphoproliferative conditions like various lymphomata (4). Of course, the malignancies and lymphomata were excluded in this case using excisional biopsies. The immunohistochemical evidence of the biopsies of lymph nodes with positive CD at CD2, CD4, CD8, CD20, and CD68 suggests the active disease indicating that given the positive ANA of the patient, the disease has a greater chance of progressing to lupus erythematosus. The case report by Tina Mahajan et al. that explored a KFD record with lupus confirms our analysis (9). Finally, on the basis of what was speculated on KFD and our case, it may be concluded that noting the uncommon signs and symptoms of a rare disease can have both effective educational outcomes and prompt diagnosis and treatment of the disease.

Conflicts of Interest

No conflict of interest exists between Dr Poonam Sherwani and Co-authors.

References

1. Kikuchi M. Lymphadenitis showing focal reticulum cell hyperplasia with nuclear debris and phagocytes. *Acta Hematol Jpn* 1972; 35:379–380.
2. Elfihri S, Laine M, Kettani F, Ben Amor J, Bourkadi JE. Kikuchi-Fujimoto disease: about a case. *Pan Afr Med J* 2017; 28; 144-147.
3. Kaur S, Thami GP, Kanwar AJ. Kikuchi's disease, skin and systemic lupus erythematosus. *Br J Dermatol* 2002; 146(1):167–168.
4. Norris AH, Krasinskas AM, Salhany KE, Gluckman SJ. Kikuchi-Fujimoto disease: a benign cause of fever and lymphadenopathy. *Am J Med* 1996; 101(4):401–405.
5. Kodet R, Campr V, Kalinová M, Kamarádová K, Mrhalová M, Soukup J. Histiocytic necrotizing lymphadenitis / Kikuchi-Fujimoto disease (HNL/K-F) and its differential diagnosis: analysis of 19 patients. *Cesk Patol* 2012; 48(4):198-206.
6. Marrack P, Kappler J, Kotzin BL. Autoimmune disease: why and where it occurs. *Nat Med* 2001;7(8):899–905.
7. Lewis MJ, Botto M. Complement deficiencies in humans and animals: links to autoimmunity. *Autoimmunity* 2006; 39(5): 367-378.
8. Santana A, Lessa B, Galrao L, Lima I, Santiago M. Kikuchi-Fujimoto's disease associated with systemic lupus erythematosus: case report and review of the literature. *Clin Rheumatol* 2005; 24(1):60–63.
9. Litwin MD, Kirkham B, Henderson DR, Milazzo SC. Histiocytic necrotizing lymphadenitis in systemic lupus erythematosus. *Ann Rheum Dis* 1992; 51(6):805–807.
10. Mahajan T, Merriman RC, Stone MJ. Kikuchi-Fujimoto disease (histiocytic necrotizing lymphadenitis): report of a case with other autoimmune manifestations. *Proc Bayl Univ Med Cent* 2007; 20(2):149-51.
11. Lopez C, Oliver M, Olavarria R, Sarabia MA, Chopite M. Kikuchi-Fujimoto necrotizing lymphadenitis associated with cutaneous lupus erythematosus: a case report. *Am J Dermatopathol* 2000; 22(4):328–333.