

B-cell lymphoma presenting as acute pancreatitis symptoms in a childSanaz Mehrabani MD^{1,*}, Hassan Mahmoodi Nesheli MD¹

1. Non-Communicable Pediatric Diseases Research Center, Health Research Institute, Babol University of Medical Sciences, Babol, IR Iran

*Corresponding author: Dr. Sanaz Mehrabani, Non-Communicable Pediatric Diseases Research Center, Health Research Institute, Babol University of Medical Sciences, Babol, Iran. Email: mehrabanisanaz@gmail.com. ORCID ID: 0000-0002-2062-0448

Received: 07 February 2019**Accepted:** 05 August 2019**Abstract**

Lymphoma which has a wide range of manifestations is the third malignancy in pediatrics. Nearly, 50% of patients have extranodal involvement. Pancreas can be affected secondarily more than primarily. A 10-year-old boy with recurrent abdominal pain in the epigastric region for six weeks was referred to Amirkola Children's Hospital, affiliated to Babol University of medical sciences (north of Iran). The patient was icteric with elevated levels of amylase and lipase. A hypoechoic mass near the head of the pancreas was detected by ultrasound examination. Pathology of stomach polyps revealed small blue round-cell tumor compatible with a lymphoma. In children with acute pancreatitis symptoms and palpable abdominal mass, the non-Hodgkin lymphomas (NHL) should be considered as an important, though rare possible cause.

Key words: B cell lymphoma, Child, Pancreatitis**Introduction**

Lymphomas divided into Hodgkin (HL) and non-Hodgkin lymphomas (NHL) are one of the most common malignancies in pediatric age (1). NHL is one of the small round-cell tumors (2).

Nearly, 50% of patients have extranodal involvement (3). Stomach and intestines are the most sites in which the lymphoma can develop, while the involvement of pancreas is rare, (4) with the prevalence between 0.2% and 2% (3). Pancreas can be affected secondarily more than primarily (5). In some cases of NHL, the abdominal involvement is manifested by pancreatitis symptoms such as increased amylase and lipase enzymes, abdominal pain, nausea, and vomiting.

This case report introduced a child with B-cell lymphoma (BL), who had acute pancreatitis symptoms.

Case Report

In 2018, a 10-year-old boy was referred to Amirkola Children's Hospital (affiliated to hospital of Babol University of Medical

Sciences) with compliant of recurrent abdominal pain in epigastric region lasting for six weeks, which was aggravated by eating. The pain was not improved by proton pump inhibitors (PPIs) and had worsened since 3 weeks before the onset of the current study, especially two days before his referral. His abdominal pain was improved by bending forward and aggravated in a supine position. The patient became icteric, had vomiting without fever, and his bowel habit was normal. According to patient's past medical history, he was the first child, weighed 35 kg and his parents were not relatives.

Last year, he had a seizure without fever and was treated with carbamazepine 200 mg daily. Moreover, he had allergic sinusitis.

His family history indicated that his father was infected with hepatitis B in past and recovered.

The results of his physical examinations were as follows:

Vital signs: Temperature=37.8°C, Pulse rate=95/min, Respiratory rate=16/min, and Blood pressure= 90/70 mm/Hg.

Sclera was icteric and conjunctiva was pale.

Abdominal examination revealed tenderness and a mass in epigastric region, but liver and spleen sizes were normal. Intestinal sounds had normal patterns.

Neck, chest, and extremities exams were normal.

Laboratory data revealed the following results:

Complete Blood Count (CBC):

White Blood Cell (WBC)=7.8/ μ L, Hemoglobin (Hb)=9.1 g/dL, Red Blood Cell (RBC)=3.86/ μ L, Hematocrit (HCT)=29.8%, Platelet (PLT)=412/ μ L, Mean Corpuscular Volume (MCV)=77.2fL, Mean corpuscular hemoglobin (MCH)= 23.6pg, Mean corpuscular hemoglobin concentration (MCHC) =30.5g/dL, Blood Sugar (BS)=92mg/dl (<200).

Venous Blood Gas (VBG): (to evaluate acid-base status)

pH= 7.39, PCO₂= 38.3 mmHg, HCO₃= 23.3 mmol/L, Blood urea nitrogen (BUN)= 8.8 mg/dL(7-17), Creatinine= 0.5 mg/dL(0.7-1.4), Calcium = 9.1 mg/dL (8-11),

Aspartate aminotransferase (AST) = 208 IU/l(up to 37), Prothrombin time (PT)= 12s(12-14), Amylase= 116IU/l(up to 100), Alanine aminotransferase (ALT)= 196IU/l(up to 41),

International normalized ratio (INR)= 1.2, Lipase= 258IU/l(up to 38), Alkaline phosphatase (ALP)= 1624 IU/l(180-1200), Partial thromboplastin time (PTT)= 20s(30-45), Total protein= 7.9 g/dL(6-8), Lactate dehydrogenase (LDH)= 1586U/L, Sodium (Na)= 136 mEq/L(130-148),

C-reactive protein (CRP) = 55 mg/dL(up to 6), Potassium (K)= 4.1mEq/L(3.5-5.5), Albumin= 4.5 g/dL(3.5-5.2), Triglyceride= 340 mg/dL (up to 200), Urine/Analysis & Urine /Culture= Normal (NL), Cholesterol= 196 mg/dL (up to 200), Retic= 2.5%, Direct coombs= negative,

CBC 2 (after 2 days): WBC=7.8/ μ L, Hb= 7.3g/dL, RBC=2.9/ μ L, HCT=23%, PLT=424/ μ L, MCV=79fL, MCH=25pg, MCHC=31g/dL, Amilase2=1200IU/l, Lipase2=2000IU/l, Hepatitis B surface antigen (HBSAg)=negative, Anti human immunodeficiency viruses (HIV) antibody (Ab)=negative, Anti Hepatitis A virus (HAV) Ab=negative, Anti Hepatitis C virus (HCV) Ab=negative, Tissue Transglutaminase Ab (TTG)= negative, Glucose-6-phosphate dehydrogenase (G6PD)=20% (Sufficient), Alpha-Fetoprotein (α FP)=negative, Wright=negative, Widal=negative, Stool occult blood (OB)=positive, Beta Human chorionic gonadotropin (hCG)=negative, Cerebrospinal fluid (CSF)=NL, Epstein-Barr virus (EBV) Ab=negative, ceruloplasmin=NL.

Echocardiography, was necessary for cardiac assessment before administration of cardiotoxic chemotherapy drugs. Echocardiography and Chest X-ray were normal.

Abdominal sonography illustrated a 53 *36 mm hypoechoic mass near the head of pancreas and para-aortic lymph nodes. Biliary ducts and gallbladder were dilated. Abdominopelvic spiral CT scan demonstrated multiple polypoid masses in the stomach, a 60*58 mm mass near the head of pancreas, and multiple hypoechoic masses as well as dilated biliary ducts and gallbladder in the kidney (Figure 1 & 2).

Upper gastrointestinal (GI) endoscopy indicated normal esophagus, and the biopsy was taken from the lower part.

Numerous polyps were seen in his body and fundus of the stomach, and multiple biopsies were done. Erosion in the duodenal bulb was detected (Figure 3 & 4).

Endoscopic pathology findings were as follows:

Esophagus: Esophagitis

Stomach: Mild chronic gastritis

Polyps of stomach: a small blue round-cell tumor compatible with lymphoma (Figure 5).

ICD: C16/9(location of pathology code), M=(diagnosis code) 9590/3, IHC (immunohistochemistry) performed on gastric tissue → B- Cell Lymphoma

Bone marrow aspiration revealed reduced erythroid, megakaryocyte, myeloid, and increased lymphocytes (Figure 6).

Cytochemistry of bone marrow revealed following information: (performed on bone marrow aspiration)

Myeloperoxidase= negative, PAS= negative, CD2= 14.1, CD33= 4.6, CD34= 2.3, CD45= 92.6, CD117= 2.9, TDT= 0.7, CD56= 1.6, CD8= 17.7, CD2= 14.1, CD3= 33.6, CD4= 7, CD5= 18.5, CD7= 11.1, CD20= 83.9, CD10= 26.6, CD19=19, CD15= 12.4, HLADW/DR= 74.9

Immunophenotype exhibited mononuclear population, and about 40% of all nucleated cells were mainly composed of B-lymphoid cells.

Cytogenetic evaluation performed during follow-up, representing that all chromosomal translocations including, t (8,14) , t (2,8) and t (8,22), were negative.

The patient received systemic chemotherapy (for stage 4 BL) and COMPE regimen (cyclophosphamide 100 mg/m², vincristine 1.5 mg/m², methotrexate 300 mg/m², prednisone 60 mg mg/m² and etoposide 75 mg/m²) for seventeen cycles every four weeks, that seemed better for this patient condition.

A one-month chemotherapy resulted in normal levels of amylase, lipase, and liver enzymes. Icteric and abdominal pain were recovered, and the pseudocyst of pancreas was not detected in follow-up sonography.

The patient was followed monthly with doing complete physical examination and laboratory tests as well as imaging if needed.

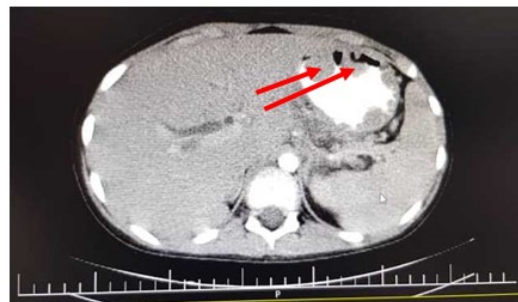


Figure 1: Abdominopelvic CT scan (multiple polyps in stomach)

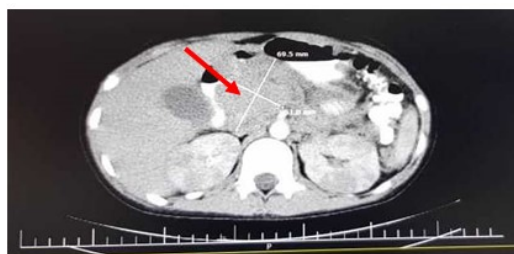


Figure 2: Abdominopelvic CT scan (para-pancreatic mass)

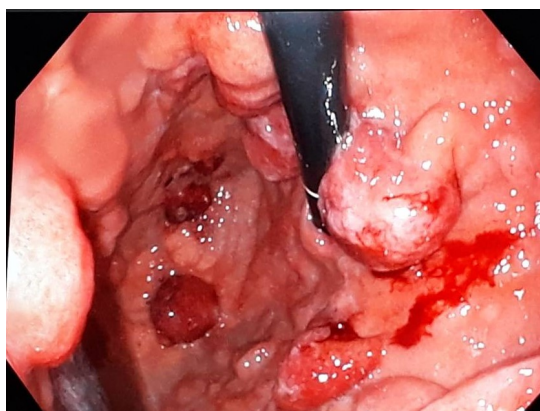


Figure 3: Endoscopy of stomach (polyps at fundus)

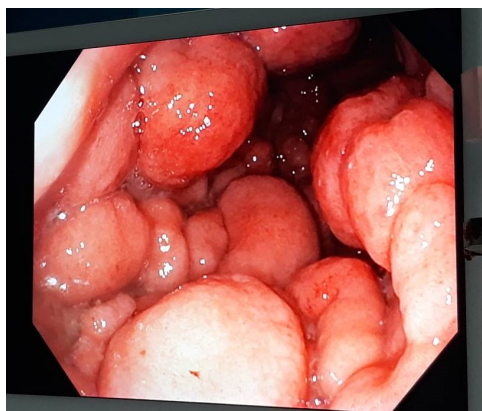


Figure 4: Endoscopy of stomach (polyps at body)

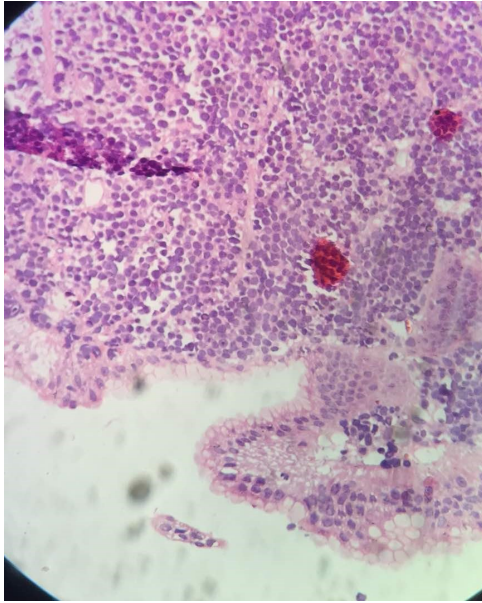


Figure 5: Pathology of polyp of stomach

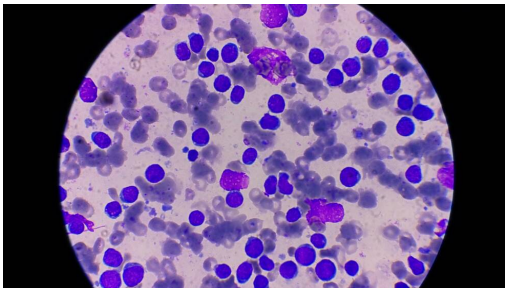


Figure 6: Microscopic findings of bone marrow aspiration.

Discussion

The incidence of lymphoma varies across the world. About 60% of lymphomas are NHL which accounts for 8% of all pediatric malignancies (6). Near in 70% of cases, the disease present with extranodal involvement (1). The most common age of onset in children is between 5 and 9 years (7-9), but the case of the current study was a 10-year-old boy. The BL mostly occurs in males (8). Gastrointestinal tract is one of the most frequent sites of NHL involvement, and about 90% of the primary GI lymphomas are BLs (10, 11). Patients can present with abdominal pain, anorexia, weight loss, diarrhea, and ileus (12). The present case had epigastric pain worsened by eating. Marginean et al. reported four cases with

NHL who were presented with abdominal pain, loss of appetite, vomiting, and diarrhea (1). BL can involve bone marrow and, in rare cases, the pancreas can be involved (13, 14). In the 10-year-old boy who was diagnosed with mature BL (15), the bone marrow was involved but had the symptoms of pancreatitis. The patient had epigastric pain with elevated levels of amylase and lipase. Ultrasound revealed a 53*36 mm hypoechoic mass near the head of pancreas and para-aortic lymph nodes, which was confirmed by CT scan results. The CT scan also indicated that the disease was multifocal and there were polypoid lesions in the stomach. Eisenhuber et al. reported a 14-year-old boy with pancreatic NHL mass, who was presented with pancreatitis (16). Both ultrasound and CT scan showed para-pancreatic masses. The overall incidence of pancreatitis like multifocal manifestation of the BL is very low in children (17). The diagnosis of NHL is based on imaging, which should be confirmed by biopsy. In cases with abdominal masses, the CT scan is useful to determine surgical sites and other involved sites. In children, the prognosis of NHL is very good. Previous studies suggested that the survival of the patients increased from 73% to 90% in the recent decade (in cases less than 10 years old (18). Although the exact factors contributing to survival in patients with NHL have not been delineated yet, high level of LDH is considered to be a negative predictor (1).

Conclusion

In children with acute pancreatitis symptoms and palpable abdominal mass, the NHL should be considered as an important, though rare possible cause.

Acknowledgment

The authors are grateful to the Clinical Research Development Committee of Amirkola Children's Hospital, Health Research Institute, Non-Communicable Pediatric Diseases Research Center of Babol University of Medical Sciences and

Mrs. Faeze Aghajanzpour for their contribution to this study.

Conflicts of Interest

There is no conflict of interest.

References

1. Marginean CO, Meliș LE, Horvath E, Gozar H, Chinceșan MI. Non-Hodgkin lymphoma, diagnostic, and prognostic particularities in children—a series of case reports and a review of the literature (CARE compliant). *Med* 2018; 97(8): 1-8.
2. Rajwanshi A, Srinivas R, Upasana G. Malignant small round cell tumors. *J Cytol* 2009;26(1):1-10.
3. Kiresi DA, Kivrak AS, Ecirli S, Toy H. Secondary breast, pancreatic, and renal involvement with non-Hodgkin's lymphoma: imaging findings. *The Breast* 2006; 15(1): 106-110.
4. Saif MW. Primary pancreatic lymphomas. *Jop* 2006;7(3):262-273.
5. Joly I, David A, Payan M, Sahel J, Sarles H. A case of primary non-Hodgkin lymphoma of the pancreas. *Pancreas* 1992; 7(1): 118-120.
6. Nunnari G, Smith JA, Daniel R. HIV-1 Tat and AIDS-associated cancer: targeting the cellular anti-cancer barrier? *J Experiment Clin Cance Res* 2008; 27(1): 1-8.
7. Mwanda O, Rochford R, Moormann AM, Macneil A, Whalen C, Wilson ML. Burkitt's lymphoma in Kenya: geographical, age, gender and ethnic distribution. *East Afr Med J* 2004 (8): 68-77.
8. Shapira J, Peylan-Ramu N. Burkitt's lymphoma. *Oral Oncol* 1998; 34(1): 15-23.
9. Kabyemera R, Masalu N, Rambau P, Kamugisha E, Kidenya B, De Rossi A, et al. Relationship between Non-Hodgkin's lymphoma and blood levels of Epstein-Barr Virus in children in north-western Tanzania: a case control study. *BMC Pediatr* 2013; 13(1): 1-7.
10. Saka R, Sasaki T, Matsuda I, Nose S, Onishi M, Fujino T, et al. Chronic ileocolic intussusception due to transmural infiltration of diffuse large B cell lymphoma in a 14-year-old boy: a case report. *Springer Plus* 2015; 4(1): 366-370.
11. Li B, Shi Y-k, He X-h, Zou S-m, Zhou S-y, Dong M, et al. Primary non-Hodgkin lymphomas in the small and large intestine: clinicopathological characteristics and management of 40 patients. *Inter J Hematol* 2008; 87(4): 375-381.
12. Koch P, Del Valle F, Berdel WE, Willich NA, Reers B, Hiddemann W, et al. Primary gastrointestinal non-Hodgkin's lymphoma: I. Anatomic and histologic distribution, clinical features, and survival data of 371 patients registered in the German Multicenter Study GIT NHL 01/92. *J Clin Oncol* 2001; 19(18): 3861-3873.
13. Araújo JP, Sampaio-Macedo C, Sousa L. Pancreas Burkitt primary lymphoma in pediatric age. *Revista española enfermedades digestivas* 2017; 109(6): 451.
14. Koca T, Aslan N, Dereci S, Akcam M. Burkitt lymphoma with unusual presentation: Acute pancreatitis. *Pediatr Inter* 2015; 57(4): 775-777.
15. Swerdlow SH, Campo E, Pileri SA, Harris NL, Stein H, Siebert R, et al. The 2016 revision of the World Health Organization classification of lymphoid neoplasms. *Blood* 2016; 127(20): 2375-2390.
16. Eisenhuber E, Schoefl R, Wiesbauer P, Bankier AA. Primary pancreatic lymphoma presenting as acute pancreatitis in a child. *Med Pediatr Oncol* 2001;37(1):53-54.
17. Lerner A, Branski D, Lebenthal E. Pancreatic diseases in children. *Pediatr Clin* 1996;43(1): 125-156.
18. Pulte D, Gondos A, Brenner H. Trends in 5-and 10-year survival after diagnosis with childhood hematologic malignancies in the United States, 1990–2004. *JNCI* 2008;100(18): 1301-1309.