

A cytology negative rare tumor with the presentation of pseudotumor cerebri clinical symptoms: diffuse leptomeningeal glioneuronal tumor

Merve Feyza Yüksel MDI^{1,*}, Ömer Bektaş PhD¹, Ömer Suat Fitöz PhD², Özben Akıncı Göktaş MD¹, Süleyman Şahin MD¹, Serap Teber PhD¹

1. Department of Pediatric Neurology, Ankara University Medical School, Turkey

2. Department of Radiology, Ankara University Medical School, Turkey

*Corresponding author: Dr. Merve Feyza Yüksel, Department of Pediatric Neurology, Ankara University Medical School, Ankara, Turkey. Email: mervefeyza42@hotmail.com. ORCID ID: 0000-0002-2062-0448

Received: 28 March 2020

Accepted: 22 November 2020

Abstract

Diffuse leptomeningeal glioneuronal tumor is characterized by hydrocephalus, leptomeningeal involvement in the absence of a primary parenchymal mass, and negative cerebrospinal fluid (CSF) cytology. It is an extremely rare and difficult tumor to diagnose as no mass can be biopsied and it mimics infectious, rheumatologic, and inflammatory pathologies. An 11-year-old girl presented with complaints of headache, vomiting, and double vision. On examination, there was papilledema. Initial MRI scanning did not yield any significant findings. Clinical progression was observed in four months in the follow-ups. The symptoms included seizures, gait disturbances, and severely increased intracranial pressure. The screening of the patient for infectious, rheumatologic, endocrinologic, and inflammatory pathologies was normal. CSF pressure was elevated without any malignancy. Repeated cranial MRI revealed hydrocephalus and pituitary expansion. Leptomeningeal thickening and contrast enhancement were observed in spinal MRI. After a negative dural biopsy, the patient was diagnosed with a spinal leptomeningeal biopsy. The authors believed that the prevalence of this rare pediatric tumor, diagnosed with a leptomeningeal biopsy, is underestimated as it has an insidious course and signs of increased intracranial pressure in the absence of a definite solid mass.

Key words: Diffuse leptomeningeal glioneuronal tumor, Diffuse leptomeningeal involvement, CSF, Pseudotumor Cerebri.

Introduction

Diffuse leptomeningeal glioneuronal tumor (DLGT) is a new entity defined under rare central nervous system tumors (CNS) in the 2016 update of WHO classification of CNS tumors (1). It presents clinically with increased intracranial pressure (ICP) findings and leptomeningeal thickening associated with hydrocephalus in central nervous system imaging (1). Diagnostic difficulties arise due to nonspecific cerebrospinal fluid (CSF) and imaging findings (2).

The authors reported a case of DLGT that presented with increased intracranial pressure complaints with no significant features in the MRI.

Case Report

An 11-year-old female patient presented to clinic with complaints of headache, vomiting, and double vision that started ten days before. In neurological examination, bilateral papillary edema and optic disc swelling were found. Cranial MRI did not reveal any findings except for the expansion of the optic nerve sheath. CSF pressure was 22 cm H₂O, CSF protein was 189 mg/dl, and CSF glucose was 66 mg/dl. Testings of CSF for Herpes simplex virus, Lyme, Brucella, Epstein Barr virus, Mycoplasma, and Tuberculosis were all negative. CSF cytology was negative for malignancy.

In order to find the etiology of the increase in intracranial pressure, thyroid function tests, blood cholesterol, adrenocorticotropic hormone, cortisol, vitamin A, D, E, and B12 levels were analyzed and all were in normal range. Upon regression of clinical signs during follow-up, the patient was discharged from the hospital. The patient presented again with headache, vomiting, and double vision two weeks after discharge. Neurological examination revealed nuchal rigidity. In the eye examination, there was papilledema, and the visual acuity was 10/10 in the right eye and 2/10 in the left eye. ICP and protein levels were found to be elevated in the repeated lumbar puncture. Infectious markers were negative in the CSF. Cranial MRI revealed optic nerve sheath enlargement, infundibular thickening, and thickening of the occipital horn of the right lateral ventricle, which may be compatible with hypophysitis or infiltration. Spinal MRI revealed leptomeningeal enhancement in the form of nodules and nodular thickening in the lower thoracic and lumbar levels along with the enhancement of cauda equina fibers and nodular thickening. Chest X-ray and CSF angiotensin-converting enzyme levels were normal in terms of sarcoidosis. Possible endocrinologic antibodies and pituitary antibodies were negative. Sjögren, lupus, Wegener granulomatosis antibodies were negative for autoimmune hypophysitis. Alpha-fetoprotein, beta-hCG, and carcinoembryonic antigen could not be detected in CSF with the initial diagnosis of germinoma. The tests for Langerhans cell histiocytosis were negative. No malignant cytology was detected in flow cytometry analysis in repeated CSF samples. The FDG PET scintigraphy of the whole body was normal for possible malignancies. As the test results were normal, a total of 5 g of methylprednisolone (1 g/day) was given for 5 days with a maintenance dose of 2 mg/kg (oral), for the persistent clinical symptoms. The patient's symptoms

showed progression, and the patient developed symptoms of increased intracranial pressure and generalized tonic-clonic seizures. Cranial-spinal MRI showed a significant increase in hydrocephalus compared to the previous examination, with extensive leptomeningeal lesions and cranial dural thickening. In addition, newly developed nodular leptomeningeal enhancement, which was significant at the C5-C6 level, developed at the cervical, thoracic, and lumbar spine. Indication of progression was observed in a total of five MRI images of the patient (Figures 1-3). The patient was started on levetiracetam. Then, the ventriculoperitoneal shunt was inserted due to hydrocephalus. During the shunt procedure, the dural biopsy was performed. The dural biopsy yielded fibrous connective tissue with focal dystrophic calcification. The patient's clinical symptoms continued to progress and she developed gait disorder and encephalopathy. Biopsy specimens were taken from the nodular lesion in the meninges at the L5 level. During the surgery, a frozen biopsy was performed in the presence of a pathologist, and the tissue was delivered quickly. A high level of tumor development including glial and partially neuronal differentiation was observed. A high Ki-67 proliferation index that can be considered as an indication of high biological aggression was found. A diagnosis of DLGT was declared with these findings and the patient was transferred to the oncology department for treatment.

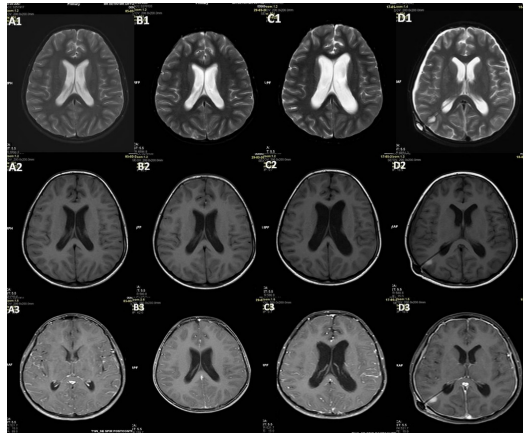


Figure 1. The patient's progressive progression on 4 MRI images at intervals of one month. T2-weighted axial, T1 weighted axial and contrast-enhanced T1-weighted axial MR images show progressive increase in ventricular dilatation. Catheter was placed for hydrocephalus (last column). Pericatheter bleeding and diffuse dural thickening were noted. (A=1ST Month; B=2ND Month; C=3RD Month; 1= T2-weighted axial; 2= T1 weighted axial; 3= Contrast-enhanced T1 weighted).

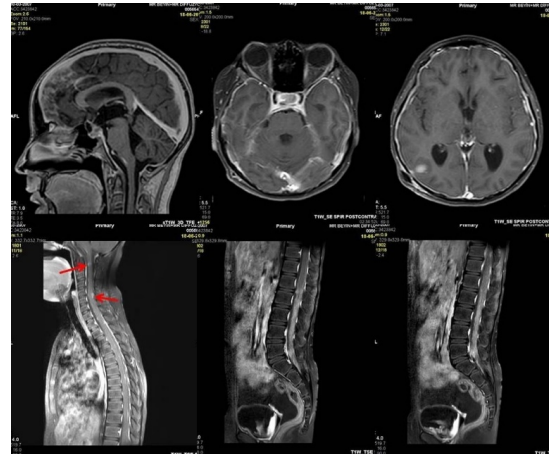


Figure 3. The patient's 5TH Month MRI finding; In addition to stalk thickening newly developed diffuse leptomeningeal thickening is noted on cranial MR imaging. Distal spinal canal lesions markedly increased in size and appear plaque-like masses and new lesions occur on cervical region (arrows).

Table I. Reported presenting symptoms

| Symptoms | Patients, n |
|-----------------------|-------------|
| Headache | 14 |
| Vomiting | 14 |
| Papilledema | 9 |
| Cranial nerve deficit | 7 |
| Meningismus | 8 |
| Cerebellar symptoms | 5 |
| Lethargy | 4 |
| Weight loss | 3 |
| Seizures | 3 |
| Depression | 1 |
| Vision loss | 1 |
| Abdominal pain | 1 |

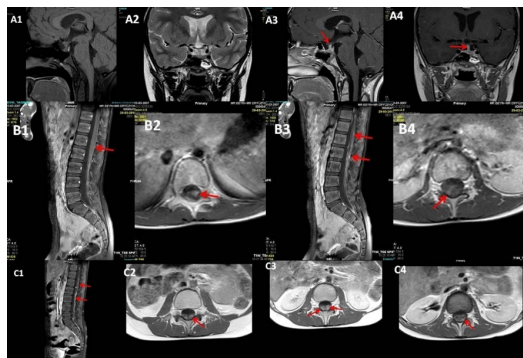


Figure 2. The patient's MRI images are shown hypophysial findings (hypophysitis) and nodular leptomeningeal contrast-enhancing lesions. A; Diffuse thickening of stalk is noted. A1, A2: T1 weighted sagittal, T2-weighted coronal, A3, A4: Contrast enhanced T1-weighted sagittal and coronal. B; Nodular leptomeningeal enhancing in spinal MRI lesions were noted on contrast-enhanced sagittal and axial images. C; Follow up spinal MR reveals that the leptomeningeal lesions are increased in size and appear more confluent. (A=1ST Month; B=2ND Month; C=3RD Month)

Discussion

The primary diffuse leptomeningeal primitive neuroectodermal tumor is an extremely rare tumor with the limited number of cases identified up today (3). It is frequently seen in children and adolescents (3). The Leptomeningeal spread usually occurs in the spinal cord with the absence of an intracranial lesion (1, 4). This makes the diagnosis of the tumor very difficult. In DLGT,

leptomeningeal thickening is typical in the radiological examination, which may lead to misdiagnosis or delay in diagnosis because of the resemblance to chronic inflammatory and infectious processes (1, 4). It usually resembles chronic inflammatory meningitis and presents with the clinical symptoms of obstructive hydrocephalus (3). In this case, however, there was no hydrocephalus at the beginning. The clinical symptoms of this case were more compatible with pseudotumor cerebri. The present case shows the importance of spinal MRI in a patient with the undetected underlying cause and clinical progression along with increased ICP, pseudotumor cerebri, or hydrocephalus.

The ages of 17 cases previously reported ranged from 1.5 to 17 years, and eight of them were males and nine were females (3-9). This situation indicated that the tumor develops predominantly in children with equal sex distribution. The most common presenting symptoms were headache and vomiting that were described in ten patients. Five patients had cerebellar symptoms (ataxia, dysarthria), three had double vision, four had weakness in the extremities, three patients had vision loss, two patients had changed state of consciousness, two patients had seizures with restlessness, whereas each of the urinary-fecal incontinence, abdominal pain, photophobia, back pain, and joint pain symptoms were reported in each patient. In physical examination, three patients had papilledema, three patients had bilateral sixth nerve paralysis, one patient had right hemiparesis, and one patient had cord compression findings. The initial symptoms were headache and elevated ICP, followed by the appearance of the other symptoms in parallel to the clinical stage of the cases. Clinical symptoms of this patient were similar to the cases described in the literature. Almost all cases reported had symptoms of elevated ICP.

As seen in this case, hydrocephalus, increased protein levels without malignant cells in CSF, and diffuse leptomeningeal involvement in MRI were observed in almost all cases reported in the literature (3-9). In this case, hydrocephalus was manifested late in the course of the disease. Intraventricular involvement, thalamic calcification, optic chiasm involvement, and dilatation of the sella turcica were the less common symptoms (6, 7). Instead of an intraparenchymal mass, intra parenchymal cysts have been identified in some of the reported cases (5-7). Leptomeningeal enhancement was observed in the initial stage of the disease, the occurrence and number of cystic changes in the brain parenchyma and leptomeninges occurred with the progression of the disease (6). However, intraparenchymal cyst was not detected in five of the nine cases described by Schniederjan et al (5). The reason of the absence of a cyst in this patient may be that the patient was in the initial stage of the disease. Although intraparenchymal cysts were strongly associated with this tumor, the fact that they did not occur in the early period led to diagnostic difficulties.

Mostly, cases with DLGT are diagnosed late in the course of the disease. The case described by Nambirajan et al. was diagnosed one year after the onset of disease, Karlowee et al.'s and Lyle et al.'s cases eleven months after the onset of disease, and Armao et al.'s case five years after the onset of disease with postmortem biopsy (6, 8-10). Another reason for the delayed diagnosis in this tumor is that the dural biopsy may be negative (6, 10). The dural biopsy performed in this case was also negative. This situation should be taken into account in the initial diagnostic period.

Isocitrate dehydrogenase 1 (IDH-1) is a cytoplasmic enzyme that produces nicotinamide adenine dinucleotide phosphate. The somatic mutations of the IDH1 gene have been shown to be

associated with various forms of cancer such as astrocytoma, oligodendroglioma, and hematopoietic dysplasias (6). IDH-1 is negative in DLGT and is used to differentiate it from other high grade glial tumors (6). Similar to the case of Schniederjan et al. and Lyle et al., IDH-1 was found negative in this case (5, 6). The deletion of 1p and 19q is used to evaluate the aggressiveness of the tumor and its response to chemotherapy, especially to temozolomide (6). These deletions may be positive in neurocytomas, adult oligodendrogliomas, and DLGT (8). These deletions showed that the disease would be more aggressive in extraventricular neurocytomas and were also used to evaluate the course of DLGT (8). The deletion of 1p and 19q showed that DLGT would have an aggressive course, but also showed an elevated likelihood of chemotherapy response. 1q deletion was also positive in this case similar to the cases reported by Schniederjan et al. and Gardiman et al. (5, 7).

In conclusion, DLGT should be considered in patients presenting with sudden headache, elevated ICP, papillary edema, and hydrocephalus in cranial imaging, or patients without hydrocephalus in the initial stage who develop hydrocephalus in the short-term. Elevated protein level without malignant cells in the CSF is an important clue in these cases. Cystic lesions without an intra-parenchymal mass in cranial MRI may help with diagnosis in the course of disease progression. Patients presenting with the above-mentioned clinical and laboratory symptoms with no definite underlying cause should undergo spinal MRI to determine the presence of leptomeningeal involvement. Leptomeningeal biopsy should be performed for diagnosis. The authors believed that the identification of only 20 cases of this tumor with an insidious course along with common clinic symptoms could be an underestimation.

Conflicts of Interest

There is no conflict of interest.

References

1. Preuss M, Christiansen H, Merkenschlager A, Hirsch FW, Kiess W, Müller W, et al. Disseminated oligodendroglial cell-like leptomeningeal tumors: preliminary diagnostic and therapeutic results for a novel tumor entity. *J Neurooncol* 2015;124(1):65–74.
2. Ko MW, Turkeltaub PE, Lee EB, Gonatas NK, Volpe NJ, Moster ML, et al. Primary diffuse leptomeningeal gliomatosis mimicking a chronic inflammatory meningitis. *J Neurol Sci* 2009; 278(1–2):127–131.
3. Sublett JM, Davenport C, Eisenbrock H, Dalal S, Jaffar Kazmi SA, Kershenovich A. Pediatric Primary Diffuse Leptomeningeal Primitive Neuroectodermal Tumor: A Case Report and Literature Review. *Pediatr Neurosurg* 2017;52(2):114–121.
4. Rodriguez FJ, Perry A, Rosenblum MK, Krawitz S, Cohen KJ, Lin D, et al. Disseminated oligodendroglial-like leptomeningeal tumor of childhood: A distinctive clinicopathologic entity. *Acta Neuropathol* 2012;124(5):627–641.
5. Schniederjan MJ, Alghamdi S, Castellano-sanchez A, Mazewski C, Brahma B, Brat DJ, et al. 9 Pediatric Cases With Chromosome 1p/19q Deletion Status and IDH1 (R132H) Immunohistochemistry. *Am J Surg Pathol* 2013; 37(5):763–771.
6. Lyle MR, Dolia JN, Fratkin J, Nichols TA, Herrington BL. Newly Identified Characteristics and Suggestions for Diagnosis and Treatment of Diffuse Leptomeningeal Glioneuronal/Neuroepithelial Tumors. *Child Neurol Open* 2015; 2(1):2329–2331.
7. Gardiman MP, Fassan M, Orvieto E, D'Avella D, Denaro L, Calderone M, et al. Diffuse leptomeningeal

- glioneuronal tumors: A new entity?
Brain Pathol 2010;20(2):361–366.
8. Nambirajan A, Suri V, Kedia S, Goyal K, Malgulwar PB, Khanna G, et al. Paediatric diffuse leptomeningeal tumor with glial and neuronal differentiation harbouring chromosome 1p/19q co-deletion and H3.3 K27M mutation: unusual molecular profile and its therapeutic implications. Brain Tumor Pathol 2018;35(3):186–191.
 9. Karlowee V, Kolakshyapati M, Amatya VJ, Takayasu T, Nosaka R, Sugiyama K, et al. Diffuse leptomeningeal glioneuronal tumor (DLGNT) mimicking Whipple's disease: a case report and literature review. Child's Nerv Syst 2017; 33(8):1411–1414.
 10. Armao DM, Stone J, Castillo M, Mitchell KM, Bouldin TW, Suzuki K. Diffuse leptomeningeal oligodendrogliomatosis: Radiologic/pathologic correlation. Am J Neuroradiol 2000; 21(6):1122–1126.