

Immune Thrombocytopenic Purpura: An uncommon manifestation of Hepatitis A with acute liver failure

Pranab Kumar Dey^{1*}, Eshita Das¹, Nairit De¹

1. Department of Paediatrics, R.G.Kar Medical College, Kolkata, India.

*Corresponding author: Dr. Pranab Kumar Dey, Associate Professor, Department of Pediatrics, R.G Kar Medical College, 1, Khudiram Bose Sarani, Shyambazar, Kolkata, Pin-700004. West Bengal, India. Email: drpranabdey@gmail.com. ORCID ID: 0000-0003-2356-7627

Received: 14 January 2022

Accepted: 14 February 2023

Abstract

Hepatitis A Virus (HAV) infection is a benign, self-limited gastrointestinal infection of children. Autoimmune hematological manifestation is very rare in children. Here, we report an 11-year-old male child having HAV infection with acute liver failure, complicated with persistent thrombocytopenia and haematuria during the course of illness and eventually diagnosed as a case of HAV infection associated with immune thrombocytopenic purpura. The child was treated successfully with a short course of steroid therapy.

Keywords: Immune Thrombocytopenic Purpura; Hepatitis A; Acute liver failure; Hematuria.

Introduction

Hepatitis A infection is the most common cause of hepatitis in children (1). It is a relatively benign disease, with the incidence of fulminant hepatitis being less than 0.1%. Almost 85% of infants and children are anicteric, unlike adults. Hepatitis A with atypical manifestations mainly reported in adults includes relapse, cholestasis, chronic autoimmune hepatitis, arthralgia, and rash. Infection with hepatitis B and C virus, parvovirus, and Epstein-Barr virus are occasionally associated with extra-hepatic autoimmune phenomena. But Extra-hepatic autoimmune phenomena like immune thrombocytopenic purpura (ITP), aplastic anemia, vasculitis, and haemophagocytic syndrome are extremely rare in a case of Hepatitis A Virus (HAV) infection (1-4). We reported a case of HAV infection with acute liver failure which is complicated as ITP, for its rarity in children.

Case Report

An 11-year-old previously well boy was admitted with a history of fever for 5 days, a blackish red purpuric spot over his face for the last 2 days, and 3-4 episodes of

painless frank haematuria in the last 1 day. There was a history of vomiting which is subsided on medication and the child had persistent dull aching pain in the epigastrium and right hypochondrium. There was no history of dysuria, loin pain, decreased urine output, rash, myalgia, arthralgia, drug intake, or history of jaundice in close contact. Initially, there was mild yellowish discoloration of the eyes which deepens during the course of the disease.

On examination, there was no lymphadenopathy, edema, rashes, or arthritis, only a few blackish-red purpuric spots over the face. The child had persistent bradycardia with good pulse volume. He had mild tenderness at the right hypochondrium and epigastrium with liver palpable 2.5 cm below the right costal margin.

Investigations revealed hemoglobin 13.4 g/dl, TLC 5400/c.mm (Neutrophil 49%, Lymphocyte 47%, Monocyte 1%, and Eosinophil 3%), Platelet count 25000/c.mm, and ESR 12mm/hr. Liver function test revealed total bilirubin 2.15 mg/dl (conjugated 1.75 mg/dl), aspartate aminotransferase (AST) 1920 (normal:15-45 IU/L) IU/L, alanine aminotransferase

(ALT) 1650 IU/L (normal: 5–45 U/L), alkaline phosphatase (ALP) 621(100-300 IU/L) IU/L, total serum protein 6.5 g/dl, serum albumin 3.7 g/dl. Prothrombin time 36.5 sec (control 13.2 sec), APTT 45.9 sec (control 33.5 sec), and INR 2.91. Serum electrolytes and renal function tests were normal except urine for routine examination revealed plenty of RBCs and mild proteinuria. Blood culture, peripheral smears for the malarial parasite, dengue immunoglobulin (Ig) M and IgG, Widal, leptospira IgM, scrub typhus IgM, and HIV were negative. Viral serologic studies were positive for anti-HAV IgM antibody and negative for anti-HAV IgG, IgM anti-hepatitis E antibody, hepatitis B and C, Epstein-Barr virus, cytomegalovirus, toxoplasma, rubella, and parvovirus B19. His autoimmune profile tests like ANA, ds DNA, LKM, SLA, and ASMA were negative. Abdominal sonography revealed an enlarged liver with a span of 15.5 cm and a thickened gall bladder wall with a partially contracted gall bladder and mild ascites. Electrocardiography and Echocardiography revealed normal study. He was gradually improved clinically by decreased jaundice as well as hematuria, and biochemically by decreased liver enzymes, improved coagulation profile, and thrombocytopenia by 2 weeks. He had a sudden worsened status by low platelet count with hematuria during discharge. For persistent thrombocytopenia, he underwent a bone marrow aspiration study which revealed normocellular marrow spaces with megakaryocytic hyperplasia and immature megakaryocytes suggestive of ITP as shown in Figure 1. However, Antiplatelet antibody couldn't be done. He was treated with oral prednisolone (2mg/kg/day) in divided doses for 7 days. His platelet count was gradually increased thereafter and his clinical and biochemical profile normalized after 4 weeks.

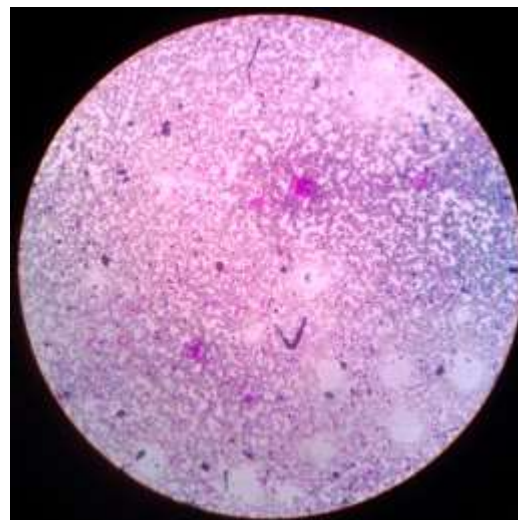


Figure 1. Hepatitis A with Immune thrombocytopenic purpura showing increased number of megakaryocytes (H&E 400X) in Bone marrow aspiration study.

Discussion

HAV infection is a benign self-limited infection of children. Autoimmune hematological manifestation is very rare in children (1-3). We reported an 11-year-old boy with acute HAV infection manifested as acute liver failure with thrombocytopenia and haematuria. His clinical course was complicated by persistent severe thrombocytopenia for which a bone marrow study was done and it was suggestive of ITP. The baby was then treated successfully with a short course of oral steroids. HAV infection is the most common form of viral hepatitis in childhood. It is caused by Type 72 enterovirus, which was named Hepatitis A by Mac Callum in 1947. It is mostly in benign nature. According to the literature, atypical manifestation of HAV infection includes cholestatic hepatitis, relapsing hepatitis, thrombocytopenic purpura, autoimmune diseases, acute renal failure, fulminant hepatic failure, etc. Among them, ITP manifestation is very rare in HAV infection. Very few cases of HAV with ITP have been reported in the literature (1-3,5).

However massive -haematuria, mild proteinuria, and acute liver failure as a manifestation of HAV infection are not reported. In multisystem involvement and renal predominant manifestation, we did work up for autoimmune disease and glomerulonephritis, which was negative. According to some pediatric reports, the thrombocytopenia may be due to bone marrow depression, disseminated intravascular coagulation as a result of increased platelet consumption, immune-mediated peripheral destruction of platelets in the reticuloendothelial system, or virus-associated haemophagocytic syndrome (VASH) or hypersplenism (3-4,6). Immune thrombocytopenia occurring during the course of HAV infection may be due to the presence of transient anticardiolipin antibody (ACL) or antiphospholipid antibody (APLA) or antiplatelet antibodies or non-specific deposition of immune complexes at platelet surface (7-14). In this case, there is no evidence suggestive of haemophagocytosis hypersplenism or bone marrow suppression. However, increased megakaryocytes in bone marrow study along with marked improvement in platelet count after a short course of steroid therapy suggested immune-mediated peripheral platelet destruction. Treatment of ITP even in the presence of a very low platelet count may not be required because the risk of serious bleeding is less and the outcome is favorable even without treatment (15). Currently, there is a trend towards conservative management of children with ITP (15). Most of the case reports of children with ITP due to HAV have been treated with IVIG with or without steroids and have shown good clinical and hematological responses. In the index case, steroid was preferred over IVIG due to financial reasons. There was no history of relapse and the child was symptom-free during follow-up.

Conclusion

Therefore, we concluded that ITP is a rare complication of HAV infection. Thrombocytopenia in a case of HAV infection is suggestive of a possible generalized immune dysregulation. In the differential diagnosis of jaundice with thrombocytopenia, HAV infection should be considered and a bone marrow study should be done to find out the etiology of thrombocytopenia. The Outcome of ITP due to HepA infection seems to be desirable.

Funding

None

Conflict of interest

The authors had no conflict of interest to declare.

References

1. Bansal A. Immune thrombocytopenia due to hepatitis A virus: Case report and review of literature. *J Pediatr Neonatal Care* 2015; 3(2):62–65.
2. Samanta T, Das AK, Ganguly S. Profile of hepatitis A infection with atypical manifestations in children. *Indian J Gastroenterol*. 2010; 9(1):31-33
3. Tanir G, Aydemir C, Tuygun N, Kaya O, Yarali N. Immune thrombocytopenic purpura as sole manifestation in a case of acute hepatitis A. *Turk J Gastroenterol* 2005;16(4):217-219.
4. Walia A, Thapa BR, Das R. Pancytopenia in a child associated with hepatitis A infection. *Trop Gastroenterol* 2006; 27:89-90.
5. S. Hosseinpour Sakha; R. Ghargharechi; R. Sarisoukhabi. "Immune Thrombocytopenia Associated with Hepatitis A Infection in Children". *Iranian J Med Sci* 2015: 148-149.

6. Labarque V, Van Geet C. Clinical practice: immune thrombocytopenia in paediatrics. *Eur J Pediatr* 2014; 173(2):163-172.
7. Grainger JD, Rees JL, Reeves M, Bolton-Maggs PH. Changing trends in the UK management of childhood ITP. *Arch Dis Child* 2012; 97(1):8-10
8. Leblebısatan G, Tümgör G, Saşmaz I, Ozgür O, Antmen B. Hepatitis A-associated immune thrombocytopenia. *Turk J Gastroenterol* 2012; 23(2):19519–19523.
9. Kumar S, Khadwal A, Verma S, Singhi SC. Immune thrombocytopenic purpura due to mixed viral infections. *Indian J Pediatr* 2013; 80(5):421–422.
10. Prabha R, Tripathi A, Singh A, Bhat NK. Immune Thrombocytopenic Purpura secondary to Hepatitis A infection in a 15 years old girl. *West Indian Med J* 2014; 63(5): 536–538.
11. Gultekingil A, Yarc E, Unal S, Kara A. Immune thrombocytopenic purpura during the course of acute hepatitis A virus infection. *Infect Dis Clin Prac* 2009; 17:331–332.
12. Yildirim ZK, Buyukavcı M. Thrombocytopenia with findings of acute hepatitis A infection: case report. *J Pediatr Inf* 2011;5: 80–82.
13. Jose W, Kumar K, Unnikrishnan A, Palaniappan M, Nair A. Autoimmune thrombocytopenic purpura in acute hepatitis A - areport and review of literature. *Asia Pac J Oncol Hematol* 2010; 2-5.
14. Stasi R, Chia LW, Kalkur P, Lowe R, Shannon MS. Pathobiology and treatment of hepatitis virus-related thrombocytopenia. *Mediterr J Hematol Infect Dis* 2009; 1-9.
15. Neunert C, Terrell D.R, Arnold, D G, Buchanan, D.B, Cines N. Cooper, et al. American Society of Hematology 2019 guidelines for immune thrombocytopenia. *Blood Adv* 2019; 3 (23):3829-3866.