

Hematopoietic Stem Cell Transplantation and Immune System Suppression in Severe Aplastic Anemia

Hassan Mahmoodi-Nesheli MD^{1*}, Ahmad Tamaddon MD², Somayeh Shirkosh PhD Candidate³, Mohtaram Hashemikaroyee BSc⁴, Khadije Jafarzadeh BSc⁵

1. Associate Professor, Non-Communicable Pediatric Diseases Research Center, Health Research Institute, Babol University of Medical Sciences, Babol, I.R.Iran

2. Professor, Clinical Research Development Unit of Amirkola Children's Hospital, Babol University of Medical Sciences, Babol, IR Iran

3. PhD Candidate in Nursing, Non-Communicable Pediatric Diseases Research Center, Health Research Institute, Babol University of Medical Sciences, Babol, I.R.Iran

4. BSc of Nursing, Clinical Research Development Unit of Amirkola Children's Hospital, Babol University of Medical Sciences, Babol, IR Iran

5. BSc of Nursing, Clinical Research Development Unit of Amirkola Children's Hospital, Babol University of Medical Sciences, Babol, IR Iran

*Corresponding author: Dr Hassan Mahmoodi Nesheli, Non-Communicable Pediatric Diseases Research Center, No 19, Amirkola Children's Hospital, Amirkola, Babol, Mazandaran Province, P. O. Box: 47317-41151, I. R. Iran. Email: mahmoodi86@yahoo.com. ORCID ID: 0000-0002-5851-7323.

Received: 13 July 2024

Accepted: 20 January 2025

Abstract

Aplastic anemia (AA) is characterized by pancytopenia and hypocellular bone marrow and can be either acquired or constitutional. Acquired AA results from autoimmune-mediated destruction of hematopoietic stem cells, often triggered by toxic agents inducing neo or cryptic antigens that activate immune responses. Although rare, acquired AA remains a serious condition typically managed with immunosuppressive therapy and supportive care. Constitutional forms, such as Fanconi anemia (FA) and Dyskeratosis Congenita (DC), are also uncommon and associated with genetic defects in DNA repair or telomere maintenance. Accurate differentiation between acquired and constitutional AA is critical for effective management.

In our center, 15 patients were diagnosed with AA between 2016 and 2021 (acquired = 5, constitutional = 10). Patients with acquired AA received immunosuppressive therapy. Those with constitutional AA and HLA-matched donors underwent bone marrow transplantation following a conditioning regimen of busulfan, cyclophosphamide, and rabbit ATG. Cyclosporine was initiated two days prior to transplantation and continued for 6–12 months or longer. Despite the high mortality risk associated with untreated AA, all patients achieved favorable outcomes with no mortality, underscoring the critical role of early diagnosis and individualized treatment in improving survival in AA.

Keywords: Aplastic Anemia, Bone Marrow Transplantation, Bone Marrow Failure Disorders, Dyskeratosis Congenital, Fanconi Anemia

Introduction

Aplastic anemia (AA) is characterized by pancytopenia and hypocellular bone marrow without features of marrow fibrosis or abnormal cells (1). AA is acquired or constitutional. Bone marrow biopsy is very helpful in the diagnosis of AA (2). Acquired aplastic anemia is an uncommon condition characterized by bone marrow failure that results from the autoimmune destruction of early hematopoietic stem cells (HSCs) and their progenitors (3).

Recent advances in genomic sequencing have enhanced comprehension of the mechanisms behind aplastic anemia, particularly regarding inflammation, somatic mutations, cytogenetic abnormalities, and the impaired telomerase functions of HSCs (1, 4). Toxic agents can trigger immune responses that lead to stem cell apoptosis (5). Treatment for acquired AA includes bone marrow transplantation, immunosuppressive therapy, and supportive care (6). Constitutional Aplastic

Anemia is also rare, with Fanconi anemia (FA) being the most common type. FA is a DNA repair disorder that leads to bone marrow failure. (7, 8). Dyskeratosis congenita (DC) is another inherited syndrome that leads to bone marrow failure, clinically identified by a triad of irregular nails, reticular pigmentation in the skin, and oral leukoplakia. It is characterized by unusually short telomeres and mutations in genes related to telomere biology. The range of disorders associated with telomere biology is expanding, and the clinical treatment of these patients is complicated (9). An accurate diagnosis of DC is essential for proper clinical management, as patients with DC accompanied by bone marrow failure do not respond well to immunosuppressive treatments and may face higher risks of morbidity and mortality connected to bone marrow transplantation (10). In Severe Aplastic Anemia (SAA), when treated with only supportive care such as transfusions and antibiotics, 28% of patients survive for two years post-diagnosis (11). Without definitive therapy, over 50% of patients may die within six months. Treatment options include antithymocyte globulin, cyclosporine, prednisolone, and granulocyte colony-stimulating factor (12). For constitutional SAA, allogeneic stem cell transplantation from an HLA-matched related donor is the primary treatment (13) with conditioning regimens including cyclophosphamide, busulfan, and antithymocyte globulin. Cyclosporine (CYA) was administered starting two days before BMT and continued for 6-12 months or longer. Transplantation from a related donor can be considered a second-line treatment for acquired SAA in patients who haven't responded to immunosuppressive therapy (12, 14).

Case Report

In our center, 15 cases were recruited as aplastic anemia in 2016- 2021. Ten patients had constitutional aplastic anemia;

(Fanconi anemia=9, Dyskeratosis Congenita=1). The presence of major or minor anomalies, frequent chromosomal aberrations, chromosomal fragility, and consistent elevations of fetal hemoglobin levels were of great value in diagnosing these patients. The patient was referred due to pallor, easy fatigability, weakness, and loss of appetite. Microcephaly, partially dark skin, and hyperpigmentation were prominent (Figure 1). The diepoxy butane test (DEB Test) was positive in 8 cases of Fanconi anemia but was negative in one case (Figure 2). Bone marrow aspiration and biopsy revealed marked depression of hematopoietic cells and replacement with fatty tissue (Figure 3). Nobody had hepatosplenomegaly or splenomegaly. Five patients with severe constitutional aplastic anemia (SAA) who had HLA-matched donors underwent bone marrow transplants (BMT). The range of age was 7-13.5 years (mean 9.87 years, 4 male and 1 female). They were transplanted between 2016 and 2021. Donors were: Father, Uncle, Mother, and Sister. These cases of severe constitutional aplastic anemia and cytopenia were Fanconi's cytopenia (four cases) and Dyskeratosis Congenita (one case). Conditional regimens for transplantation were busulfan, cyclophosphamide, and rabbit type of ATG for all patients. A low dose of busulfan (0/2 mg/kg/dose in 12 doses), and cyclophosphamide (15 mg/kg/dose in 4 days) were administered. Rabbit-type ATG was administered at 2.5 mg/kg/day for 2 continuous days. We use cyclosporine (CSA) and low-dose prednisolone for prophylaxis of graft-versus-host disease (GVHD). They were effective. More than three years after transplantation, all patients are alive and active. DC suffered from osteoporosis due to steroids. Five cases of Fanconi anemia that didn't have HLA-matched donors were treated with steroids, and therapy appeared to induce partial hematological remission, but the ultimate prognosis for the disorder appears grave.

Two patients are alive, but three patients died. Two patients died due to infection and the other died due to T-cell acute Lymphoblastic Leukemia. Five patients were diagnosed with acquired aplastic anemia (aged 4.5-13 years, mean=9.16 years, M=3, F=2). Three patients were idiopathic. They are treated with anti-thymocyte globulin, cyclosporine, and steroids. One patient received horse-type ATG and two patients received rabbit-type ATG. Cyclosporine and steroids continued to complete the recovery reached. One patient who received horse-type ATG reached recovery sooner than two others who received rabbit-type ATG. (12 months,

vs. 18 months and 36 months). Three patients were diagnosed with acquired aplastic anemia as post-COVID-19 infection. Two patients who received rabbit-type ATG, cyclosporine, and steroids, didn't have recovery 27 months and 30 months after treatment. One patient who received horse-type ATG, cyclosporine, and steroid combination therapy reached recovery 12 months later. Fortunately, all patients for whom interventional treatment was done either transplantation or immunomodulatory treatment are alive and active (100% of patients).

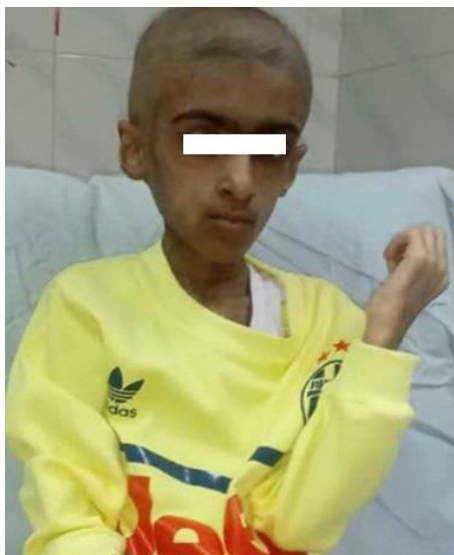

Figure 1. The patient was referred due to pallor, easy fatigability, weakness, and loss of appetite. Microcephaly, partially dark skin, and hyperpigmentation were prominent.

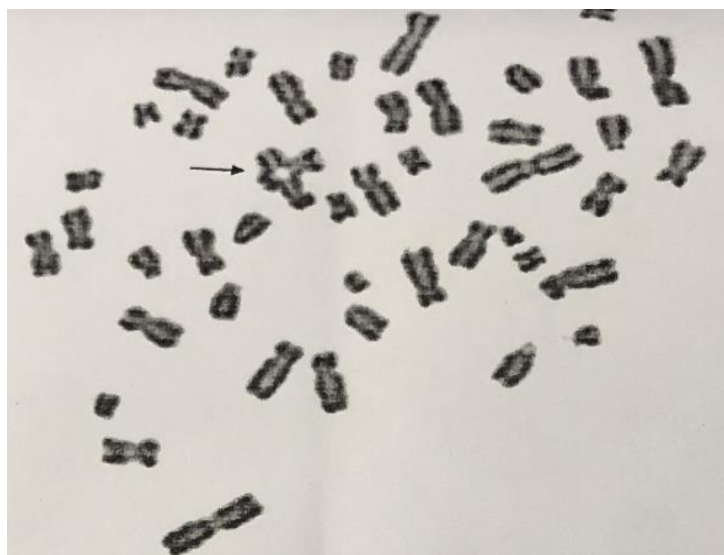


Figure 2. Positive diepoxy butane test (DEB Test) in cases of Fanconi anemia

A total of the twenty metaphase spreads were analyzed from routine culture, along with 150 spreads from cultures prepared with two concentrations of mitomycin C and these were compared to 100 spreads from normal age-matched controls. 33 breaks and 3 radial rearrangements were identified in 30 cells, resulting in an average of 0.30 breaks per metaphase while no breaks were observed in the normal control. From a cytogenetic perspective, breakage equal to or greater than 10 times the control level is deemed clinically significant. Analysis at a resolution of 450-500 bands showed no resolution and no chromosomal abnormalities.

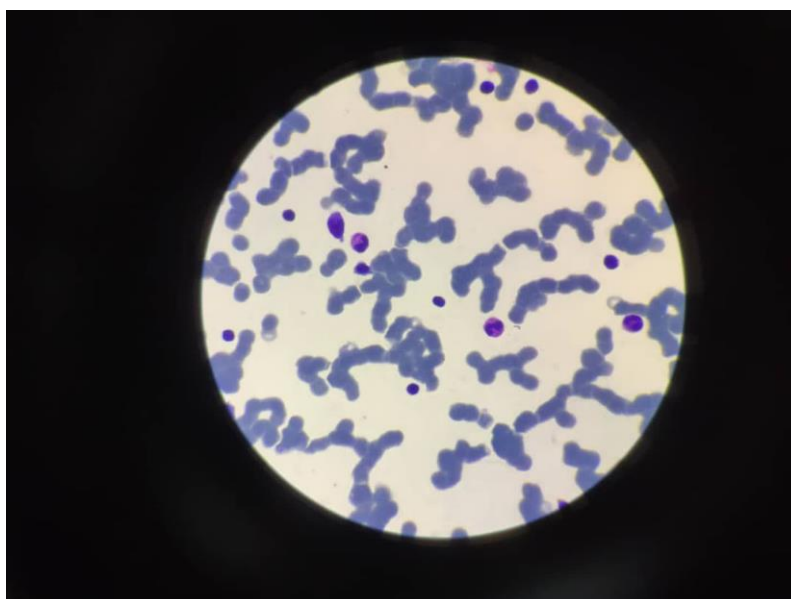


Figure 3. Bone marrow aspiration and biopsy revealed marked depression of hematopoietic cells and replacement with fatty tissue

Discussion

Prompt detection and treatment of aplastic anemia are crucial. It is also essential to perform a differential diagnosis of aplastic anemia, as varying types require different treatment approaches. In cases of constitutional aplastic anemia, bone marrow transplantation is the preferred treatment option, whereas in acquired aplastic anemia, bone marrow transplantation is considered if immunosuppressive therapy is unsuccessful. Although without treatment, the fate of aplastic anemia is grave, meticulous care is needed to achieve a successful outcome. In our study, all patients who underwent BMT received rabbit-type ATG. It seems horse-type ATG is more effective in constitutional aplastic anemia. Although the age of the donor and recipient may impact failure-free survival, the conditioning regimen is also an effective factor for overall survival. Post-transplantation care is very important. In our study patients who underwent BMT were visited and monitored every week. Our idea is that the survival of our patient is due to short periodic follow-ups.

Conclusion

Although mortality is very high in each type of aplastic anemia without treatment, all patients in our center with treatment are alive. Early diagnosis and correct treatment are crucial.

Ethical Considerations

This study obtained ethics committee approval (Ethical code: (IR.MUBABOL.REC.1401.173).

Acknowledgments

We appreciate the support and collaboration of the Clinical Research Development Unit at Amirkola Children's Hospital for this study.

AI Assistance Disclosure

Artificial intelligence tools (ChatGPT/GPT-4.1) were used solely to enhance the clarity of the English text of the article

Author's Contributions

Dr Hassan Mahmoodi-Nesheli- Case identification, clinical workup, analyzing data, and drafting the manuscript.

Prof. Ahmad Tamaddon- Case identification, clinical workup, and critical revision of the manuscript.

Somayeh Shirkosh- Data collection, data analysis, and drafting the manuscript.

Mohtaram Hashemikaroyee and Khadije Jafarzadeh- Data collection and manuscript preparation.

Funding

None

Conflict of Interest

There were no conflicts of interest.

References

1. DeZern AE, Churpek JE. Approach to the diagnosis of aplastic anemia. *Blood Adv* 2021; 5(12): 2660-2671.
2. Young NS. Aplastic anemia. *N Engl J Med* 2018; 379(17): 1643-1656.
3. Brzeźniakiewicz-Janus K, Rupa-Matysek J, Gil L. Acquired aplastic anemia as a clonal disorder of hematopoietic stem cells. *Stem Cell Rev Rep* 2020; 16(3): 472-481.
4. Solimando AG, Palumbo C, Pragnell MV, Bittrich M, Argentiero A, Krebs M. Aplastic anemia as a roadmap for bone marrow failure: An overview and a clinical workflow. *Int J Mol Sci* 2022; 23(19): 11765-11767.
5. Hartung HD, Olson TS, Bessler M. Acquired aplastic anemia in children.

Pediatr Clin North Am 2013; 60(6): 1311-1336.

6. Zhang Y, Huo J, Liu L, Shen Y, Chen J, Zhang T, et al. Comparison of hematopoietic stem cell transplantation outcomes using matched sibling donors, haploidentical donors, and immunosuppressive therapy for patients with acquired aplastic anemia. *Front Immunol* 2022; 13: 837335.

7. Siegner SM, Ugalde L, Clemens A, Garcia-Garcia L, Bueren JA, Rio P, et al. Adenine base editing efficiently restores the function of Fanconi anemia hematopoietic stem and progenitor cells. *Nat Commun* 2022; 13(1): 6900.

8. Silva de Araujo BE, Velleuer E, Dietrich R, Pomjanski N, de Santana Almeida Araujo IK, Schlenz M, et al. Detection of cytogenetic changes and chromosomal aneuploidy with fluorescent in situ hybridization in cytological specimens of oral cancers in Fanconi anemia-Proof of concept. *Clin Exp Dent Res* 2022; 8(1): 108-116.

9. Fiesco-Roa M, García-de Teresa B, Leal-Anaya P, van 't Hek R, Wegman-Ostrosky T, Frías S, et al. Fanconi anemia and dyskeratosis congenita/telomere biology disorders: Two inherited bone marrow failure syndromes with genomic instability. *Front Oncol* 2022; 12: 949435.

10. Passweg JR, Tichelli A. Immunosuppressive treatment for aplastic anemia: are we hitting the ceiling? Abstract book for the 27th congress of the european hematology association. *Haematologica* 2009; 94(3): 310-312.

11. Peslak SA, Olson T, Babushok DV. Diagnosis and treatment of aplastic anemia. *Curr Treat Options Oncol* 2017; 18(12): 70.

12. Park CW, Han CH, Kim CC, Kim DJ, Kim HK. Immunomodulation therapy for severe aplastic anemia: ALG versus ALG plus cyclosporin a. *Korean J Intern Med* 1989; 4(1): 28-33.

13. Liu L, Zhao X, Miao M, Zhang Y, Jiao W, Lei M, et al. Inefficacy of immunosuppressive therapy for severe

aplastic anemia progressing from non-SAA: Improved outcome after allogeneic hematopoietic stem cell transplantation. *Front Oncol* 2021; 11: 739561.

14. Georges GE, Storb R. Hematopoietic stem cell transplantation for acquired aplastic anemia. *Curr Opin Hematol* 2016; 23(6): 495-500.