

Association between serum ferritin level, cardiac and hepatic T2-star MRI in patients with major β -thalassemia

Eghbali A MD¹, Taherahmadi H MD², Shahbazi M MD³, Bagheri B PhD⁴, Ebrahimi L MSc⁵

1. Pediatric Hematologist & Oncologist, Department of Pediatrics, Arak University of Medical Sciences, Arak- Iran

2. Department of Pediatrics, Arak University of Medical Sciences, Arak- Iran

3. Student of Medicine, Arak University of Medical Sciences, Arak- Iran

4. Pharmacologist, Department of pharmacology, Semnan University of Medical Sciences, Semnan-Iran

5. Blood transfusion research center, High Institute for Research and Education in Transfusion Medicine, Tehran-Iran

Received: 29 December 2013

Accepted: 5 March 2014

Abstract

Background

Frequent blood transfusion is often associated with iron overload. Proper use of iron chelators to treat iron overload requires an accurate measurement of iron levels. Magnetic resonance T2-star (T2* MRI) can measure iron level in the heart and liver. Our goal was to see whether an association exists between serum ferritin level and T2* MRI in patients with major beta thalassemia.

Materials and Methods

Sixty patients with a diagnosis of major beta thalassemia were enrolled in the study. They were older than five years old and needed regular transfusion.

Cardiac and hepatic T2*MRI and mean serum ferritin levels were measured within 3 months.

Results

No significant correlation was observed between serum ferritin level and cardiac T2*MRI ($p=0.361$, $r=-0.120$). However, a significant correlation was observed between serum ferritin and liver T2*MRI ($p=0.021$, $r=-0.297$).

Conclusion

Our results showed an association between hepatic T2*MRI and serum ferritin level.

Keywords

Ferritin; Iron chelator; Major thalassemia; T2*MRI

Corresponding Author:

Eghbali A MD, Pediatric Hematologist & Oncologist, Department of Pediatrics, Arak University of Medical Sciences, Arak, Iran. Email: aziz_eghbali@yahoo.com.

Introduction

Thalassemia is the most common genetic disorder in the world (1). Frequent blood transfusion as a part of major thalassemia treatment is often linked to iron overload that can be deposited in many organs especially in the heart and liver. Heart failure secondary to iron overload is the main cause of death in patients with major thalassemia. When heart failure develops, the prognosis is usually poor. Heart failure estimated as 70% cause of mortality in major thalassemia. Iron chelators are routinely used to treat iron overload. For correct use of these drugs, an accurate measurement of iron levels is necessary. Several methods are applied to measure iron levels. Measurement of serum ferritin is relatively a reliable test but is not valuable in the liver involvement and elderly; moreover, infections and hepatic diseases can cause false increase in the level of serum ferritin. The most accurate method to measure iron level is liver

biopsy; however, it is invasive and unable to provide an accurate measurement of heart iron level (2,3). During recent years, non-invasive methods have gained prominence. Magnetic resonance T2-star (T2* MRI) is a method for assessment of high molecular weight iron complexes induced T2 relaxation enhancement like ferritin and hemosiderin. (4-16). T2* MRI can measure iron levels in the heart and liver and is helpful for early diagnosis of the myocardial hemosiderosis before the initiation of clinical manifestations. The present study was designed to find association between serum ferritin and T2* MRI of the heart and liver in patients with major thalassemia.

Materials and Methods

This was a cross-sectional descriptive study during 2011 to 2012. A total of 60 patients with a diagnosis of major beta thalassemia admitted to Amir Kabir

Hospital, Arak, Iran, were enrolled in the investigation. They were older than five years old and required regular transfusion. Demographic data, mean level of serum ferritin during last 3 months and T2*MRI results were recorded in a questionnaire. The sampling was performed on the basis of simple random method. The exclusion criteria were as follows: Patients younger than 5 years old, advanced hepatic and cardiac disease and patients with hepatitis B or C. The ethical board of the university approved the study and informed consent letter was taken from participants.

T2*MRI

MRI was performed by Magneto Symphony Graniand 32, 1.5 Tesla (Siemens, Germany, 2003) in Noor Clinic (Tehran, Iran). Each scan lasted about 30 minutes and included the measurement of hepatic and cardiac T2*. Cut off points in this MRI instrument are as follows: Liver: normal > 6.3ms, mild: 2.8-6.3ms, moderate: 1.4-2.7ms, severe <1.4ms. Cardiac: normal >20ms, mild: 14-20ms, moderate: 10-14ms, severe <10ms.

Measurement of serum levels of ferritin

Serum ferritin level was measured by ELISA (Awareness technology, US). The findings of MRI and serum ferritin were assessed contemporarily. Then mean of serum ferritin level was recorded during last 3 months. It was measured in patients who

showed no evidence of bacterial or viral infection.

Statistical analysis

Data are presented as mean±SD. Then mean of serum ferritin level was recorded during last 3 months. Linear regression and other descriptive statistic tests were used. Statistical significance was considered as $p<0.05$. All of analyses were performed using SPSS software version 16.

Results

The study was performed on 60 patients with major beta thalassemia (55% male and 45% female). The mean of age of patients was 17.65 ± 9.28 years and its range was 5 to 50. Hemoglobin values ranged from 6.7 to 11.5 (mg/dl) before transfusion. Mean level of hemoglobin was 9.1 (mg/dl) before transfusion. Mean age of transfusion was 1.1 ± 0.8 . The mean of serum ferritin level was 1927.1 ng /dl (103.2-11300 ng /dl). The mean of cardiac T2* was 26.46 ± 9.19 ms (8.36-45.8) and the mean of hepatic T2* was 5.30 ± 4.29 ms (0.95-19.72). . Four patients underwent splenectomy. Hepatic T2*MRI is presented in Table 1 and Graph1 and Cardiac T2*MRI is shown in Table 2 and Graph 2. A significant correlation was observed between serum ferritin and liver T2*MRI ($p=0.021$, $r=-0.297$). No significant correlation was seen between age and rate of blood transfusion and also between serum ferritin and cardiac T2*MRI ($p=0.361$, $r=-0.120$)

Table 1: Relationship between Serum levels of ferritin and hepatic T2*MRI

Number of patients	Age (year)	Serum Ferritin	Hepatic T2*MRI
14 (23.3%)	14.35 ± 7.27	1260 ± 235	normal>6.3ms
28 (46.7%)	18.25 ± 9.47	1655 ± 388	mild6.3-2.8 ms
15 (25%)	17.53 ± 7.32	2338 ± 449	Moderate2.8-1.4ms
3 (5%)	28 ± 19.15	5510 ± 1555	severe<1.4ms

Data are presented as mean ± SD or number (%).

Table II: Serum levels of ferritin and cardiac T2*MRI

Number of patients	Age (year)	Serum ferritin	Cardiac T2*MRI
46 (76.7%)	19.5 ±9.5	1913 ±305	Normal>20ms
9 (15%)	11.3 ±5	1987 ± 342	Mild14-20 ms
3 (5%)	8.6 ±2.5	666 ±100	moderate10-14ms
2 (3%)	17 ±7	3849 ±289	Severe<10ms

Data are presented as mean ± SD or number (%).

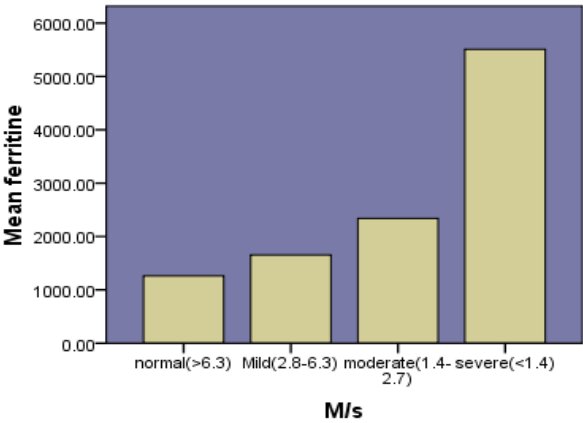


Figure 1. Serum levels of ferritin and hepatic T2*MRI

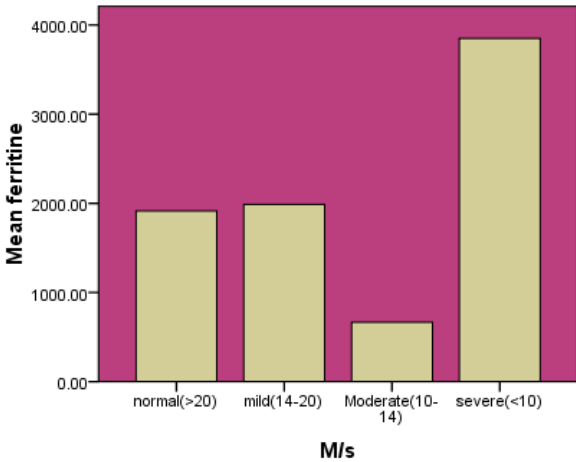


Figure 2. Serum levels of ferritin and cardiac T2*MRI

Discussion

There are several methods to measure iron levels in different organs. Liver disease and inflammatory responses can increase amount of serum ferritin, so its measurement is not very reliable. Liver biopsy is the gold standard method to measure iron level but it is invasive and cannot predict iron level of the heart. Echocardiography is another method, which is only reliable in advanced iron overloading. In the present study, T2*MRI was used for to measurement of iron levels in the heart and liver. It's found that cardiac T2*MRI is associated with the mean of age. Moreover, the result showed that younger patients had higher levels of hepatic T2*MRI. Shamsian's study showed that there was a direct association between cardiac T2*MRI and mean of age. However, two similar studies proved a reverse association between T2*MRI and mean of age (17). Surekha Tony and colleague could not show a significant association between cardiac T2*MRI and serum ferritin(18). In concert with these observations, Alberto et al demonstrated that measurement of serum ferritin did not have a prognostic value (19). In our study, correlation between age and cardiac T2*MRI was direct which can be caused by sensitivity of T2*MRI in detecting cardiac ironload. In study of shamsian and et al in mofid children's hospital in 2011, similar results were obtained but opposite results were seen in Perifanis study in 2007 (17). In our study correlation between age and hepatic T2*MRI was reverse. These results were matched with chirstoforidis study in Greece (20). This study reported that hepatic T2*MRI had strong correlation with serum ferritin and could be used to estimate iron levels of the body.

Zamani's study revealed no reasonable correlation between histological grade of siderosis (HGS) and serum ferritin. A moderate correlation was seen between serum ferritin levels and hepatic T2* levels. Iron concentration of the liver showed significant correlation with hepatic T2*. These results indicated that T2* MRI measurement is of more value than HGS in patients with thalassemia (21).

Conclusion

Our results showed an association between hepatic T2*MRI and serum ferritin. It is suggested to use this method in order to have an accurate measurement of iron level in patients with thalassemia. We can recommend hepatic and cardiac T2*MRI in addition to measurement of serum ferritin for better evaluation of patients with major thalassemia.

Conflict of interest

The authors have no conflict of interest.

References

1. Muncie HL Jr, Campbell J. Alpha and beta thalassemia. *Am Fam Physician*. Aug 15 2009; 80(4): 339-44.
2. Singer ST. Variable clinical phenotypes of alpha-thalassemia syndromes. *Scientific World Journal*. 2009;9:615-25.
3. Schrier SL. Thalassemia: pathophysiology of red cell changes. *Annu Rev Med*. 1994;45:211-8.
4. Galia M, Midiri M, Bartolotta V, Morabito A, Rizzo M, Mangiagli A, et al. Multicenter Trial Group of the Society for the Study of Thalassemia and Haemoglobinopathies. Potential myocardial iron content evaluation by magnetic resonance imaging in thalassemia major patients treated with Deferoxamine or Deferiprone during a randomized multicenter prospective clinical study. *Hemoglobin*. 2003 ;27(2):63-76.
5. Christoforidis A, Haritandi A, Tsatra I, Tsitourides I, Karyda S, Athanassiou-Metaxa M. Four-year evaluation of myocardial and liver iron assessed prospectively with serial MRI scans in young patients with beta-thalassaemia major: comparison between different chelation regimens. *Eur J Haematol*. 2007;78(1):52-7. Epub 2006;28.
6. Tanner MA, Galanello R, Dessi C, Smith GC, Westwood MA, Agus A, et al. A randomized, placebo-controlled, double-blind trial of the effect of combined therapy with deferoxamine and deferiprone on myocardial iron in thalassemia major using cardiovascular magnetic resonance. *Circulation*. 2007;115(14):1876-84. Epub 2007.
7. Deborah Chirnomas S, Geukes-Foppen M, Barry K, Braunstein J, Kalish LA, Neufeld EJ, et al. Practical implications of liver and heart iron load assessment by T2*-MRI in children and adults with transfusion-dependent anemias. *Am J Hematol*. 2008;83(10):781-3.
8. Hankins JS, McCarville MB, Loeffler RB, et al. R2* magnetic resonance imaging of the liver in patients with iron overload. *Blood*. 2009;113(20):4853-5.
9. Christoforidis A, Haritandi A, Tsitouridis I, Tsatra I, Tsantali H, Karyda S, et al. Correlative study of iron accumulation in liver, myocardium, and pituitary assessed with MRI in young thalasemic patients. *J Pediatr Hematol Oncol*. 2006 ;28(5):311-5.
10. Mazza P, Giua R, De Marco S, Bonetti MG, Amurri B, Masi C, Lazzari G, Rizzo C, Cervellera M, Peluso A, et al. Iron overload in thalassemia: comparative analysis of magnetic resonance imaging, serum ferritin and iron content of the liver. *Haematologica*. 1995 ;80(5):398-404.
11. Argropoulou MI, Kiortsis DN, Efremidis SC .

MRI of the liver and the pituitary gland in patients with beta-thalassemia major: does hepatic siderosis predict pituitary iron deposition? *Eur Radiol*. 2003;13(1):12-6. Epub 2002.

12.Papakonstantinou O, Kostaridou S, Maris T, Gouliamos A, Premetis E, Kouloulis V, et al. Quantification of liver iron overload by T2 quantitative magnetic resonance imaging in thalassemia: impact of chronic hepatitis C on measurements. *J Pediatr Hematol Oncol*. 1999;21(2):142-8.

13.Rose C, Vandevenne P, Bourgeois E, Cambier N, Ernst O. Liver iron content assessment by routine and simple magnetic resonance imaging procedure in highly transfused patients. *Eur J Haematol*. 2006;77(2):145-9. Epub 2006.

14.Maris TG, Papakonstantinou O, Chatzimanoli V, Papadakis A, Pagonidis K, Papanikolaou N, et al. Myocardial and liver iron status using a fast T*2 quantitative MRI (T*2qMRI) technique. *Magn Reson Med*. 2007;57(4):742-53.

15.Di Renzi P, Cianciulli P, Preziosi P, Amadori S, Orlacchio A. Iron accumulation in the liver of patients with thalassemia major assessed with low field strength magnetic resonance: correlation with clinico-instrumental parameters. *Radiol Med (Torino)*. 1996;91(6):764-8.

16. Marget C, Holowka S, Moineddin R, Odame I. Liver iron overload assessment by T magnetic resonance imaging in pediatric patients: An accuracy and reproducibility study. *American J Hematol*, 2012, 87:435-439.

17.Shamsian, Bibi Shahin, Abdar Esfahani, Shadi, Milani, Hani, Akhlaghpour, et al. Magnetic

resonance imaging in the evaluation of iron overload: a comparison of MRI, echocardiography and serum ferritin level in patients with β -thalassemia major, *clinical imaging*. 2012;36(5):483-8.

18.Surekha Tony, MD1*, Shahina Daar, MD2*, Mathew Zachariah, MD1*, Azza Hinai, MD1*, Idris Al-Jumah, MD1*, Salaam Alkindi, MBBCh, MSc, FRCP2* and Yasser Wali, MD, FRCPCH, (UK) 1EARLY Detection of Cardiac and Hepatic Iron Overload by T2* Magnetic Resonance in Very Young Patients with Thalassemia Major in Oman *WJG* December 1, 2010.

19.Alberto Fragasso, , Angela Ciancio, Clara Mannarella, Carlo Gaudiano, Oronzo Scarciolla, Carlo Ottonello, Marco Franconec, Michele Nardella, Angelo Pelusoe, Angela Melpignanof, Maria Rosaria Vegliog,, Myocardial iron overload assessed by magnetic resonance imaging (MRI) T2* in multi-transfused patients with thalassemia and acquired anemias, *European Journal of Internal Medicine* Volume 22, Issue 1, February 2011, Pages 62-65.

20.Christoforidis A, Haritandi A, Tsitouridis I, Tsatra I, Tsantali H, Karyda S, et al. Correlative study of iron accumulation in liver, myocardium, and pituitary assessed with MRI in young thalassemic patients. *J Pediatr Hematol Oncol*, 2006, 28(5):311-15.

21.Farhad Zamani, Sara Razmjou, Shahram Akhlaghpour, Seyyedeh-Masoom Eslami, Azita Azarkeivan, and Afsaneh Amiri T2* magnetic resonance imaging of the liver in thalassemic patients in Iran., *World J Gastroenterol*. 2011; 17(4): 522-5.