Original Article *Iran J Ped Hematol Oncol. 2016, Vol6.No2, 100-105*

The frequency of PAX3 and PAX7 Mutations in Children with Rhabdomyosarcoma

Farzaneh Jadali MD [1], Kourosh Goudarzi Pour MD [2], Roxana Aghakhani MD [3], Maliheh Khoddami MD [4], Mehran Arab Ahmadi MD [5], Behdad Behnam MD [6,*]

1. Pediatric Infectious Research Center, Shahid Beheshti University of Medical Sciences, Tehran, Iran
2. Pediatric congenital hematologic disorders research center, Shahid Beheshti University of Medical Sciences, Tehran, Iran
3. Pediatric Pathology research center of Mofid children's hospital, Shahid Beheshti University of Medical Sciences, Tehran, Iran
4. Pediatric Pathology research center of Mofid children's hospital, Shahid Beheshti University of Medical Sciences, Tehran, Iran
5. Functional Neurosurgery Research Center, Shahid Beheshti University of Medical Sciences, Tehran, Iran
6. Functional Neurosurgery Research Center, Shahid Beheshti University of Medical Sciences, Tehran, Iran

*Corresponding author: Behdad Behnam, Functional Neurosurgery Research Center, Shohada Tajrish Hospital, Tajrish Square, Tehran, Iran. E-mail: behdadbehnam10@yahoo.com

Received: 11 November 2015 **Accepted:** 20 March 2016

Abstract

Background: Rhabdomyosarcoma is the most common soft tissue sarcoma among children which has two major subtypes: embryonal rhabdomyosarcoma (ERMS) and alveolar rhabdomyosarcoma (ARMS). Distinction between these subtypes is mandatory to choose proper treatment and to determine prognosis. Histopathologic study is the main method, but nowadays molecular studies like PCR are also used. The aim of this study was to evaluate the frequency of PAX3 and PAX7 mutations in children with rhabdomyosarcoma.

Materials and Methods: In this cross- sectional survey, Paraffin blocks of 34 Rhabdomyosarcoma cases with mean age of 6.3 ± 2.9 years were studied in Mofid Children's Hospital's Pathology Department, Tehran, Iran, during a 10-year period. Tumoral lesions dissected and embedded in paraffin blocks for PCR study (Tissue dissection method). Pure RNA extraction, cDNA synthesis, and PCR process were performed according to iNtRON biotechnology company kits' protocols. All of these cases were analyzed regardingPAX3 and PAX7 mutations.

Results: Out of 34 cases, 32 were ERMS and two were ARMS. None of the ERMS samples was t (2; 13) or t (1; 13) positive. Moreover, two ARMS cases were negative for PAX3 and PAX7 mutations. No significant difference was seen for age below and above five years (P= 0.69) as well as for tumor location (trunk tumor and limbs/head tumor) (P= 0.11).

Conclusions: This study revealed lack of PAX3 and/or PAX7 mutations in both ERMS and ARMS. However, careful morphological evaluation cannot be replaced by the PCR-based t(2;13) and t(1;13) assay of childhood sarcomas, it can be used to make certain current histopathological diagnosis.

Key words: Children, Histopathology, PAX-3, PAX-7, Rhabdomyosarcoma

Introduction

The most common childhood soft tissue malignancy is rhabdomyosarcoma (RMS), accounting for 4% to 8% of all pediatric cancers (1). Pediatric RMS has two major subtypes including embryonal and alveolar (2, 3). The alveolar rhabdomyosarcoma (ARMS) has a more aggressive clinical behavior and a worse prognosis than all embryonal variants like the botryoid and the spindle cell variants (4).

However histopathological overlaps between alveolar and embryonal, subtypes may exist; the solid form of ARMS is associated with a poor prognosis in the absence of a typical alveolar growth pattern (2, 4). Despite careful morphological examination, it may be sometimes difficult to establish a definite histopathological diagnosis in a given case of a poorly differentiated RMS in a child (5).

[Downloaded from ijpho.ssu.ac.ir on 2026-11-24]

Translocation between chromosome band 2q35 and chromosome band 13q14 has been found in ARMS (6).

This translocation is associated with a rearrangement of the PAX3 gene that encoding a paired-box transcription factor. The PAX3 gene is highly expressed in dermomyotomal muscle progenitor cells of the limb in mouse embryonic development (7, 8). The breakpoint of the t(2;13) is located within the final PAX3 intron and results in a chimeric fusion protein composed of an N-terminal PAX3 fragment and the C-terminal part of a novel member of the forkhead transcription regulator family (9). The structural integrity of the PAX3 paired DNA binding domain in the PAX3 forkhead fusion protein and the home domain is retained (10-12). The muscle cell-specific transcription of PAX3 is transferred to that of the chimera.

The tumor-specific PAX3 forkhead protein is a more potent transcriptional activator than the PAX3 protein (13). A gain-of-function mutation of PAX3 may therefore be involved in the etiology of ARMS. Indeed, over expression of the PAX3 gene in NIH3T3 cells reveals an oncogenic potential (14). This argument is further strengthened by the observation of a second, less frequent translocation involving another member of the PAX gene family in pediatric ARMS (15). This t (1; 13) (p36;q14) translocation rearranges PAX7 to generate a PAX7 forkhead fusion, analogous to the PAX3 forkhead.

This study aimed to evaluate the frequency of the t (2; 13) and t (1; 13) in pediatric RMS, including the alveolar and embryonal subtypes. The other aim of this study was to compare survival rate during 24 months of follow up based on age, gender, and location of tumor.

Materials and Methods

In this cross sectional study, according to Paraffin embedded formalin fixed tissue, 34 cases of pediatric RMS younger than 11 years, were diagnosed in Mofid children's hospital's pathology department (Tehran, Iran), during 2003 till 2013. The related blocks and slides were available in our archive include two cases of alveolar and 32 cases of embryonal.

Histopathological Evaluation

As archival material is the only available source, paraffin-embedded formalin-fixed tumor materials were examined. Non-tumor tissue was dissected and removed from block and pure tumoral tissue reblocked again using a hematoxylin and eosin stained slid as a template. Normal paraffin-embedded skeletal muscle was used as a negative control.

Histopathological tumor classification: Hematoxylin and eosin-stained sections of each tumor were reviewed by two expert pathologist of pediatric pathology research center of Mofid children's hospital and the tumors were classified as either embryonal (including botryoid and spindle cell variants) or alveolar RMS, according to the WHO classification scheme (3). Any amount of alveolar pattern was classified as ARMS, in concurrence with the criteria published by Tsokos et al, (1994) (4, 16).

Genetics Study

RNA extraction and real-time polymerase chain reaction (RT-PCR) assay methods: RNA from paraffin-embedded tissues was extracted from 10 µm sections. The microtome blade was thoroughly cleaned with 70% ethanol between different cases. The pooled sections were dewaxed by using xylol and melting at 65°C. Tumor tissue was scratched off with a sterile scalpel, collected into sterile micro centrifuge tubes. Pure RNA extraction, cDNA synthesis, and PCR process were performed according to iNtRON biotechnology company kits' protocols those were kindly provided by pediatric infectious disease research center (PIRC). Since the mRNA quality often suffers through the procedure of formalin-fixation and paraffin-embedding, it was usually necessary to choose close primers for

[Downloaded from ijpho.ssu.ac.ir on 2026-11-24]

amplification of archival material. All PCR products had the predicted length and their identity confirmed these observations, each sample was reanalyzed for the second time using a fresh reverse transcription and the individual PCRs were repeated on at least four occasions. Thus, the PCR products of paraffin-embedded samples are shorter than those of fresh-frozen ones. PCR conditions used in the amplification of all templates were 20 Sec denaturation at 94°C, 10 Sec annealing at 55°C, and 1 min/Kb extension at 72°C. When necessary, two rounds of amplifications were performed ('nested' PCR). After the first amplification (40 cycles), a second round of 40 cycles was carried out using an internal primer pair.

Results

The mean age of the study samples was 6.3±2.9 years. Females and males were relatively equally involved (52.9% vs. 47.1%). Among subjects, 32 (94.1%) of them were diagnosed to have ERMS and two (5.8%) were diagnosed to have ARMS. The most common tumor location was trunk (64.7%). The most involved age group was patients younger than 2 years old (38.2%). There were no significant differences in survival rate between both genders in 24 months follow up (P= 0.49) (Figure 1) as well as for age below and above five years (P= 0.69) or tumor location (trunk tumor and limbs/head tumor) (P= 0.11) using Kaplan- Meier statistic method (Figure 2).

None of the examined ERMS was t (2; 13) or t (1; 13) positive. In addition, PAX3 and PAX7 mutations were not detected in two ARMS cases. No evidence of translocation was detected in normal skeletal muscle.

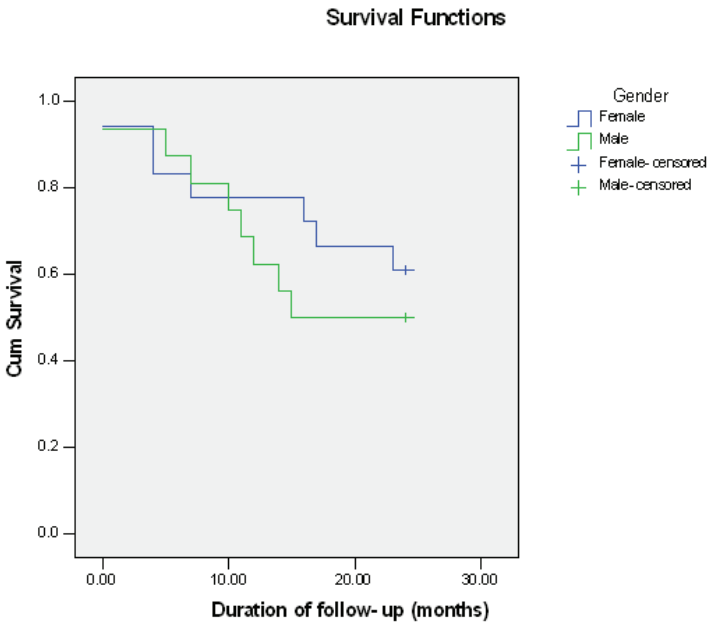

Figure 1. Survival rate during 24 months of follow up in both gender.

[Downloaded from ijpho.ssu.ac.ir on 2026-11-24]

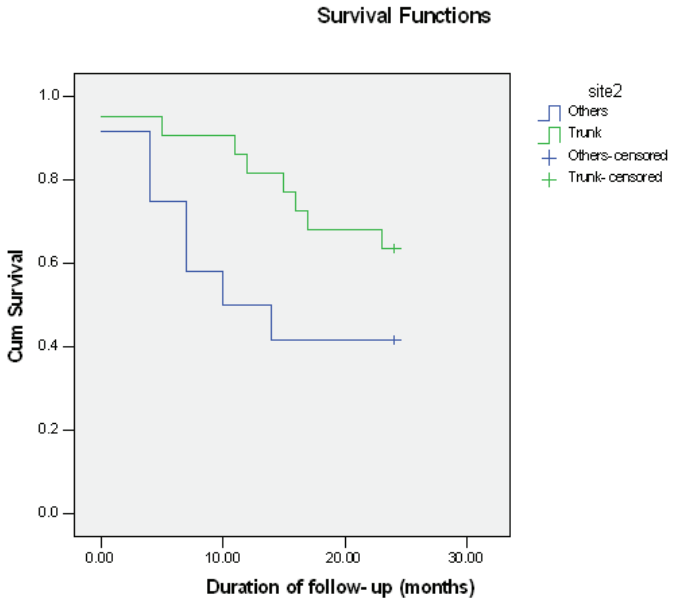

Figure 2. Differences between survival rates in 24-month follow up based on tumor location (trunk or limb/head)

Discussion

In this study, genetics and histopathological aspects of childhood rhabdomyosarcoma were investigated. The results of the study revealed that PAX3 and PAX7 genes mutations were negative in ERMS and in two cases of childhood ARMS. The different biological behavior of the two histologically distinguishable subtypes of pediatric RMS makes an accurate diagnosis desirable. Although most cases of alveolar and embryonal RMS present a clear histological picture, some overlap between the two forms may exist. Most problems arise in the definition of embryonal versus alveolar RMS in those cases that requires the establishment of minimal criteria. Poorly differentiated round cell RMS has frequently been mistaken as ERMS due to absence of a typical alveolar pattern. This variant has been recognized as the solid form of ARMS by the NCI scheme and has been shown to have a poor prognosis (4, 16).

The described chromosomal translocations between chromosome 2 and 13 or chromosome 1 and 13 are thought to be characteristic of the alveolar form of RMS (17). The present study had therefore examined the frequency of this translocation in a number of formalin-fixed, paraffin-embedded pediatric RMS.
No evidence was found for the t (1; 13) in either of ARMS. This could be due to the lower sample number in this study. Furthermore, t(2; 13) and t(1; 13) was not detected in any of the ERMS studied. In 1998, Frascella et al studied 23 cases with RMS (15 with ARMS and 8 with ERMS) with RT-PCR and found out relatively similar results to the current study. All the ERMS were PAX3 and PAX7 negative, 30% of ARMS were PAX3 negative, and %85 of ARMS were PAX7 negative relatively close to these results (18). Li Qiao-xin et al in 2009 evaluated 25 cases with RMS (10 with ARMS and 15 with

[Downloaded from ijpho.ssu.ac.ir on 2026-11-24]

ERMS)and found out all the ERMS were PAX3 and PAX7 negative like this study, 40% ARMS were PAX3 negative and 80% ARMS were PAX7 negative (19). In 2001, according to Barr FG study on the frequency of the PAX3 and PAX7 mutation in ARMS ,80% of cases have at least one of this fusions and PAX3 frequency was being 5-10 times more than PAX7 (20). It is important to consider that mRNA extracted from formalin-fixed, paraffin-embedded material is more often degraded than that from fresh-frozen material and thus the lengths of the amplification product and primers have to be chosen carefully. In this study, cDNA sequences were amplified as small as possible. It was supposed that the lack of translocations in paraffin material was due to small sample size in this study and non representativeness of the spot-check in the current study. Unfortunately, the access to only two paraffin-embedded ARMS was possible during these ten years. In this study, karyotyping of paraffin-embedded RMS was impossible since cell lines had not been established after surgery. However, it is questionable whether karyotyping was more sensitive than the PCR-based translocation assay. Cytogenetic analysis is often unsuccessful because established cell lines are prone to several karyotypic changes. A study presented two cases of ARMS that lacked specific translocations on karyotyping analysis, but showed a PAX3 and PAX7 transcripts by RT-PCR (21).

The PCR-based t(2;13) and t(1;13) assay cannot be replaced with careful morphological evaluation of childhood sarcomas, but can be used to complete current histopathological diagnosis. It may be of help in further to exclude ERMS, which carries a more favorable prognosis from the differential diagnoses list of small round cell tumor if the presence of PAX3 and/or PAX7 mutations is confirmed.

This assay may help to increase the level of diagnostic security, especially in limited biopsy material. Whether it can serve as an independent prognostic parameter in childhood RMS has to be investigated in future studies incorporating patient survival data. Furthermore, further studies with more cases of ARMS from different children's hospitals is needed to compare PCR and FISH methods and some studies to define MYCN mutation by pediatrician to provide children with more effective and safer treatment to increase their survival.

Conclusion

Based on this study, in undifferentiated small round cell tumor, exclusion of ERMS can be feasible with presence of PAX3 and/or PAX7 mutations.

Acknowledgments

This project was supported by Pediatric Congenital Hematologic Disorders Research Center.

Conflict of interest

All authors declare that they have no conflict of interest.

References

1. Malempati S, Hawkins DS. Rhabdomyosarcoma: Review of the Children's Oncology Group (COG) soft-tissue Sarcoma committee experience and rationale for current COG studies. Pediatr Blood Cancer 2012;59(1):5-10.

2. O'Brien D, Jacob AG, Qualman SJ, Chandler DS. Advances in pediatric rhabdomyosarcoma characterization and disease model development. Histol Histopathol 2012;27(1):13.

3. Newton WA, Gehan EA, Webber BL, Marsden HB, Van Unnik A, Hamoudi AB, et al. Classification of rhabdomyosarcomas and related sarcomas. Pathologic aspects and proposal for a new classification-an intergroup rhabdomyosarcoma study. Cancer 1995;76(6):1073-85.

4. Davicioni E, Anderson MJ, Finckenstein FG, Lynch JC, Qualman SJ,

[Downloaded from ijpho.ssu.ac.ir on 2026-11-24]

Shimada H, et al. Molecular classification of rhabdomyosarcoma—genotypic and phenotypic determinants of diagnosis: a report from the Children's Oncology Group. Am J Pathol. 2009;174(2):550-64.
5. Parham DM, Shapiro DN, Downing JR, Webber BL, Douglass EC. Solid alveolar rhabdomyosarcomas with the t (2; 13): report of two cases with diagnostic implications. Am J Surg Pathol 1994;18(5):474-8.
6. Barr FG, Holick J, Nycum L, Biegel JA, Emanuel BS. Localization of the t (2; 13) breakpoint of alveolar rhabdomyosarcoma on a physical map of chromosome 2. Genomics 1992;13(4):1150-6.
7. Bober E, Franz T, Arnold H-H, Gruss P, Tremblay P. Pax-3 is required for the development of limb muscles: a possible role for the migration of dermomyotomal muscle progenitor cells. Development 1994;120(3):603-12.
Goulding M, Lumsden A, Paquette AJ. Regulation of Pax-3 expression in the dermomyotome and its role in muscle development. Development 1994;120(4):957-71.
9. Liu J, Guzman MA, Pezanowski D, Patel D, Hauptman J, Keisling M, et al. FOXO1–FGFR1 fusion and amplification in a solid variant of alveolar rhabdomyosarcoma. Mod Pathol 2011;24(10):1327-35.
10. Barr FG, Galili N, Holick J, Biegel JA, Rovera G, Emanuel BS. Rearrangement of the PAX3 paired box gene in the paediatric solid tumour alveolar rhabdomyosarcoma. Nat Genet 1993;3(2):113-7.
11. Galili N, Davis RJ, Fredericks WJ, Mukhopadhyay S, Rauscher FJ, Emanuel BS, et al. Fusion of a fork head domain gene to PAX3 in the solid tumour alveolar rhabdomyosarcoma. Nat Genet 1993;5(3):230-5.
12. Shapiro DN, Sublett JE, Li B, Downing JR, Naeve CW. Fusion of PAX3 to a member of the forkhead family of transcription factors in human alveolar rhabdomyosarcoma. Cancer Res 1993;53(21):5108-12.
13. Sorensen PH, Lynch JC, Qualman SJ, Tirabosco R, Lim JF, Maurer HM, et al. PAX3-FKHR and PAX7-FKHR gene fusions are prognostic indicators in alveolar rhabdomyosarcoma: a report from the children's oncology group. J Clin Oncol 2002;20(11):2672-9.
14. Maulbecker CC, Gruss P. The oncogenic potential of Pax genes. EMBO J 1993;12(6):2361.
15. Davis RJ, D'Cruz CM, Lovell MA, Biegel JA, Barr FG. Fusion of PAX7 to FKHR by the variant t (1; 13)(p36; q14) translocation in alveolar rhabdomyosarcoma. Cancer Res 1994;54(11):2869-72.
16. Tsokos M, editor. The diagnosis and classification of childhood rhabdomyosarcoma. Semin Diagn Pathol 1994.
17. Gunawan B, Granzen B, Keller U, Steinau G, FÜzesi L, Schumpelick V, et al. Clinical aspects of alveolar rhabdomyosarcoma with translocation t (1; 13)(p36; q14) and hypotetraploidy. Pathol Oncol Res. 1999;5(3):211-3.
18. Frascella E, Toffolatti L, Rosolen A. Normal and rearranged PAX3 expression in human rhabdomyosarcoma. Cancer Genet Cytogenet 1998;102(2):104-9.
19. Li Q-X, Liu C-X, Chun C-P, QI Y, CHANG B, LI X-X, et al. Chromosomal imbalances revealed in primary rhabdomyo-sarcomas by comparative genomic hybridization. Chin Med J 2009;122(11):1277-82.
20. Barr FG. Gene fusions involving PAX and FOX family members in alveolar rhabdomyosarcoma. Oncogene 2001;20(40):5736-46.
21. Barr FG, Chatten J, D'Cruz CM, Wilson AE, Nauta LE, Nycum LM, et al. Molecular assays for chromosomal translocations in the diagnosis of pediatric soft tissue sarcomas. Jama 1995;273(7):553-7

[Downloaded from ijpho.ssu.ac.ir on 2026-11-24]

[Downloaded from ijpho.ssu.ac.ir on 2026-11-24]