

## 18F-FDG PET/CT Images in a Child with Cutaneous B cell Lymphoblastic Lymphoma Presented with Bone Involvement

Inci Uslu Biner MD<sup>1\*</sup>, Ebru Tatci MD<sup>1</sup>, Ozlem Ozmen MD<sup>1</sup>, Suna Emir MD<sup>2</sup>, Dilek Kacar MD<sup>2</sup>

1. Ataturk Chest Diseases and Thoracic Surgery Training and Research Hospital, Department of Nuclear Medicine, Ankara, Turkey

2. The ministry of Health Ankara Children's Diseases Hematology Oncology Training and Research Hospital, Pediatric Oncology Unit, Ankara, Turkey

Corresponding author: Inci Uslu Biner, MD. Department of Nuclear Medicine, Ataturk Chest Diseases and Thoracic Surgery Training and Research Hospital, Sanatoryum Cad.06280, Kecioren, Ankara, TURKEY. Email: inciulusu@yahoo.com

Received: 20 June 2016

Accepted: 11 August 2016

### Abstract

B-cell lymphoblastic lymphoma (B-LBL) is an uncommon subtype of pediatric non-Hodgkin Lymphoma (NHL) which rarely involves the skin primarily. The findings of 2-deoxy-2-[F-18] fluoro-D: -glucose (FDG) positron-emission tomography/computed tomography (PET/CT) scan of an 8-year-old boy with cutaneous B-cell lymphoblastic lymphoma were presented. PET/CT scan demonstrated mild FDG uptake in the lesion located on the scalp and also multiple bone metastases with increased FDG uptakes in several areas. The importance of 18F-FDG PET/CT scan in primary staging of the patients with primary cutaneous B-LBL was emphasized due to its impact on planning of therapy via the determination of unexpected malign infiltration sites.

**Key Words:** Precursor B-Cell Lymphoblastic Lymphoma, Cutaneous, Bone Metastasis, Child, PET/CT

### Introduction

Lymphoblastic leukemia/lymphoma is a rare subtype of NHL during childhood. B-LBL constitutes approximately 10 to 15 % of the LBLs. Primary involvement of the skin is a rare manifestation of B-LBL because cutaneous B-LBL usually appears secondary to systemic nodal B-LBL. A case of primary cutaneous B-LBL without clinically palpable lymph nodes and bone marrow involvement was reported in whom FDG PET/CT revealed bone metastases.

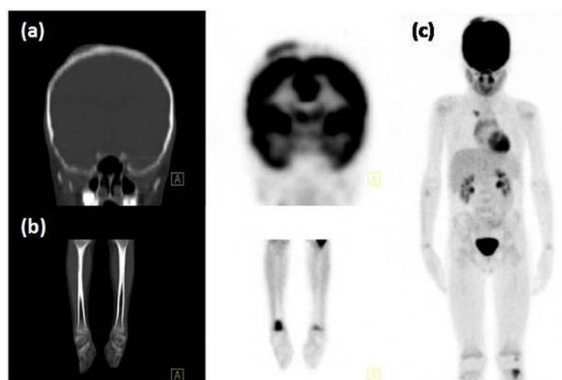
### Case presentation

An 8-year old boy with a white colored mass on the scalp which was increased in size over few weeks was investigated in the current study. The mass was approximately 17x37mm in size, non – itchy and round, tender, and had a smooth surface. The remaining physical examination was normal and there wasn't any other skin lesion and palpable lymph

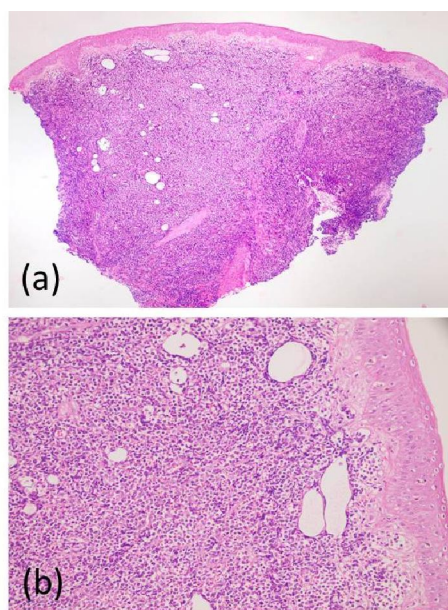
nodes in the physical examination. Lesion biopsy suggested a B -cell Lymphoblastic Lymphoma. For staging, bone marrow (BM) trapping was performed. There was no evidence of lymphoma involvement in BM. FDG PET/CT scan was performed to stage the disease. PET/CT revealed a hypermetabolic soft tissue mass in the scalp in vertex localization with maximum standardized uptake value (SUVmax) of 7.61 (Fig1a). There were also multiple bone metastases with increased FDG uptake in right clavicle, left proximal tibia, bilaterally distal tibia, lateral condyle of left femur, right proximal fibula and right proximal radius with maximum standardized uptake value (SUVmax) of 4,10 (Fig1b,c). Additionally, lymph nodes in the head and neck region with lower FDG uptakes were detected. On the basis of the pathologic diagnosis, he was diagnosed with primary cutaneous lymphoblastic lymphoma (Fig 2, 3)

Depending on the PET/CT findings; the patient started to receive chemotherapy

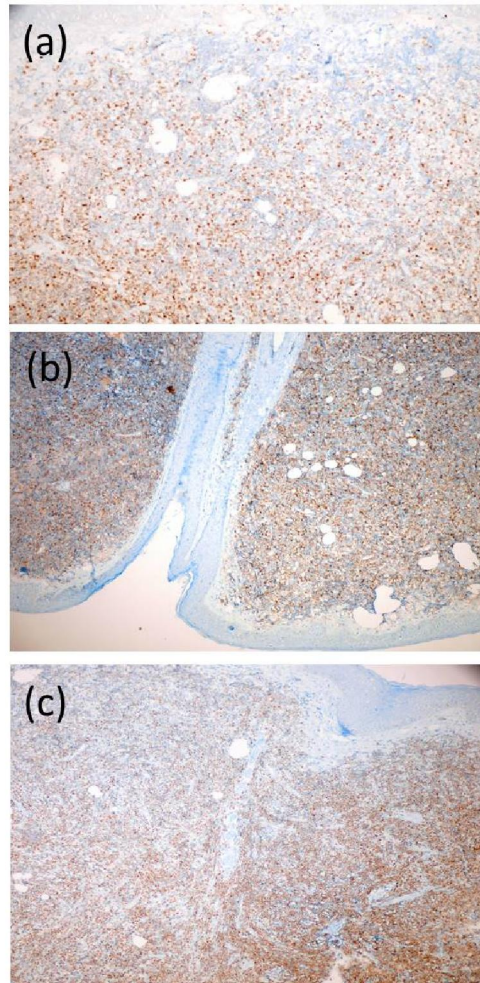
according to ALL protocols and the patient is still under treatment.



**Figure 1.** FDG PET/CT was performed with a dedicated PET/CT scanner (Biograph LSO HI-REZ PET/CT; Siemens, Medical Solutions, Knoxville, TN, USA) as a part of staging before treatment in a 8-year-old boy with cutaneous B-cell Lymphoblastic Lymphoma and coronal image of the head showed high FDG uptake in the scalp with maximum standardized uptake value (SUVmax) of 7.61 (a). The Maximum Intensity Projection (MIP) presentation of the staging PET/CT examination demonstrating multiple bone metastases with increased FDG uptakes (SUVmax: 4.10) and the FDG uptakes in tibiae are also seen (b, c).



**Figure 2.** HE 40X (a) and HE 200X (b): The diffuse dermal infiltration of monotonous medium-sized lymphoblasts with high nucleocytoplasmic ratio, hyperchromatic oval-round nucleus and indistinct nucleoli. The epidermis is intact.



**Figure 3.** TDT 100X: Most of the tumor cells show nuclear expression of TDT at different expression levels (a) and Tm cells show strong and diffuse staining with CD22 and PAX5 antibodies (b, c).

### **Discussion**

Lymphoblastic leukemia/lymphoma (LBL) is a highly aggressive malignant neoplasm of precursor lymphocytes of B- or T-cell. Precursor B-cell LBL is a rare subtype of childhood NHL. While mediastinal masses are commonly seen in T-cell variant, extramediastinal involvement such as skin and bone is more common in this subtype (2, 3). In a study of The Children's Leukemia Cooperative Group of the European Organization of Research and Treatment of Cancer (EORTC) cutaneous involvement have been demonstrated to be an early manifestation of Acute Lymphoblastic leukemia (ALL) or LBL (4). Depending on the extent of disease,

treatment decision and the prognosis of primary cutaneous lymphomas (PCL) could be affected since extranodal involvement is an important prognostic factor for patients with lymphoma before treatment (5). FDG PET/CT, that provides both anatomic and metabolic information facilitates the detection of affected extranodal sites especially in NHL and is reported to be an important and useful tool for providing valuable information about disease extent in cutaneous lymphomas (6). Primary cutaneous B-cell lymphoma in childhood has rarely been reported in the literature (7, 11). Although there are some reported cases of B-LBL primarily in the skin, (6, 7) there is limited data in

existing literature regarding the the roles of 18F-FDG PET imaging in primary cutaneous B-cell lymphoma in children. We provide additional support to the literature by reporting the bone metastases of a cutaneous lymphoma in a child detected by initial staging PET/CT findings. The most frequent location of skin lesions in children with ALL or LBL is on the head (4). In this case presented here who was admitted to hospital with a mass in the scalp and diagnosed as B-LBL histopathologically, PET/CT revealed multiple bone involvement although he didn't have any skeletal complaint and had normal skeletal surveys. If there was only FDG uptake at the lesion located at the scalp the patient would be accepted as primary cutaneous B LBL and be treated on short invasive protocole that used for other B-cell LL. However, in this patient an intensive lymphoblastic leukemia (ALL)-like chemotherapy protocol was administered since PET/CT revealed several bone metastases. Therefore, PET/CT may guide an appropriate treatment strategy. In conclusion, this case report we described here is an example of cutaneous NHL, as a rarely seen type of NHL, in pediatric population. We wish to remind the importance of FDG PET/CT in the primary staging of lymphomas that originated from unusual extranodal sites in children and emphasize its possible role to switch the treatment protocol.

### Conflict of interest

Authors declared no conflict of interest.

### References

1. Maitra A, McKenna RW, Weinberg AG, Schneider NR, Kroft SH. Precursor B-cell lymphoblastic lymphoma. A study of nine cases lacking blood and bone marrow involvement and review of the literature. *Am J Clin Pathol* 2001; 115(6): 868-75.
2. Kahwash SB, Qualman SJ. Cutaneous lymphoblastic lymphoma in children: report of six cases with precursor B-cell lineage. *Pediatr Dev Pathol* 2002; 5(1): 45-53.
3. Cortelazzo S, Ponzoni M, Ferreri AJ, Hoelzer D. Lymphoblastic lymphoma. *Crit Rev Oncol Hematol* 2011; 79(3): 330-43.
4. Millot F, Robert A, Bertrand Y, Mechinaud F, Laureys G, Ferster A, et al. Cutaneous involvement in children with acute lymphoblastic leukemia or lymphoblastic lymphoma. The Children's Leukemia Cooperative Group of the European Organization of Research and Treatment of Cancer (EORTC). *Pediatrics* 1997; 100(1): 60-4.
5. Spaccarelli N, Gharavi M, Saboury B, Cheng G, Rook AH, Alavi A. Role of 18F-fluorodeoxyglucose positron emission tomography imaging in the management of primary cutaneous lymphomas. *Hell J Nucl Med* 2014; 17(2): 78-84.
6. Kumar R, Xiu Y, Zhuang HM, Alavi A. 18F-fluorodeoxyglucose-positron emission tomography in evaluation of primary cutaneous lymphoma. *Br J Dermatol* 2006; 155(2): 357-63.
7. Sharon V, Mecca PS, Steinherz PG, Trippett TM, Myskowski PL. Two pediatric cases of primary cutaneous B-cell lymphoma and review of the literature. *Pediatr Dermatol* 2009; 26(1):34-9.
8. Rashidghamat E, Robson A. Primary cutaneous precursor B cell lymphoblastic lymphoma in a child, complicated by fatal disseminated varicella zoster virus. *Clin Exp Dermatol* 2015; 40(8): 839-43.
9. Biasotti S, Sementa AR, Zupo S, Nemelka O, Pistoia V, Garaventa A. A novel pediatric case of cutaneous pre-B lymphoblastic lymphoma. *Haematologica* 2001; 86(9): 997-8.
10. Samarghandi A, Gru AA, Natwa M, Barker DW. F(18)FDG PET/CT appearance in primary cutaneous diffuse large B-cell lymphoma, leg type. *Clin Nucl Med* 2015; 40(6): 506-8.
11. Kalender E, Yilmaz M, Erkilic S, Yilmaz M, Celen Z. Bilateral cutaneous diffuse large B-cell lymphoma on FDG PET/CT. *Clin Nucl Med* 2011; 36(10): 153-5.