

Case Report

An Unusual Presentation of Extrarenal Malignant Rhabdoid Tumor of Soft Tissue: A case report and review of the literature

Pedram M ¹, Hiradfar AA ¹, Karimian N ²

1- Department of Pediatrics Hematology, Research Center of Thalassemia and Hemoglobinopathy, Shafa Hospital, Jondishapoor University of Medical Science, Ahwaz, Iran.

2- Research Center of Thalassemia and Hemoglobinopathy, Jondishapoor University of Medical Science, Ahwaz, Iran.

Abstract

Extra renal extra cranial malignant rhabdoid tumors (MRT) are rare, frequently lethal and affect mostly children. No definite treatment has been made; and the role of radiation therapy is poorly defined.

This report explains a 14 year old girl with MRT in her neck soft tissue. She is alive with no evidence of disease 18 months after diagnosis. Through the experience with this case, we suggested that radiation therapy is not beneficial enough in all MRT cases and an aggressive multimodality approach should be chosen according to the stage and the state of its respectability.

Keywords

Malignant rhabdoid tumor, Soft tissue, Radiation therapy, aggressive multimodality

Corresponding Author:

Hiradfar AA MD. Department of Pediatrics Hematology, Research Center of Thalassemia and Hemoglobinopathy, Shafa Hospital, Jondishapoor University of Medical Science, Ahwaz, Iran.
Email: hiradfarataolah@yahoo.com

Introduction

Highly aggressive and frequently lethal, malignant rhabdoid tumor (MRT) has only recently as a distinct clinicopathologic entity in the pediatric population. It was first described in 1978 as a variant of wilms tumor “rhabdomyosarcomatous” features (1). In 1981, it was recognized with extra renal variants, which reported in the central nervous system (CNS), liver, female genital tract, and soft tissues (2-10). The CNS is the most frequent and well-studied non-renal location of MRT (3,11-13). In our knowledge, extra renal and extra cranial MRT has come primarily from isolated case reports (13). Extra renal malignant rhabdoid tumor is highly lethal, rare tumor with a poor prognosis. Three years survival for extra renal, extra cranial rhabdoid tumors estimated 9% (SD± 6) and an incidence of 0.15 per million children under the age of 15 (2,14). The incidence of MRT in adults is lower or might less frequently report. The medical literature described the highly lethal nature of MRT, but there are reports of longer survivals from 72 to 192 months (2,4,15,16). The diagnosis of extra renal MRT is usually based on the cytologic similarity to classic MRT of the kidney. The primary characteristics of these tumors are filamentous cytoplasmic, macro nucleoli, and abundant cytoplasm (3, 10). At the chromosomal level, the most common aberrations are translocations and deletions of chromosomal band 22q11. (10). Immunohistochemical staining shows marked heterogeneity (10, 17). Most MRTs

are immunoreactive for mesenchymal (vimentin) and epithelial markers (cytokeratin, epithelial membrane antigen) (17). However, immunoreactivity for desmin, muscle-specific actin, glial fibrillary acidic protein, CD57, S100, and myoglobin are reported for some of them (10, 17). To the best of our knowledge, a few cases with primary location of neck soft tissue were reported so far, and the oldest patient had been 4.5 years old at the time of diagnosis (3,10,18-20) (Table I) We report a soft tissue MRT in the neck of a 14 years old girl.

Case presentation

A 14-year-old female presented with a mass in her neck since one year ago. A palpable, firm, immobile, and lobulated mass about 3.5×4×5 cm was detected in the posterolateral part of right side the neck. The mass did not have pulsatile pattern or bruit. Skin on the mass had no changes. Her neck mass had got bigger every time. Physical examinations of the patient were unremarkable except for the neck mass. There was no obvious history of fever, bone pain, sweating, or weight loss, and her swallowing and breathing was normal. There were no significant lymphadenopathies in other sites. She had no significant past medical history. Her blood tests were normal, including complete blood count, clotting profiles, renal and liver function tests. Ultrasonography of the mass revealed a solid soft tissue mass about 4×5×5 cm in with 3-4 adherent lymph nodes. Computed tomography (CT) scan showed a soft tissue mass in the right side of nasopharynx, prominence in posterior parapharyngeal wall, with multiple heterogenous lymphadenopathies (Figure I). No metastasis to the lung or other visceral organs was detected in the CT scans. No distinct area with increased uptake was noted at bony structures in whole body scan by Tc-99 MDP. She had a normal reactive bone marrow pattern. A fine needle aspiration (FNA) of the mass was performed prior to definitive wide excision. The excised tumor consisted of a large, lobulated, well-circumscribed mass (3×3.8×3.5 cm) with two adherent lymph nodes. Histological examination of the mass diagnosed a malignant rhabdoid tumor (MRT). The mass was composed of cohesive sheets of large atypical cells with marked nuclear polymorphism and prominent nucleoli surrounded by eosinophilic cytoplasm and exhibited frequent mitosis. Adherent lymph nodes tissue was also infiltrated by these atypical cells. Immunohistochemistry were positive for vimentin, desmin, and cytokeratin (focally), but they were negative for CD45, CD117, S-100, epithelial membrane antigen (EMA), and smooth muscle actin. No consistently effective regimen for MRT has yet been reported and we decided to initiate adjuvant chemotherapy.

The treatment was initiated with VAC (Vincristin 1.5mg/m², Actinomycin D 0.015mg/kg × 5 days, Cyclophosphamide 2.2g/m²) and VIE (Vincristin 1.5mg/m², Ifosphamide 1800mg/m² × 5 days, Etoposide 100mg/m² × 5 days), and they repeated every 3-weeks. After the six courses of chemotherapy, CT scans did not show any metastasis in her chest, abdomen, and pelvis. There was a complete remission of the neck mass on CT imaging. She was treated with a further six courses of chemotherapy. The patient is alive and she is clinically disease-free until 18 months after treatment.

Discussion

MRTs have been described in multiple anatomic locations. According to the literature, less than 10 cases with MRT in the neck soft tissue were reported without any metastasis at the time of diagnosis. The cases were between 5-54 months old at the time of diagnosis (Table I) (3, 10, 13, 18-20)

Present case was the first patient with soft tissue MRT located in the neck with local invasion and no significant metastasis. She was diagnosed in age 14, which was unexpected presentation for highly aggressive extra renal malignant rhabdoid tumor sized 3×3.8×5.3 cm without any metastasis. MRTs are rare tumors without clear treatment and the role of radiotherapy is not well defined (13). Recently published report of 2 cases with MRT of neck soft tissue suggested that radiotherapy with chemotherapy and surgery has potential to prolong survival (13). In this case, considering the stage of the tumor and the state of its primary respectability, we decided to initiate adjuvant chemotherapy with VAC and VIE protocols for a total of 12 courses. In addition, she did not received radiotherapy, and she is still alive and disease-free for 18 months after treatment.

In conclusion, she survived with this treatment longer than similar soft tissue reported MRT cases. So, the experience of this case and reviewing the literature showed RT is not beneficial enough in all MRT cases and an aggressive multimodality approach should be chosen according to the MRT stage and the state of its respectability.

*S.T.N: Soft Tissue Tumor

Patient	Age at DX (mo)	Sex	Primary Site	Metastasis at DX time	Tumor Size (Cm)	Treatment	Vital status after DX(mo)	year	Author	Ref#
1	21	F	S.T.N	No	7x6x5	CMT,S	DOD,14	2001	Helmeke	18
2	9	M	S.T.N	No	6.5x5.3x5.1	CMT,S	NED,15	2001	Helmeke	18
3	30	F	S.T.N	No	Unknown	CMT,S,RT	NED,104	2007	Madigan	19
4	54	M	S.T.N	No	Unknown	CMT,RT	DOD,5	2007	Madigan	19
5	Unknown	M	S.T.N	No	Unknown	Unknown	Unknown	1994	Parham	3,10
6	12	F	S.T.N	No	7	CMT,RT,S	NED,84	2008	Puri	13
7	5	F	S.T.N	No	5.4x4x3	CMT,S,RT	DOD,6	2008	Puri	13
8	10	M	S.T.N	Yes	7.5	Unknown	Unknown	1998	Fanburg	20
9	23	M	S.T.N	No	4.5	Unknown	NED,72	1998	Fanburg	20

Table I: Extrarenal extracranial MRTs in Soft Tissue of Neck
(review of recent reports in brief)

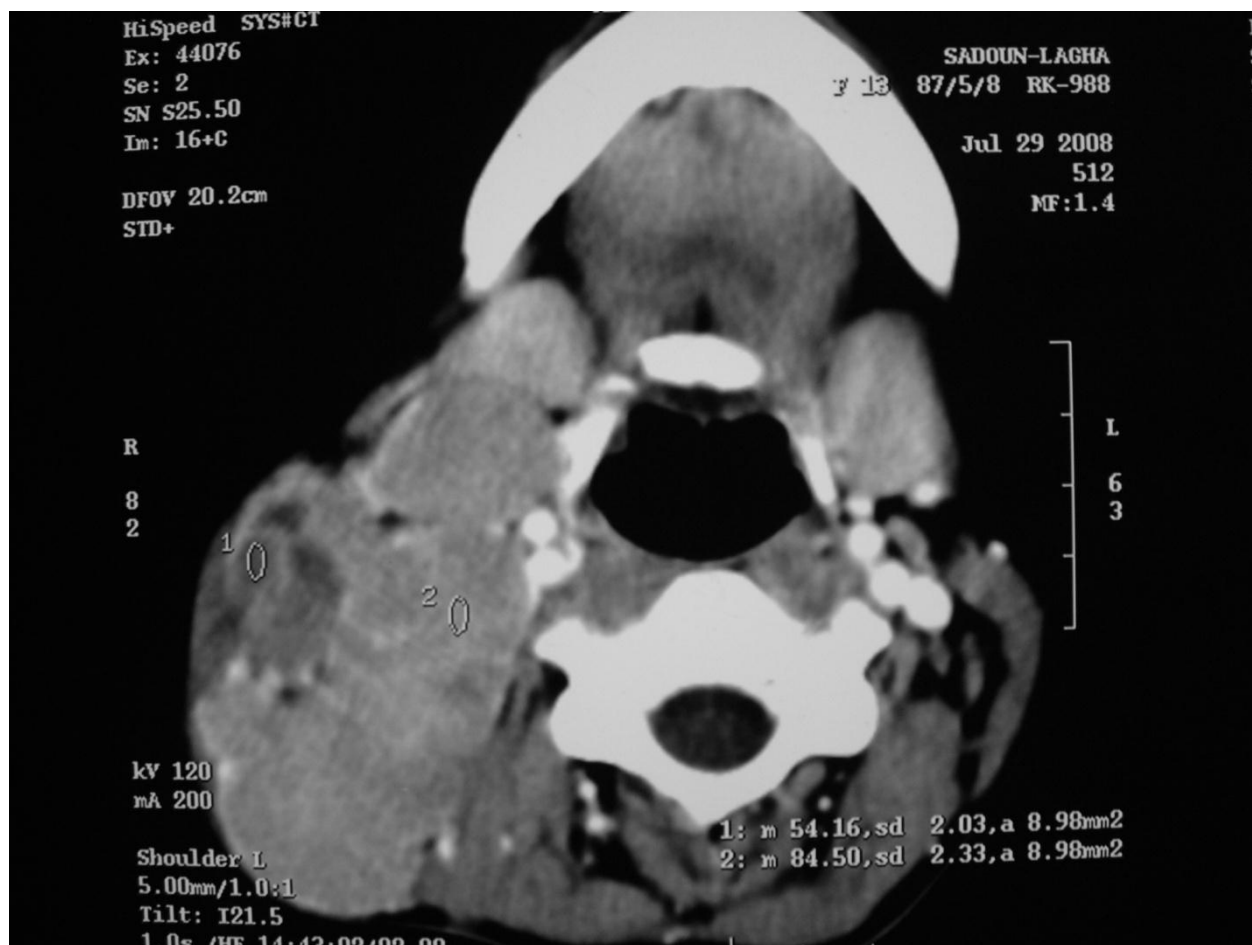


Figure I:

Computed tomography of the neck demonstrating a soft tissue mass in the right side of nasopharynx, prominence in posterior parapharyngeal wall

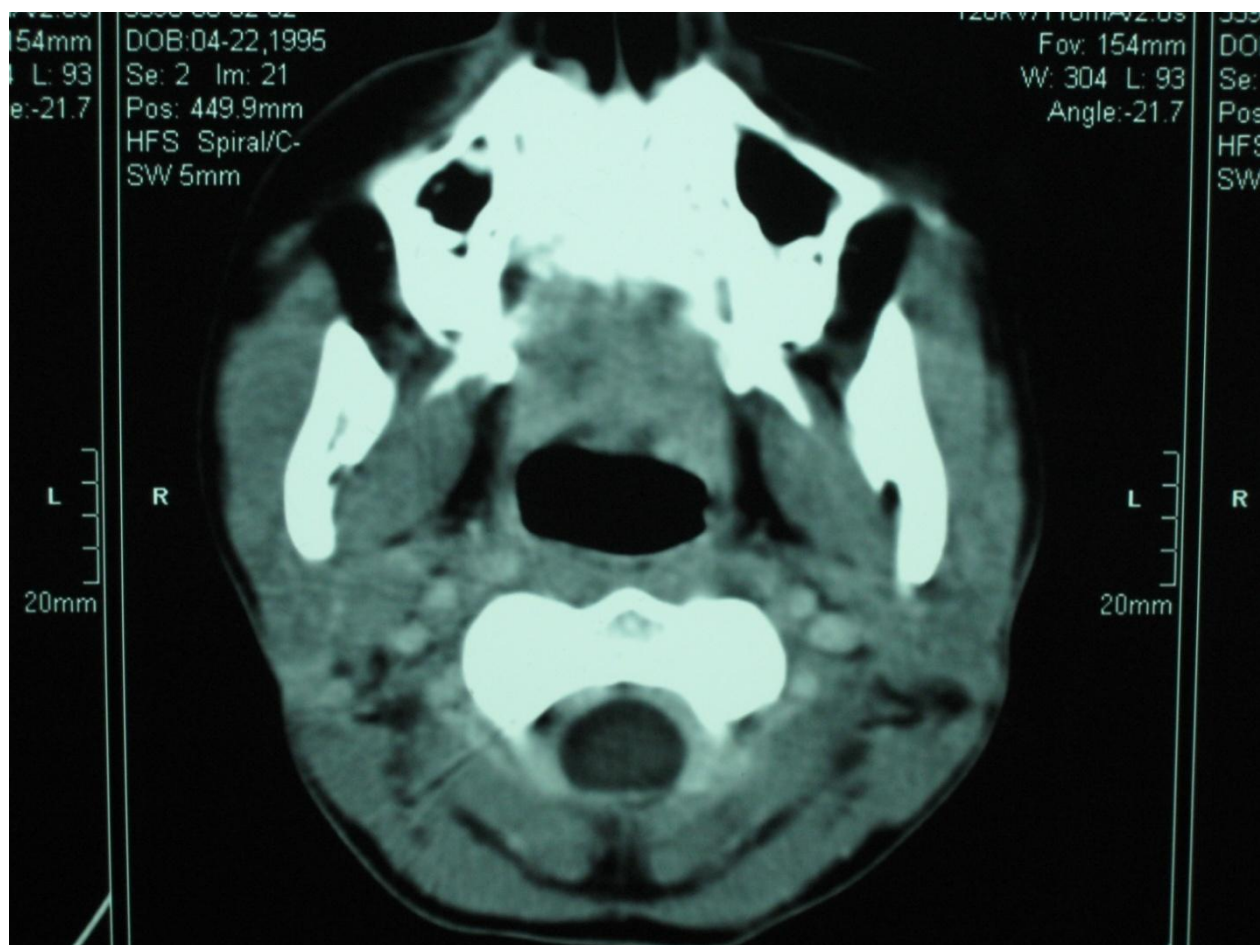


Figure II:
15 months after chemotherapy completion, there is no any neck mass

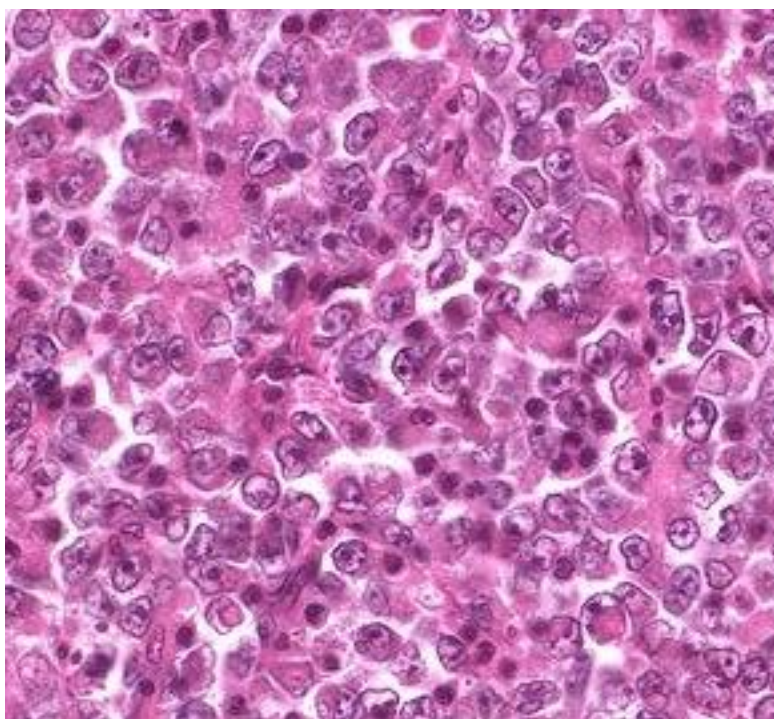


Figure III;
Microscopic histopathology
There are many atypical cells, with macronucleoli and abundant cytoplasm

References

1. Bekwith J, Palmar N. Histopathology and prognosis of Wilms tumors. Results from First National Wilms Tumor study. *Cancer* 1978; 41: 1937-1948.
2. Horazdovsky R, Manivel J, Cheng E. Successful Salvage and Long-Term survival after Recurrent Malignant Rhabdoid Tumor. *Sarcoma*. 2007;2007:1-4.
3. Parham D, Weeks D, Beckwith J. The clinicopathologic spectrum of putative extrarenal rhabdoid tumors: an analysis of 42 cases studied with immunohistochemistry or electron microscopy. *The American Journal of Surgical Pathology* 1994; 18(10): 1010-1029.
4. Sotelo-Avila C, Gonzalez-Crussi F, deMello D, Vogler C, Gooch WM 3rd, Gale G, et al. Renal and extrarenal rhabdoid tumors in children. a clinicopathologic study of 14 patients. *Seminars in Diagnostic Pathology* 1986; 3(2): 151-163.
5. Small E, Gordon G, Dahms B. Malignant rhabdoid tumor of the heart in an infant. *Cancer* 1985; 55: 2850-2853.
6. Rubenchik I, Dardick I, Auger M. Cytopathology and ultrastructure of primary rhabdoid tumor of the lung. *Ultrastruct Pathol* 1996; 20: 355-360.
7. Gündüz K, Shields JA, Eagle RC Jr, Shields CL, De Potter P, Klombers L. Malignant rhabdoid tumor of the orbit. *Arch Ophthalmol* 1998; 116: 243-246.
8. Koibuchi Y, Lino Y, Yoshita T, Yokoe T, Shinkai H, Kawashima K, et al. Malignant rhabdoid tumor of the breast: a case report. *Jpn J Clin Oncol*. 1995; 25: 273-277.
9. White FV, Dehner LP, Belchis DA, Conard K, Davis MM, Stocker JT, et al. Congenital disseminated malignant rhabdoid tumor. *Am J Surg Pathol* 1999; 23: 249-256.
10. Sajedi M, Wolff JE, Egeler RM, Pinto A, Hughes R, Anderson RA, et al. Congenital Extrarenal Non-Central Nervous System Malignant Rhabdoid Tumor. *J Pediatr Hematol Oncol* 2002; 24(4):316-20.
11. Hilden JM, Meerbaum S, Burger P, Finlay J, Janss A, Scheithauer BW, et al. Central nervous system atypical teratoid/rhabdoid tumor. Results of therapy in children enrolled in a registry. *J Clin Oncol* 2004; 22: 2877-2884.
12. Rorke L, Packer R, Biegel J. Central nervous system atypical teratoid/rhabdoid tumors of infancy and childhood. *J Neurosurg* 1996; 85: 56-65.
13. Puri D, Meyers P, Kraus D, LaQuaglia M, Wexler L, Woiden S. Radiotherapy in Multimodal Treatment of Extrarenal Extracranial Malignant Rhabdoid Tumors. *Pediatr Blood Cancer* 2008; 50: 167-169.
14. Brennan BM, Foot AB, Stiller C, Kelsey A, Vujanic G, Grundy R, et al. Where to next with extracranial rhabdoid tumors in children. *European Journal of cancer* 2004; 40(4): 624-626.
15. Parham D. An inaccuracy. *Am J Surg Path* 1995; 19(4): 488-489.
16. Kodet R, Newton WA Jr, Sachs N, Hamoudi AB, Raney RB, Asmar L, et al. Rhabdoid tumors of soft tissues: a clinicopathologic study of 26 cases enrolled on the intergroup rhabdomyosarcoma study. *Human Pathology* 1991; 22(7): 674-684.
17. Wick M, Ritter J, Dehner L. Malignant rhabdoid tumors: a clinicopathologic review and conceptual discussion. *Semin Diagn Pathol* 1995; 12: 233-248.
18. Helmeke L, Engler S, Mattke A, Henne-Bruns D. Extrarenal Malignant Rhabdoid Tumors in childhood. *Med Pediatr Oncol* 2001; 36: 317-319.
19. Madigan C, Armenian S, Malogowkin M, Mascarenhas L. Extracranial Malignant Tumors in childhood. The Children Hospital Los Angeles Experience. *Cancer* 2007; 110: 2061-2066.
20. Fanburg-Smith J, Hengge M, Hengge U, Smith J, Miettinen M. Extrarenal Rhabdoid Tumors of Soft Tissue: A Clinicopathologic and Immunohistochemical Study of 18 cases. *Ann Diagn Pathol* 1998;2: 351-362.