

Adrenocortical carcinoma in a 8 years old child: a Case Report

Fatemeh Tabatabaei MD^{1,*}, Mohammad Reza Sharif MD², Nahid Reisi MD³

1. Isfahan Endocrine & Metabolism Research Center, Isfahan University of Medical Sciences, Isfahan, Iran

2. Infectious Disease Research Center, Kashan University of Medical Sciences, Kashan, Iran

3. Child Growth & Developmental Research Center, Isfahan University of Medical Sciences, Isfahan, Iran

*Corresponding author: Dr Fatemeh tabatabaei, Isfahan Endocrine & Metabolism Research Center, Isfahan University of Medical Sciences, Isfahan, Iran. Email: fatemeh_tbtb@yahoo.com.

Received: 27 April 2015

Accepted: 17 February 2016

Abstract

Background: Unilateral tumors or masses of the adrenal gland are common. They are categorized as either functional (hormone-secreting) or silent and as either benign or malignant. Adrenocortical tumors are rare in childhood, with an incidence of 0.3-0.5 cases per one million child-years. Almost half of childhood tumors are adrenocortical carcinomas (ACC). Most ACCs are sporadic, but specially in children, some occur as a component of hereditary cancer syndromes. The most common presenting symptom occurring in 50-80% in children with ACC is virilization; overall, survival is poor for adrenocortical carcinoma (ACC). The prognosis in children who have adrenocortical carcinoma (ACC) appears to be better than that of adults, at least for early-stage disease. Residual or metastatic disease carries a poor prognosis. Complete resection is required for cure.

Case presentation: The patient is a 8 years old girl presented progressive virilizing symptoms including deepening of the voice, clitoromegaly, growth acceleration, acne and premature pubic and axillary hair development before 8 years old.

Conclusion: The clinical, biochemical, histological features along with differential diagnosis are discussed. This case is presented because of its rarity. This case study report a rare case and also to highlight the importance of differentiating ACC from an adenoma particularly in pediatric patients.

Keywords: Adenoma, Adrenocortical Carcinoma, Child Virilization

Introduction

Adrenocortical tumors are rare neoplasm in childhood and most commonly reported in adult patients (1). Adrenocortical tumors (ACT) occur with a worldwide incidence of 0.2-0.3 cases per million. Approximately 90% of ACT is malignant and they account for 0.2% of all pediatric solid malignancies. There is a bimodal age distribution in the first and fourth decades of life and most children present before the age of 5 years. Girls are more affected than boys and this apparently increases from early childhood, whereas this ratio female: male goes up from the 1.5: 1 to 6: 1 during adolescence (2).

Symptoms of endocrine hyperfunction are presented in 80-90% of children with adrenal tumors. In addition to virilization, 15-40% of children with adrenocortical tumors also have cushing syndrome.

Whereas isolated virilization occurs frequently, children with adrenal tumors usually do not present cushing syndrome alone (1).

Childhood ACT is usually associated with constitutional genetic abnormalities. Fifty percent of children have Li-Fraumeni syndrome, a dominantly inherited condition that results from mutations of the p53 gene. Genetic counseling and testing should be considered for all families of children with ACT. Germline mutations of p53 do not appear to be associated with ACT in older children and young adults (2).

Case report

A 8 years old girl of nonconsanguineous parents was referred to pediatric clinic in khorshid hospital in Isfahan university.

She was visited with the complaints of facial acne, appearance of the pubic hair and gradual enlargement of the clitoris for 2 months ago and gradual deepening of the voice for 3 months. (Fig-1)

She had no history of menstrual bleeding or breast enlargement, no history of headache, vomiting, convulsion or ingestion of any offending drug. Her height was 145 cm (upper than 95% percentile of height) and weight was 37 kg (on 95% percentile of weight) and blood pressure was 100/60 mm of Hg, and pulse was 100 beats/min. In physical examination she had clitoromegaly (Length clitoris was 4 cm and its width was 1cm), vaginal orifice intact and urethral orifice normal in position, pubic hair was stage 4 tanner, breast was stage 1 tanner. Examinations of other systems did not reveal any abnormality.

The report of lab test was Na=140 mEq/L, K= 4.3 mEq/L, Testosterone (RIA) was raised [1.7 ng/mL (normal 0.06-0.5)], DHEA-S (CLIA) was raised [347 µg/dL (normal 9-79)], ACTH was normal [14.6 pg/mL (normal 4.8-49)], Cortisol (8 AM) was normal [8.6 µg/dL (normal 6.2-19.4)], 17OH Progesterone (RIA) was slightly raised (5.9 ng/mL).

Many adrenocortical tumors have a relative deficiency of 11β-hydroxylase activity and increased amounts of deoxycorticosterone; these patients are hypertensive, and their tumors are often malignant (1). Differential diagnosis of clinical hyperandrogenism is shown in Table I (4).

Ultrasonography of whole abdomen showed a solid hypoechogenic mass measuring about 50×59 mm in the left adrenal, without pressure on the left kidney, uterus and ovaries was prepubertal size. In contrast enhanced CT study of abdomen, there was a solid mass lesion of about 55 mm diameter at anatomic site of left adrenal gland which is heterogeneous and renal cortex is intact and no gross abnormal lymph adenopathy is detectable (Fig-2). For resection of the tumor and

getting specimen for histopathology the patient was referred to surgery unit.

After operation an encapsulated mass of 6×5×4.5 cm and 57 grams without extension to nearby structures was removed. It was categorized as stage II. Microscopic examination showed a neoplastic proliferation of atypical cells composed of adrenocortical cells. These findings were consistent with adrenocortical carcinoma. DHEA-S (15 µg/dL), Testosterone (0.3 ng/mL) measured 6 weeks after operation was within normal limit. After confirming the diagnosis the patient was advised to get admission in Pediatric Hematology-Oncology department for chemotherapy and further management.

Discussion

Virilization can occur in childhood due to excessive amounts of androgens. In a boy, virilization may be due to precocious puberty, while congenital adrenal hyperplasia (CAH) and androgen producing tumors of the gonads or adrenals and Cushing's syndrome are occasional causes in both sexes. (table-1)

Our patient was a rare case because CAH is the most common cause of virilization in girls. Ninety percent of ACT affecting young children are functional and the majority of children present with clinical features of androgen excess including accelerated growth and skeletal maturity, acne, pubic hair growth, growth of the penis in boys and clitoromegaly in girls. Estrogen secretion occurs very rarely and induces accelerated growth and skeletal maturity, breast development and vaginal bleeding in girls. Approximately 40% of patients are hypertensive at diagnosis because of glucocorticoid or mineralocorticoid excess or compression of the renal artery (2-3). A minority of patients present with hypertensive seizures. Glucocorticoid excess results in the clinical characteristics of Cushing syndrome in a minority of patients.

Older patients are more likely to have nonfunctioning tumors and present more commonly with abdominal pain and weight loss.

Surgery should aim for complete en bloc tumor resection. Hyperglycemia and electrolyte abnormalities before surgery should also be corrected. Spironolactone, an aldosterone antagonist, has a more rapid effect and may be required in large doses in children with severe or refractory hypertension. In 20% of patients, the inferior vena cava is infiltrated with tumor thrombus making difficulty in radical surgery (2).

All patients with glucocorticoid secreting tumors experience adrenal insufficiency in the postoperative period because of adrenocorticotrophic hormone (ACTH) suppression. Replacement therapy with hydrocortisone at stress concentrations is required and gradually weaned until there is recovery of the hypothalamo-adrenal-pituitary axis which may take many months or even years. Patients with bilateral disease have a lifelong need for glucocorticoid and mineralocorticoid replacement therapy. The urinary steroid profile should be checked during the first postoperative week in patients with functional tumors. Hormones typically return to normal within 7 days of complete tumor resection (2).

The application of mitotane in the management of ACT is uncertain. Up to 30% of patients with advanced disease have an objective response; however, this is usually transient and the overall effect on survival is unknown (5).

Mitotane accelerates the metabolic clearance of glucocorticoids, thyroid and parathyroid hormones so glucocorticoid and mineralocorticoid replacement therapy is required in all patients and many also require thyroid hormone supplementation (2).

The effect of chemotherapy on ACT in childhood has been less extensively studied. The usage of cisplatin alone can induce remission in up to 25% of patients

with advanced disease (6). Combination therapy of cisplatin with doxorubicin and cyclophosphamide or 5-fluorouracil increases remission rates to 20–40% (7,8). The use of mitotane in combination with etoposide-based chemotherapy is attractive to reduce the occurrence of multidrug resistance and improved remission rates of 63% have been reported when mitotane is combined with cisplatin, etoposide and doxorubicin (9).

In general, ACT is considered radio-resistant. The high prevalence of p53 gene mutations in these patients and associated with risk of secondary malignancies also makes it an unattractive therapy. A number of treated children with radiotherapy have been reported fatal secondary sarcoma (2). Once the child has entered remission they should enter a program of tumor surveillance with periodic clinical review, evaluation of urinary steroid excretion and imaging. Patients who have completed 5 years of tumor surveillance, they should continue under the care of the endocrinologist until adult life to ensure that growth and puberty progresses normally. Virilized girls with clitoromegaly may be best seen in a multidisciplinary service for children with disorders of sex development to enable their psychological, surgical and medical needs to be met (2).

Prognosis is closely related to the stage of the tumor at diagnosis, event-free survival at 5 years being 91% for children presenting with stage I disease and 53% for those with stage III disease (1). Very few children present with stage II or IV disease but the prognosis is extremely poor for these patients (2).

Conflict of interest

Authors have no conflict of interest.

References

1. Behrman, RE, Kliegman R, Jenson HB. Adrenocortical Tumors. Nelson Textbook of Pediatrics, 20th Edition. Philadelphia WB Saunders; 2015:2726-2727

2. Charles G. D. Brook, Peter E. Clayton, Rosalind S. Brown. Endocrine neoplasia in childhood. Brook's Clinical Pediatric Endocrinology, 6th Edition, UK, Wiley-Blackwell, 2009; 428-432.
3. Michalkiewicz E, Sandrini R, Figueiredo B, Miranda EC, Caran E, Oliveira-Filho AG, et al. Clinical and outcome characteristics of children with adrenocortical tumors: a report from the International Pediatric Adrenocortical Tumor Registry. J Clin Oncol 2004; 22: 838-845.
4. Dennedy MC, Smith D, O'shea D, McKenna TJ. Investigation of patients with atypical or severe hyperandrogenaemia including androgen-secreting ovarian teratoma. Eur J Endocrinol. 2010; 162(2):213-20.
5. Mayer SK, Oligny LL, Deal C, Yazbeck S, Gagné N, Blanchard H. Childhood adrenocortical tumors: case series and reevaluation of prognosis – a 24-year experience. J Pediatr Surg 1997; 32: 911–915.
6. Chun HG, Yagoda A, Kemeny N, Watson RC. Cisplatin for adrenal cortical carcinoma. Cancer Treat Rep 1983; 67: 513–514.
7. van Slooten H, van Oosterom AT. CAP (cyclophosphamide, doxorubicin and cisplatin) regimen in adrenal cortical carcinoma. Cancer Treat Rep 1983; 67: 377–379.
8. Schlumberger M, Brugieres L, Gicquel C, Travagli JP, Droz JP, Parmentier C. 5-Fluorouracil, doxorubicin and cisplatin as treatment for adrenal cortical carcinoma. Cancer 1991; 67: 2997–3000.
9. Zancanella P, Pianovski MA, Oliveira BH, Ferman S, Piovezan GC, Lichtvan LL, et al. Mitotane associated with cisplatin, etoposide and doxorubicin in advanced childhood adrenocortical carcinoma: mitotane monitoring and tumor regression. J Pediatr Hematol Oncol 2006; 28: 513–524

Table I: Differential diagnosis of clinical hyperandrogenism

Diagnosis	frequency	Age of onset years	Time onset of presentation	Menstrual disturbance	Virilization
PCOS and related disorders	>95	15 to 20	years	±	Rare
CAH	1 to 2	congenital	Birth/adolescence/adulthood	+	±
Adrenal tumor	<1	Any time	Weeks-months	+	+
Ovarian tumor	<1	Any time	Weeks-months	+	+
Cushing's syndrome	<1	Any time	Months- years	+	±
Hyperthecosis ovary	<1	Pre- to post-menopause	Months- years	+	+



Figure1. Acne on the face of the patient

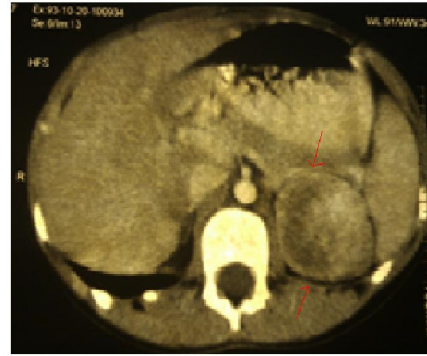


Figure2. Axial sections of contrast-enhanced CT, demonstrating a large heterogeneous mass in the left adrenal gland . The overall size of this mass was 55 mm.