

Langerhans cell histiocytosis of the clavicle in a 10-years-old girl

Shirin Sayyahfar MD^{1,*}, Shahla Ansari MD^{1,2}, Mahtab Rahbar MD^{1,3}, Elham Zarei MD^{1,4}

1. Department of Pediatrics, Division of Pediatric Infectious Diseases, Ali Asghar Children Hospital, Research Center of Pediatric Infectious diseases, Institute of Immunology and Infectious Diseases, Iran University of Medical Sciences, Tehran, Iran.

2. Department of Pediatrics, Division of Pediatric Hematology and Oncology, Ali Asghar Children Hospital, Iran University of Medical Sciences, Tehran, Iran.

3. Department of Pathology, Ali Asghar Children Hospital, Iran University of Medical Sciences, Tehran, Iran.

4. Department of Radiology, , Ali Asghar Children Hospital , Iran University of Medical Sciences, Tehran, Iran.

*Corresponding author: ShirinSayyahfar, MD, Department of Pediatrics, Iran University of Medical Sciences, Ali Asghar Children Hospital, VahidDastgerdi Street, Shariati Street, Tehran, Iran. Email: sayyahfar.sh@iums.ac.ir

Received: 30 July 2016

Accepted: 17 January 2017

Abstract

Langerhans cell histiocytosis (LCH) is an abnormal proliferation of Langerhans cells in one or more organs; bone is the most frequently involved organ in which the skull is the most frequent. The clavicle is rarely the primary site of the LCH, thereby the timely diagnosis is often delayed and most of the patients are primarily treated for acute or chronic osteomyelitis. Herein we report a 10 years old girl with swelling and pain in the medial end of the left clavicle admitted in Aliasghar Children's Hospital in 2015 and final diagnosis of the LCH which was initially misdiagnosed as osteomyelitis. The LCH should be considered in the differential diagnosis of any lytic or destructive lesion of the clavicle for timely diagnosis and prevention of inappropriate treatment.

Clavicle; Histiocytosis, Langerhans cell histiocytosis, Osteomyelitis, Pediatrics

Keywords: Clavicle; Histiocytosis, Langerhans cell histiocytosis, Osteomyelitis, Pediatrics

Introduction

Langerhans cell histiocytosis (LCH) formerly known as eosinophilic granuloma, Letterer-Siwe disease, histiocytosis X, and Hand-Schuller-Christian disease is an abnormal proliferation of the tissue macrophages called Langerhans cells in one or more organs, including bone, skin, lymph nodes, lung, liver, spleen and bone marrow (1, 2). The LCH can present at any age from neonatal period to elderly; However it is more prevalent in 5-15 years old group with a slight more predominance in males (1, 3). Approximately 80% of the cases are under 15 years (4). The most frequent organ involved in this disease is the bone. The skull followed by femur, jaw, pelvis, ribs, spine, scapula, humerus, and sternum are the most frequent sites of the bone involvement. The estimated annual prevalence of this disease is 1-2 cases per

1 million in adults (5). Wester et al. reported 61 cases of LCH occurring in adults, with only 6% involving the clavicle (6). The minimum incidence of the LCH is estimated to 8.9 per 1 million in children per year (4). A solitary lesion in the clavicle is extremely rare (7), and only 12 cases have been reported up to 2015 (4). As far as the clavicle is rarely the primary site of the LCH (1), the correct diagnosis is usually delayed and most of the patients with the clavicular LCH are primarily treated for acute or chronic osteomyelitis. Herein we report a 10 years old girl with swelling and pain of the medial end of the left clavicle and final diagnosis of the LCH initially misdiagnosed as osteomyelitis. Informed consent was taken from her parents before case report.

Case report

A ten- years- old girl was referred to Aliasghar Children's Hospital in 2015 due to pain and swelling over the left medial end of the clavicle for 3 months. There was no history of trauma in this region.

She had no fever, chills or night sweats but weight loss of nearly 5 Kg during this period of time. The general condition was good and the physical examination was unremarkable except swelling and local tenderness of the proximal site of the left clavicle that did not limit the range of motion of the left shoulder. There was no erythema or warmth of the overlying skin. No cervical, axillary, or supraclavicular lymphadenopathy was found. Laboratory data was as follows: white blood cell (WBC), $6.4 \times 10^3/\text{mm}^3$ (neutrophil 64%, lymphocyte 34%, band 1%, eosinophil 1%), hemoglobin (Hb), 11.6 g/dl, Platelet $407 \times 10^3/\text{mm}^3$, erythrocyte sedimentation rate (ESR), 81mm/hr, CRP 6.4mg/L (Normal <10 mg/L), Lactate dehydrogenase (LDH), 500IU/L (up to 480), Ferritin 46.8 (10- 90 ng/ml). Routine liver and kidney function test results were within normal limits. Tuberculin skin test, wright and coombs wright test were also negative.

In the primary evaluation, chest x-ray (plain radiograph) revealed an expansile lytic lesion in the medial end of the left clavicle (Figure1) which led the physician to obtain computed tomography (CT) which confirmed the lesion (Figure2) and suggested the differential diagnoses of an infiltrative lesion, osteomyelitis or extra pulmonary tuberculosis. She was admitted and underwent bone biopsy from the lytic lesion of the clavicle.

Treatment with clindamycin was started for primary diagnosis of osteomyelitis after performing the bone biopsy. Bone survey revealed a lytic lesion and was otherwise normal. Technetium 99m-methyl diphosphonate (Tc-99mMDP) bone scan was performed which documented intense focus of radioisotope accumulation within the left medial end of the clavicle.

Polymerase chain reaction (PCR) analysis of the bone specimen for mycobacterium tuberculosis was negative. Histopathologic examination revealed Langerhans cells with pale eosinophilic cytoplasm, irregular and elongated nuclei with prominent nuclear grooves, fine chromatin and indistinct nucleoli (Figure3). Immunohistochemical staining of the bone specimen was positive for CD1a and S100. According to the result of the bone biopsy she was treated for the clavicular LCH with chemotherapy. One year follow up revealed no local recurrence or distant metastasis

Discussion

Clavicle is a bone with unique characteristics. It is the first bone which ossifies in the embryonic time and the only long bone with anatomical position of horizontal axis. Moreover, it is a long bone with oncological characteristics of flat bones (8). As it is located subcutaneously throughout its length, any deformity or swelling of this bone is early revealed (8).

The most common causes of non-traumatic lesions of clavicle are neoplasm, infection, auto-inflammatory disorders (e.g. chronic recurrent multifocal osteomyelitis) and developmental abnormalities (1, 9, 10)

Although extremely rare, tubercular osteomyelitis of the clavicle should be considered in differential diagnosis of clavicular lesions, especially in endemic regions (11). Other infectious causes include pyogenic osteomyelitis and brucellosis.

Our patient was firstly diagnosed as a case of pyogenic osteomyelitis that was ruled out with the result of bone biopsy evaluation. Since she lived in one of the provinces of Iran in which tuberculosis is endemic, we performed PCR on biopsy specimen to rule out this diagnosis.

Although the incidence of clavicular tumors is only 0.45–1 % of all bone tumors; the majority are malignant and delay in diagnosis might be dangerous (8).

Open incisional biopsy is recommended to diagnose the etiology of the clavicular lesions, because needle biopsy may cause injury to the neurovascular structures that are in close relation with this bone (8).

There are various reports about the histological type of the most prevalent tumors of the clavicle in the literature such as myeloma, osteosarcoma, and, Ewing's sarcoma (8, 12, 13) but there is not an exact rate of the LCH originated from or involved the clavicle.

The real incidence of LCH is not defined exactly and may vary according to ethnicity (3), but it is estimated to be 1–2 cases per 1 million of the population (4). The Majority of LCH are solitary lesions (1), as our case that had a solitary lesion in the medial end of her left clavicle.

The primary and definite diagnosis of LCH is based on morphologic identification of characteristic the LCH cells and staining of the lesional cells with

CD1a and/or Langerin (CD207), respectively (3). It is recommended to perform a bone scan to detect other sites of the disease (1).

The LCH mostly involves the bones which may be painful or painless. The most common bone involved is skull. Skin lesions often papulosquamous, soft tissue swelling, mainly in proximity to bony lesions, external ear drainage, enlargement of lymph nodes and thymus, and gum hypertrophy with premature eruption of the teeth, are other major clinical manifestations of the disease. Disseminated form of the LCH named Letterer-Siwe disease most often involves young infants and accompanies with more systemic involvement including fever, hepatosplenomegaly, liver dysfunction, hematopoietic failure and intestinal involvement (3).

Clinicians should be aware and consider LCH in the differential diagnosis of any lytic or destructive lesion of the clavicle for timely diagnosis and prevent inappropriate treatment (8).

Conflict of interest

Authors have no conflict of interest.

References

1. Parikh SN, Desai VR, Gupta A, Anton CG. Langerhans cell histiocytosis of the clavicle in a 13-year-old boy. *Case Rep Orthop* 2014; 2014:510287.
2. Henry RJ, Sweeney EA. Langerhans' cell histiocytosis: case reports and literature review. *Pediatr Dent* 1996; 18(1):11-6.
3. Filipovich A, McClain K, Grom A. Histiocytic disorders: Recent insights into pathophysiology and practical guidelines. *Biol Blood Marrow Transplant* 2010; 16: S82-S89.
4. Udaka T, Susa M, Kikuta K, Nishimoto K, Horiuchi K, Sasaki A, et al. Langerhans Cell Histiocytosis of the Clavicle in an Adult: A Case Report and Review of the Literature. *Case Rep Oncol* 2015; 8(3):426–431.
5. Stålemark H, Laurencikas E, Karis J, Gavhed D, Fadeel B, Henter JI. Incidence of Langerhans cell histiocytosis in children: a population-based study. *Pediatr Blood Cancer* 2008 Jul; 51(1):76-81.
6. Wester SM, Beabout JW, Unni KK, Dahlin DC. Langerhans' cell granulomatosis (histiocytosis X) of bone in adults. *Am J Surg Pathol* 1982; 6(5):413–426.
7. Wang S, Zhang W, Na S, Zhang L, Lang Z. Langerhans cell histiocytosis of the clavicle: a case report and review of the literature. *Medicine (Baltimore)* 2014; 93(20):e117.
8. Kapoor S, Tiwari A, Kapoor S. Primary tumours and tumorous lesions of clavicle. *Int Orthop* 2008; 32(6):829-34.
9. McCarville M B. The child with bone pain: malignancies and mimickers. *Cancer Imaging* 2009; 9: S115-S121.
10. Ren K, Wu S, Shi X, Zhao J, Liu X. Primary clavicle tumors and tumorous lesions: a review of 206 cases in East Asia.

Arch Orthop Trauma Surg 2012; 132(6):883-9.

11. Aggarwal AN, Dhammi IK, Singh AP, Kumar S, Goyal MK. Tubercular osteomyelitis of the clavicle: a report of four cases. J Orthop Surg (Hong Kong) 2009; 17(1):123-6.

12. Pratt GF, Dahlin DC, Ghormley RJ .Tumors of scapula and clavicle .Surg Gynecol Obstet 1958; 106(5):536-44.

13. Smith J, Yuppa F, Watson RC .Primary tumors and tumor-like lesions of the clavicle. Skeletal Radiol 1988; 17(4):235-46.

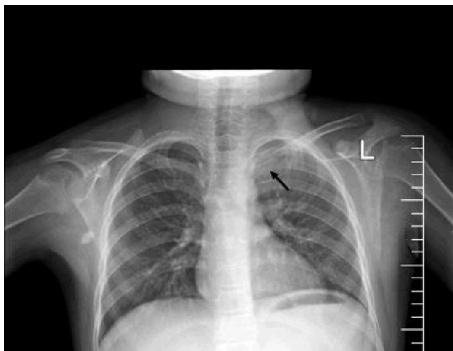


Figure1. Postero-anterior view of CXR showing medial end of the left clavicle destroyed.

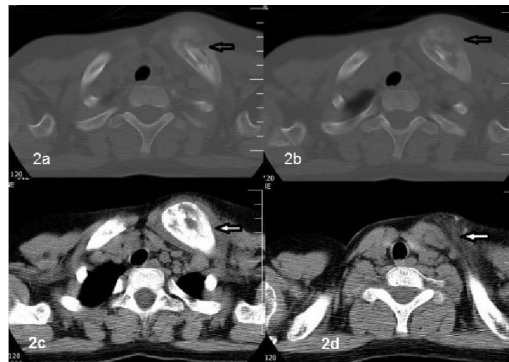


Figure2. Computer tomographic scans; 2a and 2b show ill-defined lytic lesion with cortical disruption and periosteal reaction in medial end of left clavicle; 2c and 2d show a small soft tissue component and mild fat stranding adjacent to the bone lesion.

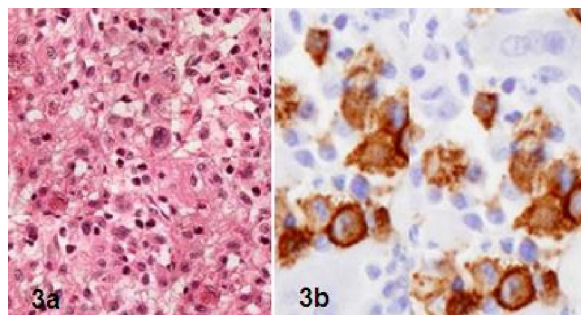


Figure3. Histopathologic examination; 3a Langerhans cells with pale eosinophilic cytoplasm, irregular and elongated nuclei with prominent nuclear grooves and giant cell, fine chromatin and indistinct nucleoli (H&E x400); 3b: Langerhans cells histiocytosis with positive cytoplasmic stain for CD1a(x400).