

Bone marrow and cervical lymph nodes metastases as prodromal manifestations of malignant melanoma in a child

Fariba Binesh MD^{1*}, Alireza Jenabzadeh MD², Maryam Vagihinejad MD¹, Mohammad Ali Dideban BSc¹, Fatemeh PourHosseini MSc¹, Hadi Zare-Zardini MSc^{3,*}

1. Department of Pathology, Shahid Sadoughi University of Medical Sciences, Yazd, Iran

2. Department of pediatric oncology, Shahid Sadoughi University of Medical Sciences, Yazd, Iran

3. Hematology and oncology research center, Shahid Sadoughi University of Medical Sciences, Yazd, Iran

*Corresponding author: Hadi ZareZardini, MSc, Hematology and Oncology Research Center, Shahid Sadoughi University of Medical Sciences, Yazd, Iran. Email: hadizarezardini@gmail.com

Received: 04 February 2017

Accepted: 22 August 2017

Abstract

Malignant melanoma in children is rare. It can arise from congenital melanocytic nevi. In pediatric patients, diagnosis of melanoma is difficult and challenging because the physicians have a low index of suspicion. Marrow metastasis in malignant melanoma especially in children is extremely uncommon. Here, the authors reported a 5 year old girl who was presented with a 4 month history of pelvic and right lower limb pain and limping to the pediatric outpatient clinic in August 2016 at Shahid sadoughi Hospital, Yazd, Iran. She was febrile and had right cervical lymphadenopathy and scalp congenital nevus. The investigations confirmed the diagnosis of malignant melanoma with marrow and cervical lymph node metastases. The patient underwent multidisciplinary management and she was followed up closely.

Metastatic malignant melanoma is a rare and dangerous disease with poor prognosis in children. It should be considered in differential diagnosis of children with congenital melanocytic nevi.

Key words: Malignant melanoma, Bone marrow, Metastasis, Child

Introduction

Malignant melanoma in children accounts for 1% to 4% of all cases of melanoma and for 1% to 3% of all children malignant tumors (1). Pediatric melanoma is divided into congenital, infantile, childhood, and adolescent groups. It can arise from congenital melanocytic nevi. The risk for development of melanoma in a congenital nevus increases with its size (2). According to one study, large congenital melanocytic nevi were found in 33% of children with malignant melanomas (3). Malignant melanoma with widespread metastases, including bone marrow metastasis is extremely rare in children. To the best of our knowledge, there are only a few cases of malignant melanoma metastasizing to the bone marrow in children (4). In the Iranian literature, there is no previously reported case of malignant melanoma with widespread metastases as an initial manifestation in children. Here,

the authors reported a rare case of a 5-year-old girl with a scalp congenital melanocytic nevus who was presented with malignant melanoma metastasizing to bone marrow and cervical lymph nodes as a prodromal manifestation.

Case report

A 5-year-old girl, referred to the pediatric outpatient clinic in August 2016 at Shahid sadoughi Hospital, Yazd, Iran, with complaint of a 4 month history of pain in the right lower limb and limping. The pain did not disturb her sleep and responded to analgesic drugs and rest. Her parents also noticed fever and enlargement of her right cervical lymph nodes. On physical examination, the girl was febrile on admission. A congenital nevus was found on the patient's scalp and her right cervical lymph nodes were palpable. The diameter of the nevus was about 7 centimeters. According to her mother, the nevus had

not changed in size or appearance. Neurological examination revealed mild neck stiffness. Laboratory investigations found normal white blood cell count ($5 \times 10^9/L$) a hemoglobin level of 8.3g/dl and normal platelet count ($176 \times 10^9/L$). ESR (erythrocyte sedimentation rate) was 127 mm/h, but CRP (C reactive protein) was negative. Biochemistry tests revealed calcium level of 11.3 mg/dl. Serology results showed positive anti CMV (cytomegalovirus) IgM antibody. Lumbar puncture results were unremarkable. No pathology was found on x-ray of the chest. Thoracic and abdominal CT scans revealed several lytic and expansile lesions in thoracic vertebrae, ribs, humerus, scapula, lumbar vertebrae, pelvic bone, and femur. Ultrasound examination of the neck confirmed the previous finding of enlarged lymph nodes in the right side. Abdominal ultrasound showed mesenteric lymphadenopathy with malignant features. Subsequently, bone marrow aspiration was performed. Smears showed bone marrow infiltration with atypical cells with irregular nuclei, ample cytoplasm with many vacuoles (Figure 1-A). Immunophenotyping (flow cytometry) for usual lymphoid and myeloid markers were negative. Since bone marrow aspiration was not diagnostic and we could not rule out metastatic tumor, cervical lymph node biopsy was done. The resected lymph nodes were black. Sections showed diffuse infiltration of the lymph node by a population of large pleomorphic tumor cells with large nuclei and their cytoplasm was full of black pigment. The cells expressed vimentin, S100 protein and HMB45 (Figure 1B,C). It confirmed the diagnosis of metastatic malignant melanoma. The girl was referred to pediatric oncology department. After completion of the initial work-up, the final diagnosis was malignant melanoma with metastatic spread to the lymph nodes, bone marrow, bone, and leptomeninge. The patient underwent multidisciplinary

management and we followed up her closely.

Discussion

Malignant melanoma is rare in children. The exact incidence of subtypes of pediatric melanoma is obscure. Children melanoma occurs in both genders; however, in adolescents it is more frequent in girls, but in children, somewhat more in boys (5). It seems pediatric melanoma is more frequent in the second decade of life. The clinical manifestation of children with melanoma is heterogeneous. One study showed that 8 of 443 patients developed melanoma on congenital nevi (6). Presentation of pediatric melanoma with widespread metastases, including marrow involvement is rare (7). Jana Volejnikova described a case of malignant melanoma arising in a large congenital melanocytic nevus with spreading to the bone marrow in a 5-year-old boy. Histologic diagnosis of melanoma can be difficult in children. Advanced stage at the time of diagnosis is an ominous sign, as in adult cases. There is very limited information on the best therapy of metastatic melanoma in pediatrics. Although surgery is the cornerstone therapy, excellent improvement has been made in the field of immunotherapy. It may gradually substitute chemotherapy. Survival of patient with malignant melanoma in childhood depends on the tumor stage. In a study conducted by Lacoste et al., the mortality rate was about 60% (8). However, in children with metastatic disease, a reported 5-year survival dropped to 30% (9). A multidisciplinary approach is needed. As malignant melanoma is very scarce in children, high level of suspicion is necessary to make a timely and correct diagnosis.

Acknowledgments

The authors are indebted to the staff of the Pathology Unit at Shahid Sadoughi

Hospital in Yazd, Iran, for their cooperation during this study.

Conflicts of interest

The authors confirm that there are no known conflicts of interest associated with this publication and there has been no significant financial support for this work that could have influenced its outcome.

References

1. Downard CD, Rapkin LB, Gow KW. Melanoma in children and adolescents. *Surg Oncol*. 2007;16(3):215-220.
2. Fishman C, Mihm MC Jr, Sober AJ. Diagnosis and management of nevi and cutaneous melanoma in infants and children. *Clin Dermatol*. 2002; 20(1):44-50
3. Trozak DJ, Rowland WD, Hu F. Metastatic malignant melanoma in prepubertal children. *Pediatrics* 1975;55(2):191-204
4. Jana Volejnikova, Viera Bajciova, Lucie Sulovska, Marie Geierova, Eva Buriankova, Marie Jarosova, et al. Bone marrow metastasis of malignant melanoma in childhood arising within a congenital melanocytic nevus. *Biomed Pap Med Fac Univ Palacky Olomouc Czech Repub* 2016; 160:XX.
5. Moore-Olufemi S, Herzog C, Warneke C, Gershenwald JE, Mansfield P, Ross M, et al. Outcomes in pediatric melanoma: comparing prepubertal to adolescent pediatric patients. *Ann Surg* 2011; 253: 1211–1215.
6. Brecht IB, Garbe C, Gefeller O, Pfahlberg A, Bauer J, Eigentler TK, et al. 443 paediatric cases of malignant melanoma registered with the German Central Malignant Melanoma Registry between 1983 and 2011. *Eur J Cancer* 2015;51(7):861-
7. Neuhold JC, Friesenhahn J, Gerdes N, Krenkel S. Case reports of fatal or metastasizing melanoma in children and adolescents: a systematic analysis of the literature. *Pediatr Dermatol* 2015;32(1):13-22
8. Lacoste C, Avril MF, Frassati-Biaggi A, Dupin N, Chrétien-Marquet B, Mahé E, Bodemer C, Vergier B, et al. Malignant melanoma arising in patients with a large congenital melanocytic naevus: retrospective study of 10 cases with cytogenetic analysis. *Acta Derm Venereol* 2015;95(6):686-90
9. Anne Kristine Larsen, Mette Bybjerg Jensen, Christen Krag. Long-term Survival after Metastatic Childhood Melanoma. *Plast Reconstr Surg Glob Open*. 2014 Jun; 2(6): e163.

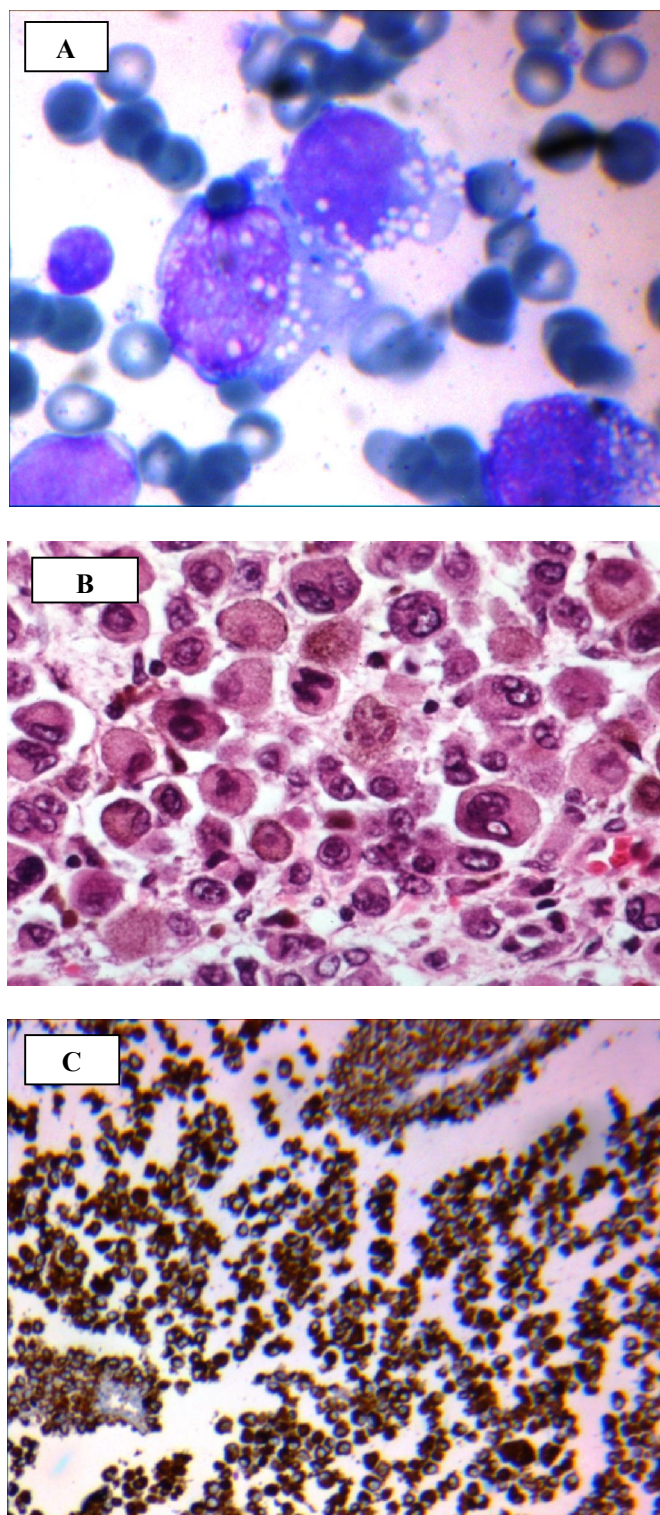


Figure1. A:Bone marrow aspiration smear, B: Cervical lymph node, C :HMB45 stain.