

The efficacy of the aqueous extracts of *Anethum graveolens*, *Urtica dioica*, and *Silybum marianum* on the liver function in iron overloaded rats

Mahbubeh Hosseini MSc², Durdi Qujeq PhD^{2,3,4,5}, Ahmad Tamaddoni MD^{6,7,8,9,*}, Mohammad Ranaee MD^{10,11}, Karimollah Hajian-Tilaki PhD^{12,13}

1. Student Research Committee, Babol University of Medical Sciences, Babol, Iran
 2. Department of Clinical Biochemistry, School of Medicine, Babol University of Medical Sciences, Babol, Iran
 3. Cellular and Molecular Biology Research Center, Health Research Institute, Babol University of Medical Sciences, Babol, Iran
 4. Dental Materials Research Center, Institute of Health, Babol University of Medical Sciences, Babol, Iran
 5. Cancer Research Center, Health Research Institute, Babol University of Medical Sciences, Babol, Iran
 6. Non-Communicable Pediatric Disease Research Center, Health Research Institute, Babol University of Medical Sciences, Babol, Iran
 7. Cancer Research Center, Health Research Institute, Babol University of Medical Sciences, Babol, Iran
 8. Clinical Research Development Center, Amircola Children's Hospital, Babol University of Medical Sciences, Babol, Iran
 9. Department of Pediatrics, School of Medicine, Babol University of Medical Sciences, Babol, Iran
 10. Department of Pathology, School of Medicine, Babol University of Medical Sciences, Babol, Iran
 11. Clinical Research Development Unit of Rouhani Hospital, Babol University of Medical Sciences, Babol, Iran
 12. Environmental Health Research Center, Health Research Institute, Babol University of Medical Sciences, Babol, Iran
 13. Department of Statistic and Epidemiology, School of Medicine, Babol University of Medical Sciences, Babol, Iran
- *Corresponding author: Ahmad Tamaddoni, MD, Department of Pediatrics, School of Medicine, Babol University of Medical Sciences, Babol, Iran. Email: drtamaddoni@yahoo.com.

Received: 06 July 2018

Accepted: 24 August 2018

Abstract

Background: This study aimed to compare the effect of the aqueous extracts of *Anethum graveolens*, *Urtica dioica*, and *Silybum marianum* with deferoxamine (DFO) on iron-overloaded rats.

Materials and Methods: In this case control study, fresh leaves of *Anethum graveolens* and *Urtica dioica* as well as seeds of *Silybum marianum* were washed with water and rinsed with deionized water to remove possible pesticide and preservative residue. Forty eight male rats were randomly divided into six groups: negative control, positive control (iron overload), *Anethum graveolens* group, *Urtica dioica* group, *Silybum marianum* group, and DFO group. Iron dextran was injected intraperitoneally (i.p.) at 50 mg/kg body weight for 12 weeks (once a week) to establish the iron overload condition. While normal rats received normal saline, rats in the treated groups orally received three plant extracts and DFO (subcutaneously) weekly for 8 weeks (once a week). At the end of the experiment, changes in alanine aminotransferase (ALT) and aspartate aminotransferase (AST) activity were measured using AST and ALT kits from Zist Chem Diagnostics Co. (Tehran, Iran) and histological changes were observed by hematoxylin and eosin staining of the liver.

Results: Iron overloaded rats showed a slightly increase in the serum ALT and AST activity compared to control group (4.97 ± 0.12 , 60.79 ± 1.16 vs. 3.92 ± 0.10 , 50.24 ± 0.82 U/L, respectively) (p value < 0.05). However, relative to iron overloaded rats, treatment with *Anethum graveolens*, *Urtica dioica*, and *Silybum marianum* extracts and DFO significantly decreased the activity of ALT and AST (ALT: activity (4.37 ± 0.08 , 4.58 ± 0.06 , 4.74 ± 0.09 and 3.96 ± 0.15 U/L, respectively); (AST: 53.68 ± 1.24 , 55.78 ± 1.03 , 57.87 ± 1.15 and 51.65 ± 0.66 U/L, respectively) (p value < 0.05). Treatment of iron overloaded rats with *Anethum graveolens*, *Urtica dioica*, and *Silybum marianum* also significantly improved the liver dysfunction.

Conclusion: *Anethum graveolens*, *Urtica dioica*, and *Silybum marianum* may be potential medicinal herbs which can reduce liver damage caused by iron overload.

Keywords: *Anethum graveolens*, *Deferoxamine*, Iron-overloaded, *Silybum marianum*, *Urtica dioica*,

Introduction

It is believed that iron contributes to the metabolisms of the body. Researchers reported that treatment with ferulic acid in iron overloaded animals can diminish liver damage (1). Previous studies suggested that Taurine, a potent free radical scavenger, can reduce the hepatotoxicity of iron overload regarding the ROS production (2). It is a well-established concept that iron scavenger can be used as a powerful treatment to balance iron status (3). Liver iron content is mainly associated with mean serum corpuscular hemoglobin (4). In general, iron accumulates in liver in various chronic liver diseases (5). There is much evidences suggesting that iron overload induces severe damage to several vital organs such as the liver (6). The recent evidence has highlighted that the excessive iron gets deposited in vital organs and leads to dysfunction of the liver. Changes in iron metabolism in body have long been associated with some complications, because our body has limited capacity to excrete iron, so patients with iron overload and its complications need effective iron chelation therapy (7). It is important to emphasize that the herbs are not important iron sources in human nutrition (8). Stinging nettle (*Urtica dioica* L.) is used as a source of fiber and alternative medicine (9). It is known that *Silybum marianum* L. (milk thistle) is used as a medicinal herb for the treatment of liver disease (10). Recent data demonstrated that iron overload may cause many complications in patients. Silymarin plays an important role in the treatment of the disease (11). Evidence revealed that Silymarin is a flavonoid complex isolated from *Silybum marianum* with a strong antioxidant activity, inducing a hepato-protective action, and probably, a protective effect on iron overload (12). Chromatographic analysis showed that the extract of *Anethum graveolens* L. (dill) contains rosmarinic acid as the major phenolic acid (13). The aim of this study was to determine the effect of *Anethum*

graveolens, *Urtica dioica*, and *Silybum marianum* extracts on improving iron chelation in iron overload rats treated with iron dextran.

Materials and Methods

All solvents and reagents used in this study were measurable. Transaminase enzyme (ALT/GPT, AST/GOT) kit was purchased from Zist Chem Co (Tehran, Iran).

Aqueous extraction of plant

The leaves of *A. graveolens* and *Urtica dioica* as well as seeds of *Urtica dioica*, and *Silybum marianum* were dried at room temperature for 10 days, finally powdered, and used for extraction. The powder (20 g) of *A. graveolens*, *Urtica dioica*, and *Silybum marianum* seeds was separately mixed with 550, 800, and 440 ml distilled water using a shaker for 24 hours, then the process was repeated with the precipitated pellet. The sediments were filtered and collected. All samples of the extract were stored at -4°C for further analysis.

Experimental treatments

Forty-eight male rats weighing 185-195 g were purchased from the Experimental Animal Center, Babol Medical University. Rats were housed in cages under controlled temperatures and 12 h light-dark cycle. They received normal chow and drinking water ad libitum. All rats were taken care in this study in accordance with the Guidelines of Animal. The use of animals was reviewed and approved by the Babol University of Medical Sciences University Animal Care Review Committee. After one week of acclimation, the rats were divided into six groups: (1) negative control group (normal), (2) positive control group (iron overload group), (3) iron-dextran plus *A. graveolens* extract, (4) iron-dextran plus *Urtica dioica* extract, (5) iron-dextran plus *Silybum marianum* extract group, (6) iron dextran plus DFO group (50mg/ kg/1day). Rats of the latter five groups were injected intraperitoneally (i.p.) with iron dextran at 100 mg/kg/1day over the 12-week

experimental period and had free access to normal rats chow and drinking water. Correspondingly, rats of the normal group received (i.p.) injection with isovolumic normal saline and were maintained on normal chow and drinking water ad libitum. To test the treatments (groups 3, 4, 5, and 6), the rats were given *Anethum graveolens*, *Urtica dioica*, and *Silybum marianum* orally at dose of 50mg/kg/day for 8 weeks (once a week), respectively. Likewise, the rats in the DFO group were injected subcutaneously at the dosage of 50 mg/kg/day. Food intake and activities of all rats were observed carefully every day. The entire experimental period lasted for 21 weeks. At the end of the experiment, the final bodyweight of each rat was recorded, and then the rats were anesthetized with diethyl ether (50mg/kg) and blood was collected from their eyes (venous pool) by standard venous puncture with glass capillary tubes in dry, clean, and screw capped tubes and left to clot. The liver tissue was quickly removed and weighed for further analysis (15, 16).

Sample Collection

Rats were fasted overnight after the experiment ended on the 21st week. They were anesthetized with diethyl ether and blood was collected. Sera were separated using centrifuge (3000 × g for 10 min).

Tissue Preparation

The liver and pancreas samples were rapidly removed and weighed, then washed with cold normal saline to clean the blood cells, then blotted on filter study, and processed separately for histological study.

Histopathological Analysis

A paraffin-embedding technique was carried out and the sections were cut into 5 μm thickness, stained with hematoxylin and eosin, and examined microscopically for histopathological changes.

All procedures involving animals were carried out according to the guidelines for care and use of experimental animals. This study was approved by the Ethics

Committee for Research of Babol University of Medical Sciences (MUBABOL.HRI.REC. 1395.38 -3031).

Determination of aspartate transaminase (AST) and alanine transaminase (ALT) activity

The enzymatic activities of aminotransferases, including alanine aminotransferase (ALT) and aspartate aminotransferase (AST) in serum samples were estimated, using single-beam ultraviolet (UV)/visible spectrophotometer (UNICO) with commercial kits. The reagents were supplied by Zist Chem Diagnostics Co (Tehran, Iran). The assay and the outcomes of assaying biochemical markers used here have been typically validated against other methods and had good inter- and intra-assay coefficients of variation (14-16).

Statistical analysis

Results were expressed as mean ± standard deviation (SD) in the study. The data were statistically analyzed using SPSS (version 16) and running descriptive statistics.

Results

There were significant increases in serum iron level in iron overloaded group compared to normal control group (229.0±85.5 vs. 131.9± 6.85). Moreover, there was a significant increase in serum ALT and AST activity in iron overloaded group compared to normal control group (4.97±0.12, 60.79±1.16 vs. 3.92±0.10, 50.24±0.82 U/L, respectively). Following treatment with aqueous extracts of *Anethum graveolens*, *Urtica dioica*, *Silybum marianum*, and DFO (50mg/kg/day, respectively), a significant reduction in ALT activity (4.37 ±0.08, 4.58±0.06, 4.74 ±0.09 and 3.96 ±0.015 U/L, respectively) and AST activity (53.68±1.24, 55.78±1.03, 57.87±1.15 and 51.65 ±0.66 U/L, respectively) was observed (both at $p < 0.001$), indicating positive effects of aqueous extracts on iron overload rats (Figure 1 & 2).

Body weight

The mean body weight of iron overloaded rats was significantly lower than the normal group at the end of the 21-week experiment (163.7 vs. 195.8 gr) (p value < 0.05). However, their body weight was improved by receiving *Anethum graveolens*, *Urtica dioica*, and *Silybum marianum* extracts compared to iron overloaded group (183.2, 177.9, 172.4, 181.6 vs. 163.7 gr), with the most potent effect observed in the *Anethum graveolens* group.

Morphological changes of the liver observed by H & E staining

Observation of H & E stained liver sections under an optical microscope showed no significant difference in the hepatocellular plates of the normal group except vascular hyperemia. In liver tissue of iron overloaded rats, there were periportal and parenchymal inflammation, central vein hyperemia, increased number of brown pigments surrounding the port, and focal necrosis in liver parenchymal tissues. The results of H & E staining of rat liver tissues treated with the aqueous extract of *Anethum graveolens* indicated that vascular hyperemia, inflammation, and brown pigments surrounding the port were less than DFO group. Additionally, there were vascular hyperemia, inflammation, and brown pigments surrounding the port in H & E staining of rat liver in group treated with aqueous extract of *Silybum marianum*. In addition, there was pigmentation in paranchym in the group that received *Urtica dioica* extract. These two groups had less therapeutic effects than DFO group. The result of H & E staining indicated that periportal inflammation and genesis of brown pigments occurred in the rats that received DFO as well, but less severe than those found in iron overloaded rats.

Results of histopathological study of liver suggested that treatment with aqueous extracts of *Anethum graveolens*, *Urtica dioica*, *Silybum marianum*, and DFO can reduce the iron pigmentation,

pleomorphism, vaculation, fibrosis, disarrangement, and degeneration of hepatocytes compared to iron overloaded group (Figure 3).

Morphological changes of the pancreas observed by H & E staining:

Observation of H & E stained pancreas sections under an optical microscope showed a vital vascular hyperemia and no pigment in normal group. Iron overloaded rats showed brown pigments surrounding the blood vascular, ducts, and parenchymal. In this group, no pigmentation in Islets of Langerhans and marked atrophy were observed. The results of H & E staining of pancreas tissues of rats treated with *Anethum graveolens* and *Silybum marianum* extracts indicated vascular hyperemia and pigments less than the group that received DFO. In pancreas tissue of rats treated with *Urtica dioica* extract had perivascular and parenchymal pigmentation more than other plants. The pancreas of rats that received DFO had vascular hyperemia, pigments surrounding the blood vascular, ducts, and parenchymal less than iron overload group (Figure 4).

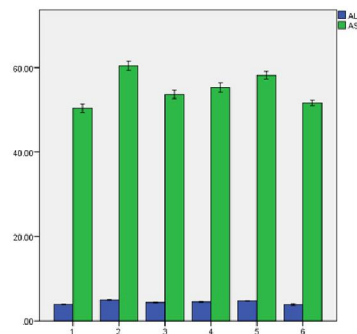


Figure 1. Effect of *Anethum graveolens*, *Urtica dioica*, milk thistle extracts on the serum activity of ALT and AST in iron-overloaded rats. Data are expressed as the mean \pm the standard deviation of the mean ($n = 8$). Samples were obtained from the: (1) negative control group, (2) positive control group (iron overload group), (3) iron-dextran plus *A. graveolens* extract, (4) iron-dextran plus *Urtica dioica* extract, (5) iron-dextran plus milk thistle extract group and (6) iron-dextran plus DFO group (50mg/ kg/1day). ALT, alanine transaminase; AST, aspartate transaminase. $P < 0.001$ compared with control.

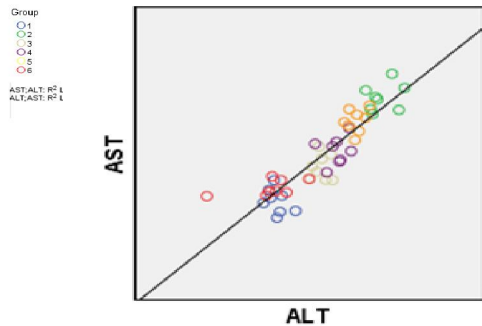


Figure 2. The correlation of mean value of ALT and AST serum levels in iron overload rats in different treated groups. (1)negative control group, (2)positive control group (iron overload group), (3)iron-dextran plus A.graveolens extract, (4)iron-dextran plus Urticadioica extract, (5)iron-dextran plus milk thistle extract group and(6) iron-dextran plus DFO group(50mg/ kg/1day).

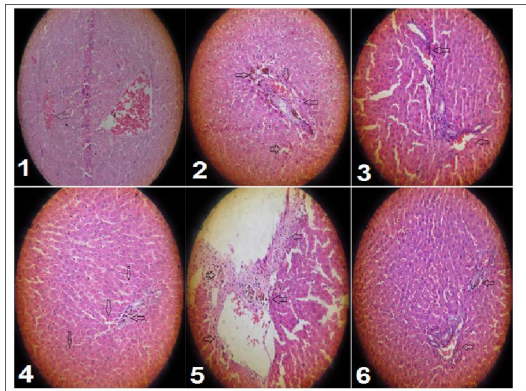


Figure 3. Morphological changes of the pancreas observed by H & E staining, (1)negative control group, (2)positive control group (iron overload group), (3)iron-dextran plus A.graveolens extract, (4)iron-dextran plus Urticadioica extract, (5)iron-dextran plus milk thistle extract group and(6) iron-dextran plus DFO group(50mg/ kg/1day).

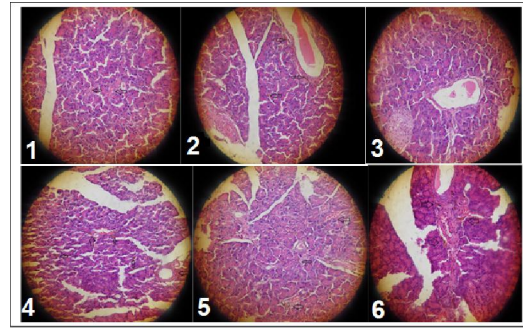


Figure 4. Morphological changes of the pancreas observed by H & E staining, (1)negative control group, (2)positive control group (iron overload group), (3)iron-dextran plus A.graveolens extract, (4)iron-dextran plus Urticadioica extract, (5)iron-dextran plus milk thistle extract group and(6) iron-dextran plus DFO group(50mg/ kg/1day).

Discussion

Iron overload plays a major role in liver injury. A feature of liver damage is the excessive death of hepatocytes, leading to the leakage of cellular enzymes into the blood stream, and subsequently resulting in increased activity of serum ALT and AST and loss of liver function. The AST and ALT activity in the serum are biomarkers for liver function. Early detection of liver dysfunction and rapid start of treatment are extremely important to interfere with its progression. Changes in liver function were assessed by the activities of ALT and AST, which significantly increased in iron overloaded rats, compared with the normal group. In the present study, the serum activities of AST and ALT in the rats were significantly increased following iron overload, suggesting an iron overload-related liver injury. DFO is currently used to remove excessive iron. However, its short half-life, burdensome, subcutaneous mode of administration, and propensity to cause neurotoxicity at high doses were greatly hindered its use. Thus, the main purpose is to use non-toxic and high-performance plants to reduce iron toxicity. We demonstrated that these three

plants improved the extra iron removal properties, and had a longer plasma retention time. Accordingly, it seems that they have better biocompatibility in the treatment of iron overload compared to DFO. Oral administration of *Anethum graveolens*, *Urtica dioica*, and *Silybum marianum* extracts significantly reduced the activity of serum enzymes of iron overloaded rats to approach the normal control values, suggesting protection by stabilizing the structural integrity of the liver cells. The protective effects of *Anethum graveolens*, *Urtica dioica*, and *Silybum marianum* extracts were also observed concurrent with the reduction in liver enzyme activity, suggesting the ability of these plant extracts to decrease the toxic effects of iron accompanied by increased pathological changes and iron deposition in the liver tissue (iron overload group). Najafzadeh et al., observed reduction serum and liver iron content, ALT and AST activities and necrotic rate of hepatocytes in rats treated with silymarin, also which is in line with this study. These effects may be attributed to chelating effect of *Silybum marianum* extract.

According to the results of this study, *Anethum graveolens*, *Urtica dioica*, and *Silybum marianum* extracts administration can significantly reduce iron deposition and repair liver dysfunction and histopathological changes in the liver of iron overloaded rats.

The effective role of extracts on serum of iron overloaded rats may be due to its iron scavenging and iron chelating activities. On the other hand, the protective effects of *Anethum graveolens*, *Urtica dioica*, and *Silybum marianum* extracts could be due to their antioxidant capability, because phenolic and flavonoids presented in this plants can readily form a resonance stabilized phenoxy radical, with potent free radical scavenging activity and can effectively scavenge excess iron which is a risk factor for liver damage. The iron chelating activity of *Urtica dioica* can be

attributed to their constituents, including phenolics, flavonoids, and terpenoids compounds that are plant secondary metabolites. Plant secondary metabolites act as protective constituents because they have properties such as metal chelation. These secondary metabolites are abundant in leaves of these plants. *Anethum graveolens* has phenolics and flavonoids such as flavonols, alkaloids, antocyanin, tannin, and saponin. Moreover, *Silybum marianum* is rich in silymarin as effective flavonoid.

Conclusively, *Anethum graveolens*, *Urtica dioica*, and *Silybum marianum* extracts can be used for the development of potential iron chelation in the treatment of iron overload-induced tissue toxicity.

The underlying mechanism remains unknown, further basic and clinical examinations are required to study the role of *Anethum graveolens*, *Urtica dioica*, and *Silybum marianum* in iron overload and their therapeutic potential. In the present study, those rats injected with iron exhibited significant symptoms of iron toxicity, including an increased serum activities of AST and ALT. This study demonstrated a significant protective effect of *Anethum graveolens*, *Urtica dioica*, and *Silybum marianum* on liver injury in iron overloaded rats, by reducing the iron distribution in the liver. These results provided preliminary experimental support for

Anethum graveolens, *Urtica dioica*, and *Silybum marianum* plants for iron overload condition. As *Anethum graveolens*, *Urtica dioica*, and *Silybum marianum* extracts have a complex chemical composition, further investigations are needed to better understand the protective mechanisms and interactions among the various constituents.

Conclusion

The results of the present study indicated that administration of *Anethum graveolens*, *Urtica dioica*, and *Silybum marianum* extracts have beneficial

effects on liver function, with significant reductions in ALT and AST enzyme activity. The results of the present study also demonstrated that *Anethum graveolens*, *Urtica dioica*, and *Silybum marianum* extracts can significantly restore abnormal liver function and improve the pathological changes of the liver due to iron overload. All these findings revealed a new pharmacological use of *Anethum graveolens*, *Urtica dioica*, and *Silybum marianum* extracts in decreasing the iron deposition. It is suggested to discover how these compounds show their activities in biological systems for their future development and application as iron chelator agents.

Acknowledgment

This work was financially supported by Babol University of Medical Sciences (No: 950214). The authors would also like to thank Mr. Shikhzadeh for technical assistance in sample preparation and handling of lab wares and animals in experimental procedures. The authors thank Dr. Evangeline Foronda for the final English editing.

References

1. Qiao Y, He H, Zhang Z, Liao Z, Yin D, Liu D, Yi B, He M. Long-Term Sodium Ferulate Supplementation Scavenges Oxygen Radicals and Reverses Liver Damage Induced by Iron Overloading. *Molecules*. 2016;21(9).
2. Zhang Z, Liu D, Yi B, Liao Z, Tang L, Yin D, He M. Taurine supplementation reduces oxidative stress and protects the liver in an iron-overload murine model. *Mol Med Rep*. 2014 Nov;10(5):2255-62.
3. Gelderman MP, Baek JH, Yalamanoglu A, Puglia M, Vallelia F, Burla B, Vostal J, Schaer DJ, Buehler PW. Reversal of hemochromatosis by apotransferrin in non-transfused and transfused Hbbth3/+ (heterozygous B1/B2 globin gene deletion) mice. *Haematologica*. 2015 May;100(5):611-22.
4. Kühn JP, Meffert P, Heske C, Kromrey ML, Schmidt CO, Mensel B, Völzke H, Lerch MM, Hernando D, Mayerle J, Reeder SB. Prevalence of Fatty Liver Disease and Hepatic Iron Overload in a Northeastern German Population by Using Quantitative MR Imaging. *Radiology*. 2017.
5. Mueller J, Raisi H, Rausch V, Peccerella T, Simons D, Ziener C, Schlemmer HP, Seitz HK, Waldburger N, Longerich T, Straub BK, Mueller S. Sensitive and non-invasive assessment of hepatocellular iron using a novel room-temperature susceptometer. *J Hepatol*. 2017 May 5. S0168-8278(17)32000-7.
6. Yang F, Li Y, Yan G, Liu T, Feng C, Gong R, Yuan Y, Ding F, Zhang L, Idiatullina E, Pavlov V, Han Z, Ma W, Huang Q, Yu Y, Bao Z, Wang X, Hua B, Du Z, Cai B, Yang L. Inhibition of iron overload-induced apoptosis and necrosis of bone marrow mesenchymal stem cells by melatonin. *Oncotarget*. 2017;8(19):31626-31637.
7. Jaiswal S, Hishikar R, Khandwal O, Agarwal M¹, Joshi U, Halwai A, Maheshwari B, Sheohare R. Efficacy of Deferasirox as an Oral Iron Chelator in Paediatric Thalassaemia Patients. *J Clin Diagn Res*. 2017;11(2):FC01-FC03.
8. Suliburska J, Kaczmarek K. Herbal infusions as a source of calcium, magnesium, iron, zinc and copper in human nutrition. *Int J Food Sci Nutr*. 2012 Mar;63(2):194-8.
9. Rutto LK, Xu Y, Ramirez E, Brandt M. Mineral Properties and Dietary Value of Raw and Processed Stinging Nettle (*Urtica dioica* L.). *Int J Food Sci*. 2013;2013:857120.
10. Yaldiz G. Effects of Potassium Sulfate [K₂SO₄] on The Element Contents, Polyphenol Content, Antioxidant and Antimicrobial Activities of Milk Thistle [*Silybum marianum*]. *Pharmacogn Mag*. 2017 Jan-Mar;13(49):102-107.
11. Darvishi Khezri H, Salehifar E, Kosaryan M, Aliasgharian A, Jalali

- H, HadianAmreeA. Potential Effects of Silymarin and Its Flavonolignan Components in Patients with β -Thalassemia Major: A Comprehensive Review in 2015. *AdvPharmacol Sci*. 2016;2016:3046373.
12. Hagag AA, Elfrargy MS, Gazar RA, El-Lateef AE. Therapeutic value of combined therapy with deferasirox and silymarin on iron overload in children with Beta thalassemia. *Mediterr J Hematol Infect Dis*. 2013 Nov 4;5(1):e2013065.
13. Orhan IE, Senol FS, Ozturk N, Celik SA, Pulur A, KanY. Phytochemical contents and enzyme inhibitory and antioxidant properties of *Anethum graveolens* L. (dill) samples cultivated under organic and conventional agricultural conditions. *Food Chem Toxicol*. 2013 Sep;59:96-103.
14. Qujeq D, Laghaie B, GholipourA, Solimani N, S HassenzadehS. Effects of sodium fluoride on total serum protein levels and transaminase activity in rats. *Biomedicine & Pharmacotherapy* 56(4):169-72 · June 2002
15. AliAsgharYoonesi, DurdiQujeq, Mohsen Esmaili, FaridehFeizi. Effects of Combination of G-CSF and SCF One Week Prior to Liver Injury In Acute liver Damage Model Induced by Thioacetamide Administration Volume 2, Number 1 (2014) *Res Mol Med (RMM)* 2014, 2(1): 21-25.
16. Qujeq D, AbassiR, Faeizi F, ParsianH, SohanFarajiA, Taheri H, Tatar M, Elmi1 MMHalalkhorH. Effect of granulocyte colony-stimulating factor administration on tissue regeneration due to carbon tetrachloride-induced liver damage in experimental model. *Toxicology and Industrial Health* 29(6) 498–503, 2012.
17. Qujeq D, Sadogh M, SavadkohlS. Association between helicobacter pylori infection and serum iron profile. *Caspian J Intern Med*. 2011 ;2(3):266-9.
18. Wang M, Liu R, Liang Y, Yang G, Huang Y, Yu C, Sun K, Lai Y, Xia Y. Iron overload correlates with serum liver fibrotic markers and liver dysfunction: Potential new methods to predict iron overload-related liver fibrosis in thalassemia patients. *United European Gastroenterol J*. 2017 Feb;5(1):94-103.
19. Datz C, Müller E, AignerE. Iron overload and non-alcoholic fatty liver disease. *Minerva Endocrinol*. 2017 ;42(2):173-183.
20. Asare, G.A., K.S. Mossanda, M.C. Kew, A.C. Paterson, C.P. Kahler-Venter and K. Siziba,. Hepatocellular carcinoma caused by iron overload: A possible mechanism of direct hepatocarcinogenicity. *Toxicology*, 2006; 219: 41-52.
21. Peng An, Hao Wang, Qian Wu, XinGuo, Aimin Wu, Zhou Zhang, Di Zhang, XiaochenXu, Qianyun Mao, XiaoyunShen, Lihong Zhang, ZhiqiXiong, Lin He, Yun Liu, Junxia Min, Daizhan Zhou and FudiWangc, Elevated serum transaminase activities were associated with increased serum levels of iron regulatory hormone hepcidin and hyperferritinemia risk, *Sci Rep*. 2015; 5: 13106.
22. Richardson D.R., and Ponka P. Pyridoxalisonicotinoylhydrazone and its analogs: potential orally effective iron-chelating agents for the treatment of iron overload disease. *J Lab Clin Med*. 1998;131(4):306-15.
23. Maiko Hayashi, Hideo Fukuhara, Keiji Inoue, Taro Shuin, YuichiroHagiya, Motowo Nakajima, Tohru Tanaka, Shun-ichiro Ogura, The Effect of Iron Ion on the Specificity of Photodynamic Therapy with 5-Aminolevulinic Acid, *PLoS ONE* .2015;10(3): e0122351.