Case Report

Iran J Ped Hematol Oncol. 2018, Vol 8. No 3, 247-251

A Case of Childhood Undifferentiated Embryonal Sarcoma of Liver Mimicking Hydatid Cyst

Mozhgan Hashemieh MD

Research and Development Center, Imam Hossein Medical Center, Shahid Beheshti University of Medical Sciences, Tehran, Iran.
*Corresponding author: Mozhgan Hashemieh, Imam Hossein Medical Center, Shahid Madani Street, Tehran, Iran. Email: mozhganhashemieh@gmail.com

Received: 13 September 2017 **Accepted:** 10 February 2018

Abstract

Background: Hepatic tumors are rare in children comprising only 1% - 4 % of all childhood solid tumors. Primary sarcomas of the liver are extremely rare and represent approximately 0.2 % of all liver tumors. Undifferentiated embryonal sarcoma of liver is an aggressive tumor with an unfavorable prognosis. Here we reported a case of undifferentiated embryonal sarcoma of liver in a 9-year-old boy who was misdiagnosed as hydatid cyst of liver.

Case Report: An 8-year-old male patient was referred to our hospital following unsuccessful surgery for presumed hydatid disease of the right lobe of liver. Computed tomography (CT) and ultrasonography showed a large hepatic mass. Following the surgery, our patient received adjuvant chemotherapy. At the time of writing, it has been one year after the termination of adjuvant chemotherapy. Follow up imaging studies, including ultrasonography, CT scan, and MRI show no evidence of recurrence.

Conclusion: Here we reported a case of undifferentiated embryonal sarcoma of liver in a 9-year-old boy mistaken for hydatid cyst of liver. Based on our observation, undifferentiated embryonal sarcoma of liver should be considered as a differential diagnosis among patients suspected of hydatid cyst of liver.

key words: Childhood Liver Tumors, Hydatid Cyst, Undifferentiated Embryonal Sarcoma of Liver

Introduction

Primary neoplasms of the liver are rare in children compromising only 1% to 4 % of all solid malignancies of children younger than 18 years of age (1). Hepatoblastoma and hepatocellular carcinoma are the two most common malignancies that arise in the liver (2). Sarcomas of the liver are extremely rare tumors and represent approximately 0.2 % of all primary liver tumors (3).

These tumors include a heterogenous group of histologic types, such as angiosarcoma, leiomyosarcoma, epitheloid hemangioendothelioma, fibrosarcoma, malignant fibrous histiocytoma, and undifferentiated embryonal sarcoma of the liver (UESL) (4- 7).

The peak incidence of UESL is among patients between 6 - 10 years old and is considered an aggressive neoplasm with an unfavorable prognosis (8). Previously this tumor was reported with a median survival of less than one year following diagnosis. However, the introduction of modern supportive care and multimodal treatment including tumor resection, adjuvant chemotherapy, and liver transplantation has led to longer survival rate (9, 10).

Preoperative clinical diagnosis of UESL is difficult due to the lack of specific clinical presentation, serological markers, and radiological changes (11, 12). UESL is sometimes misdiagnosed as other types of sarcomas involving the liver, including poorly differentiated or sarcomatoid hepatocellular carcinoma, embryonal rhabdomyosarcoma and other sarcomas (12).

Here we reported a case of UESL in an 8 year old boy misdiagnosed as hydatid disease of the liver.

Case report

[Downloaded from ijpho.ssu.ac.ir on 2026-11-24]

An 8-year-old male patient was referred to our hospital following unsuccessful surgery for presumed hydatid disease of the right lobe of liver.

The patient had abdominal pain in right upper quadrant and low grade fever since one month ago. His parents had consulted a local doctor in Mazandaran province in North of Iran. Computed tomography (CT) and ultrasonography showed a large hepatic mass. In ultrasonography, a solid cystic mass (140 × 150 mm) was detected in central part of the liver.

Gallbladder and intra- and extrahepatic biliary tracts were all normal. Abdominal CT scan revealed a well-defined low density large heterogenous mass (146 × 124 × 145 mm) in the right liver segment. Enhanced CT showed vessels, septa, and variable degrees of cystic changes in the tumor. This large mass had compressive effects on surrounding structures including inferior vena cava and renal arteries (Figure 1).

During admission, a huge, tender, and smooth faced liver was palpable from right side of the abdomen toward the mid-epigastric region. Laboratory data showed normal liver function tests, normal tumor markers including carcinoembryonic antigen (CEA), CA 125, alpha-fetoprotein, β – HCG, and negative hepatitis markers. His complete blood count showed a mild anemia (MCV = 56 & MCH = 23) compatible with minor beta thalassemia and ESR of 75. CRP and serum ferritin were 80 and 340 ng/ml, respectively. All kidney function tests were normal. The patient complained about generalized bone pain but a whole body radioisotopic bone scan showed no evidence of osteo metastases. Histologic examination showed infiltration of neoplastic cells composed of a mixture of spindle and satellite cells in a myxoid and hemorrhagic stroma.

Some of tumoral cells had granular pink cytoplasm. Entrapped hepatocytes and ductular structures were present highlighted by CKAE1 / AE3. Immunohistochemistry (IHC) findings showed positive desmin, vimentin, lysozyme, and α1 antitrypsin (α1 - AT) in tumor cells. Additionally, Myogenin, Myo D1, and NSE were negative in tumoral cells. Ki 67 nuclear staining was positive in about 35 - 40 % of neoplastic cells. Histomorphologic and immunohistochemical study documented the diagnosis of undifferentiated embryonal sarcoma of liver. Since the lesion was too large and invaded large vessels, it was accepted as inoperable by the hepatic surgeons. We decided to conduct chemotherapy for the patient promptly. The patient received Vincristine 1.5 mg / m2 / dose, Doxorubicin 75 mg / m2 / dose, and Cyclophosphamide 1200 mg / m2 / dose alternating every 3 weeks with Ifosfamide 1800 mg / m2 / dose and Etoposide 100 mg / m2 /dose daily for 5 days. At the end of 5 cycles of chemotherapy when total dose of Adriamycin (Doxorubicin) reached to 375 mg / m2, Dactinomycin at dose of 1.25 mg / m2 / dose replaced Adriamycin. After 6 cycles of combination chemotherapy, the size of mass decreased to 73 × 66 mm in ultrasonography. Then patient underwent surgery and near total resection of tumor was performed.

Following the surgery, our patient received adjuvant chemotherapy. At the time of writing, it has been one year after the termination of adjuvant chemotherapy. Follow up imaging studies, including ultrasonography, CT scan, and MRI show no evidence of recurrence (Figure 2).

[Downloaded from ijpho.ssu.ac.ir on 2026-11-24]

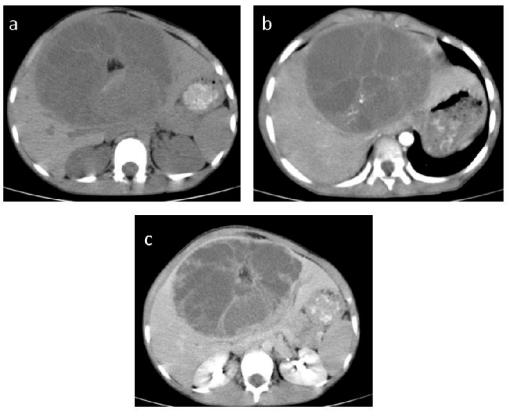

Figure 1. Pretreatment axial spiral computed tomography scan of abdomen revealed a well defined low density large heterogenous mass (146 × 124 × 145 mm) in the right liver segments.
a: without contrast ,b: with contrast (portal phase), c: with contrast (delayed phase).

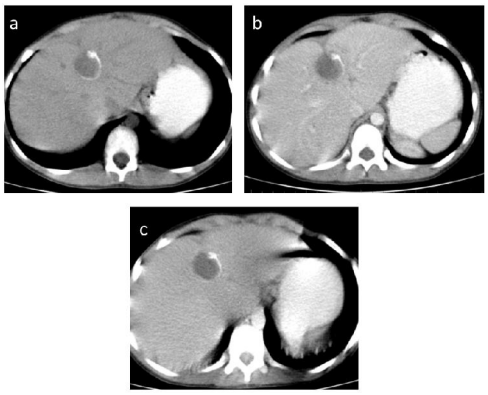

Figure 2. Post treatment axial spiral computed tomography scan of abdomen revealed a well defined hypodense non-enhancing lesion with thick calcified rim.
a: without intravenous contrast ,b: with contrast (portal phase),c: with contrast (delayed phase).

Discussion

Various terms such as malignant mesenchymoma, embryonal sarcoma, and fibromyosarcoma were summarized under the term undifferentiated embryonal sarcoma of liver after that Stocker and Ishak published a series of 31 cases in 1978. UESL is considered a pediatric neoplasm with a peak incidence at 6 to 10 years of age (8, 9).

Clinical symptoms of UESL are variable and nonspecific, including abdominal mass with or without abdominal pain, fever, nausea, vomiting, weight loss, fatigue, and jaundice. Occasionally spontaneous rupture may result in intraperitoneal hemorrhage due to rapid growth of tumor. Very rare manifestations include erythropoietin secreting capacity and life threatening paraneoplastic syndromes (12). Its frequency in the adult population is extremely rare, affecting mostly adults under the age of 30 years (13).

UESL often show a misleading cystic appearance on CT and MRI in contrast to a predominantly solid appearance on ultrasound (14). MRI typically demonstrates large portions of the mass which are hypo intense on T1W images and have high signal intensity on T2W images. With gadolinium administration, there is a mild heterogenous enhancement with predominant lack of enhancement in most of the tumor, consistent with extensive central necrosis or cystic change (15). There have been previous case reports of hepatic UESL being mistaken for hydatid disease in literature (16, 17, 18).

Histologic studies are mandatory to distinguish UESL from other liver neoplasms of mesenchymal origin such as rhabdomyosarcoma, leiomyosarcoma, and fibrosarcoma but differential diagnosis may be difficult because of some overlapping features. The distinction of UESL from hepatic tumors of epithelial origin such as hepatoblastoma and hepatocellular carcinoma appears less problematic. There are no distinctive laboratory markers for this tumor. Evaluation of some tumor markers such as alpha-fetoprotein (AFP), CA 19 -9, CA 125, β – HCG, and CEA often yield normal results (19).

The prognosis of UELS has been known to rely on whether surgical resection can be achieved, but total resection of the tumor at the time of initial diagnosis is often difficult. However, despite complete resection in some cases, local recurrence and distant metastases have been major factors in achieving long term survival

[Downloaded from ijpho.ssu.ac.ir on 2026-11-24]

(20). Positive resection margins and spontaneous rupture of the tumor are associated with early recurrence and death (21).

After tumor resection, all of patients must receive adjuvant chemotherapy in order to achieve long term survival. Different chemotherapeutic agents have been used in chemotherapy regimens for UESL including, Vincristine, Doxorubicin, Actinomycin-D, Cyclophosphamide, Ifosfamide, Etoposide, Cisplatin, and Carboplatin (22). In prior decades, the survival rate for UESL was less than 37 %. However, the widespread use of chemotherapy regimens has lead to improved survival and the survival rate is currently reported to be > 70 %. Metastases have been shown to accrue in 5% to 13 % of children (23). The effectiveness of radiation therapy to prevent recurrence and improve survival in UESL is unknown. Radiation therapy has been used in the postoperative setting to prevent recurrence in the tumor bed in adults (23). In addition, Plant et al., showed that radiation therapy could successfully treat lung and paraspinal metastases in two adult patients (24).

Limited experience exists on the role of liver transplantation in children with UESL, and it may be successful in refractory or unresectable cases (25). Other authors have recommend liver transplantation for patients who have no evidence of extrahepatic manifestations when multiple hepatic UESL lesions are preset and previously administered chemotherapy does not allow secondary resection (26).

Conclusion

Here we reported a case of undifferentiated embryonal sarcoma of liver in a 9-year-old boy mistaken for hydatid cyst of liver. Based on our observation, undifferentiated embryonal sarcoma of liver should be considered as a differential diagnosis among patients suspected of hydatid cyst of liver.

Conflicts of interest

The authors declare no conflict of interest.

References

1. Darbari A, Sabin KM, Shapiro CN, Schwarz KB. Epidemiology of primary hepatic malignancies in US children. Hepatol. 2003; 38(3): 560-6.

2. Rapkin LB, Olson TA. Hepatic tumors.In Lanzkowsky P, Lipton JM, Fish JD, eds. Lanzkowsky manual of pediatric hematology and oncology,6th edition. Elsevier, 2016:569-76.

3-Lenze F, Birkfellner T, Lenz P, Hussein K, Länger F, Kreipe H, et al. Undifferentiated embryonal sarcoma of the liver in adults .Cancer. 2008;112(10):2274-82.

4. Weitz J, Klimstra DS, Cymes K, Jarnagin WR, D'Angelica M, La Quaglia MP, et al. Management of primary liver sarcomas. Cancer. 2007;109(7):1391-6.

5. Alrenga DP. Primary fibrosarcoma of the liver. Case report and review of the literature. Cancer. 1975;36(2):446-9.

6. Arends JW, Willebrand D, Blaauw AM, Bosman FT. Primary malignant fibrous histiocytoma of the liver--a case report with Immunocytochemical observations.
1987;11(4):427-31.

7. Fujita S, Lauwers GY. Primary hepatic malignant fibrous histiocytoma: report of a case and review of the literature. Pathol Int. 1998;48(3):225-9.

8. Stocker JT, Ishak KG. Undifferentiated (embryonal) sarcoma of the liver: report of 31 cases. Cancer. 1978;42(1):336-8.

9. Bisogno G, Pilz T, Perilongo G, Ferrari A, Harms D, Ninfo V, et al. Undifferentiated sarcoma of the liver in childhood: a curable disease. Cancer. 2002;94(1):252-7.

10. Noguchi K, Yokoo H, Nakanishi K, Tsuruga Y, Kamachi H, Matsushita M, et al. A long-term survival case of adult undifferentiated embryonal sarcoma of liver. World J Surg Oncol. 2012;10:65.

11. Cao Q, Ye Z, Chen S, Liu N, Li S, Liu

[Downloaded from ijpho.ssu.ac.ir on 2026-11-24]

F. Undifferentiated embryonal sarcoma of liver: a multi-institutional experience with 9 cases. Int J Clin Exp Pathol. 2014;7(12):8647-56.
12. xZhang H, Lei L, Zuppan CW, Raza AS. Undifferentiated embryonal sarcoma of the liver with an unusual presentation: case report and review of the literature. J Gastrointest Oncol. 2016;7(Suppl 1):S100-6.
13. Varol U, Karaca B, Muslu U, Doğanay L, Değirmenci M, Uslu R, et al. Undifferentiated embryonal sarcoma of the liver in an adult patient: case report. Turk J Gastroenterol. 2012;23(3):279-83.
14. Faraj W, Mukherji D, El Majzoub N, Shamseddine A, Shamseddine A, Khalife M. Primary undifferentiated embryonal sarcoma of the liver mistaken for hydatid disease. World J Surg Oncol. 2010;8:58.
15. Sodhi KS, Bekhitt E, Rickert C. Paradoxical hepatic tumor: Undifferentiated embryonal sarcoma of the liver. Indian J Radiol Imaging. 2010;20(1):69-71.
16. Charfi S, Ayadi L, Toumi N, Frikha F, Daoud E, Makni S, et al. Cystic undifferentiated sarcoma of liver in children: a pitfall diagnosis in endemic hydatidosis areas. J Pediatr Surg. 2008, 43(6):E1-4.
17. Aggarwal S, Guleria S, Dinda AK, Kumar L, Tarique S: Embryonal sarcoma of the liver mimicking hydatid cyst in an adult. Trop Gastroenterol. 2001,22(3):141-2.
18. Yoon JY, Lee JM, Kim DY, Choi GH, Park YN, Chung JW, et al. A case of embryonal sarcoma of the liver mimicking a hydatid cyst in an adult. Gut Liver. 2010;4(2):245-9.
19. Zhang H, Lei L, Zuppan CW, Raza AS. Undifferentiated embryonal sarcoma of the liver with an unusual presentation: case report and review of the literature. J Gastrointest Oncol. 2016;7(Suppl 1):S100-6.
20. Zhao X, Xiong Q, Wang J, Li MJ, Qin Q, Huang S, et al. Preoperative Interventional Therapy for Childhood Undifferentiated Embryonal Liver Sarcoma: Two Retrospective Cases from a Single Center. European J Pediatr Surg Rep. 2015;3(2):90-3.
21. Pachera S, Nishio H, Takahashi Y, Yokoyama Y, Oda K, Ebata T, et al. Undifferentiated embryonal sarcoma of the liver: case report and literature survey. J Hepatobiliary Pancreat Surg. 2008;15(5):536-44.
22. Walther A, Geller J, Coots A, Towbin A, Nathan J, Alonso M, et al. Multimodal therapy including liver transplantation for hepatic undifferentiated embryonal sarcoma. Liver Transpl. 2014;20(2):191-9.
23. Shi Y, Rojas Y, Zhang W, Beierle EA, Doski JJ, Goldfarb M, et al.. Characteristics and outcomes in children with undifferentiated embryonal sarcoma of the liver: A report from the National Cancer Database. Pediatr Blood Cancer. 2017;64(4). 24. Plant AS, Busuttil RW, Rana A, Nelson SD, Auerbach M, Federman NC, et al. A single-institution retrospective cases series of childhood undifferentiated embryonal liver sarcoma (UELS): success of combined therapy and the use of orthotopic liver transplant. J Pediatr Hematol Oncol. 2013;35(6):451-5.
25. Kelly MJ, Martin L, Alonso M, Altura RA.. Liver transplant for relapsed undifferentiated embryonal sarcoma in a young child. J Pediatr Surg. 2009;44(12):e1-3.
26. Dower NA, Smith LJ, Lees G, Kneteman N, Idikio H, Emond J, et al. Experience with aggressive therapy in 3 children with unresectable malignant liver tumors. Med Pediatr Oncol. 2000;34(2):132-5.

[Downloaded from ijpho.ssu.ac.ir on 2026-11-24]