

Acute Immune Thrombocytopenic Purpura in Infants

Hashemi A MD¹, Kargar F MD², Souzani A MD², Hazar N MD³

1- Assistant professor of Pediatric Hematology & Oncology of Shahid Sadoughi University of Medical Sciences, Yazd (Hematology, Oncology & Genetics Research Center of Shahid Sadoughi University of Medical Sciences, Yazd)

2- Medical doctor (Hematology, Oncology & Genetics Research Center of Shahid Sadoughi University of Medical Sciences, Yazd)

3- General practitioner

Received: 21 April 2011

Accepted: 14 July 2011

Abstract

Objective

Immune thrombocytopenic purpura (ITP) manifests as an easy bruising or extravasation of blood from capillaries into skin and mucous membranes. The characteristics of acute ITP in infants have rarely been described. In order to better understand acute ITP in infants, the characteristics of the disease at this age group was investigated.

Material and Methods

The present descriptive, cross-sectional study, variables such as age, sex, clinical presentation, treatment outcome, and the rate of chronicity in 72 infant suspected to ITP on admission were evaluated from 2002 to 2008 at Yazd Shahid Sadoughi Hospital.

Results

Analyzing data showed among 72 cases, 31 were female and 41 were male; aged 15 days to 2 years old. According to the result of bone marrow aspiratation, 66 patients had ITP, 2 had Wiskott Aldrich and 4 patients had Fanconi anemia. Clinical presentations of the patients with ITP were as following: 55 patients (83.3%) had purpura, 27 (40.9%) active mucosal bleeding and 2 (3%) had intra cranial hemorrhage. According to the history of patients; 31 patients (47%) had common cold, 17 (25.8%) were positive for vaccination, 2 (3%) had a history of chickenpox. They all had good response to treatment. There was no significant relationship between sex and disease progression towards the chronic phase (Pvalue: 0.554). A total of 16 chronic ITP had complete response to treatment (with IVIG and corticosteroids, Anti D, Azathioprine).

Conclusion

ITP in infant is a benign disease and responds well to treatment. Vaccination and viral illnesses play an important role in the etiology of ITP in children.

Key words

Infant, Age, Acute, Chronic, ITP

Corresponding Author:

Azam sadat Hashemi, Pediatric Hematologist & Oncologist, Assistant professor – Hematology oncology and Genetics Research Center, Shahid Sadoughi university of medical sciences and health services, Yazd- Iran

Email: dr_a_hashemi@yahoo.com

Introduction

Platelets are an important component in the first phase of hemostasis –platelet plug formation (1,2). Acute immune thrombocytopenic purpura (ITP) is a well-described illness in children (3–6); however, the characteristics of this entity in infants have rarely been analyzed. Moreover, different conclusions about response to various treatments and incidence of chronicity in infants with acute ITP have been noted in the relevant literature (4–6). It has been documented that acute ITP occasionally is followed by immunization with measles, measles–mumps–rubella (MMR), hepatitis B, influenza, diphtheria–pertussis–tetanus (DPT) and chickenpox vaccines (7–14). Clinical symptoms include Petechiae, purpura and mucosal bleeding. Patients usually have a history of viral di or vaccination before the disease. The most serious complication of disease ITP is intra cranial hemorrhage (ICH) that occurs in less than one percent of the patients (15, 16). In most of the cases (70-90%), patients improve in six month or even less, while the disease becomes chronic (duration > 6 months) in 10 – 30% of the cases. (17) Immune thrombocytopenic purpura (ITP) is divided in an acute and chronic form based on the duration of the disease. Persistence of thrombocytopenia for more than 6 months defines chronic ITP (18).

The most common differential diagnoses (DDX) of ITP are Wiskott Aldrich syndrome and Fanconi syndrome.

To raise awareness of infant ITP, we describe the clinical features, laboratory data, and treatment outcomes of 72 infant with ITP (17).

Material and Methods

We reviewed the charts of 72 patients .The patients diagnosed and treated for ITP from 2002 to 2008 at the Shahid Sadoughi Hospital of Yazd. Newborn infants with neonatal alloimmune thrombocytopenia and immune thrombocytopenia secondary to maternal ITP were excluded from this analysis. And variables such as age (under 1 year age group and above 1 year age group), sex, immunization history, clinical features and laboratory values, treatment, and outcome were evaluated. Bone marrow aspirates were performed at the discretion of the treating physician. The most common presenting symptoms were purpura, petechia, gastrointestinal bleeding, hematuria, ICH, epistaxis and oral gum bleeding. The treatment in patients included 400 mg/kg/day intra venous immune globulin for 5 days or 1-2 gms/kg/day for 2 days with or without 15-20 mg/kg/day methyl prednisolone for 5 consecutive days and in chronic phase included anti D (55microgr/kg), azathioperin (50mg/m2/day), cyclosporine (3-5 mg/kg/day) .

Chronic ITP was defined as thrombocytopenia (less than 150,000/ml) persisting for longer than 6 months after diagnosis of acute ITP.

Rate of response to treatment was evaluated on the basis of increase in platelet count (> $50 \times 10^9/L$) and complete response was referred to a persistent PLT above $150 \times 10^9/L$.

Relapse of disease was considered as decrease in platelet count (< 15000) after the initial stage of recovery.

The data was analyzed using SPSS statistic software. Chi square test was used for analysis of the effect of age and sex on this disease.

Results

From among the 72 patients initially admitted with probable diagnosis of ITP, 31(43.6%) were females and 41(56.4%) were males. Their age ranged from 15 days to 2 years. On the basis of results bone marrow aspiration, 66 patients (91.6%) were ITP, 2 patients (2.7%) had Wiskott Aldrich and 4 patients (5.5%) had Fanconi anemia. Of these infants with ITP, 55 patients (83.3%) presented with purpura and 27 patients (40.9%)with active mucosal bleeding (most commonly epistaxis) and 2 patients(3%) with ICH. 31 patients (47%) had a

history of common cold, 17 patients (25.8%) had history of vaccination and 2 patients (3%) had a history of chickenpox.

According to treatment, 66 patients received IVIG with or without corticosteroids and 52 patients showed complete response to the initial treatment. Of the total, 50 patients (27 male and 23 female) had acute ITP (75.76%) that 42 patients (58.3%) were under 1 year old and 8 patients (11.1%) were above 1 year old. 16 patients (24.24%) had chronic ITP that 10 patients (13.8%) were under 1 year old and 6 (8.3%) were above 1 year old (9 were male and 7 were female). There was no significant relationship between sex and disease progression towards the chronic phase (Pvalue: 0.554). The treatment regimens of the chronic group were as follows: IVIG and corticosteroids (7 patients), Anti D (4 patients) and Azathioprine (5 patients). They all had good response to treatment. Relapse of disease was considered as decrease in platelet count (< 150000) after the initial stage of recovery.

Discussion

Immune thrombocytopenic purpura or ITP is an autoimmune disease that is characterized by skin-mucous bleeding and decrease in platelets (less than 150,000). Patients usually have a history of viral disease or vaccination before the disease.

In this study, we reported 66 patients with ITP from 15 days to 2 years. 50 patients (75/76%) had acute ITP (of which 42 patients were under 1 year old). The most common presenting symptoms were purpura, petechia, gastro-intestinal bleeding, hematuria, ICH, epistaxis and oral gum bleeding. Acute ITP in infants have rarely been described. In 1990s, Ballin et al. (18) reported 57 acute ITP patients below 2 yr. Hord et al. (19) described 12 infants with acute ITP and compared them with children of acute ITP in 1994. Sandoval et al. (17) reported 79 cases with acute ITP that 26 were below 1 yr old. Males were predominant in these series (20, 21), including our study. However, the response to treatment and the incidence of chronicity in infants with acute ITP are good. Our results showed all infants had rapid response to treatment, as the diagnoses of acute ITP in infants were confirmed by bone marrow aspiration.

In this study, petechia and purpura were the most common symptoms (83/3%) that are similar to other studies (2, 22, 23).

On the other hand, active mucosal bleeding occurred in 27 cases (40/9%) which was more as compared to other similar studies (2, 22, 23).

In our study, 31 patients (47%) had experienced an infection in the past one month, As the study by Ramyar, 46 patients (48%) had a history of upper respiratory viral infection in recent month (2). In the present study, 75/76% cases had acute disease and 24/24% of cases had chronic disease and similar studies have reported the rate of chronicity from 17/50% to 25% (16,24).

In the study by LG Robb and K Tiedman, there was no significant relationship between sex and disease progression towards the chronic phase (Pvalue: 0.4) (25) that is similar to the present study (Pvalue: 0.554).

Vaccination may play an important role in the etiology of infant ITP. Mumps-measles-rubella (MMR) vaccination is linked with the development of ITP. The study suggests that further immunization is not contraindicated in infants experiencing acute ITP associated with vaccines.

In this study 25.8% had a history of vaccination and re-boosters with vaccines revealed no recurrence of the disease in all of these patients. That is similar to study by Wang J-D et al. (6) while one patient in study by Mossalem M et al, having a relapse 4 weeks after immunization MMR (23).

In the present study, the rate of ICH was 3 % (2 cases) who were treated with combination of corticosteroids and IVIG and both had a complete response to treatment. The rate of ICH in

LG Robb and K Tiedeman's study was one percent (3 from 289 patients) who was treated with corticosteroids and died finally (25) while Mossalem M et al reported that none of the ITP patients had life-threatening hemorrhage (23).

In conclusion infant ITP responded favorably to treatment. Vaccination and common cold may play an important role in etiology of ITP.

References

1. Karayalcin G. Disorders of Platelets in :Philip Lanzkowsky , M.B., ch.B, M.D., Sc.D.,F.R. C.P.,D.C. H., F. A.A.P. Manual of pediatric Hematology and Oncology. Fourth edition. Elsevier Academic. 2005: 250-263.
2. Ramyar a, Kalantari N. clinical features and treatment response of 96 infants with Immune thrombocytopenic purpura. *Acta Medical Iranica*. 2007;45(6):466-468
3. Kühne T, Imbach P, Bolton-Maggs PH, Berchtold W, Blanchette V, Buchanan GR;Intercontinental Childhood ITP Study Group. Newly diagnosed idiopathic thrombocytopenic purpura in childhood: an observational study. *Lancet*. 2001;358(9299):2122-5.
4. Kühne T, Buchanan GR, Zimmerman S, Michaels LA, Kohan R, Berchtold W, Imbach P; A prospective comparative study of 2540 infants and children with newly diagnosed idiopathic thrombocytopenic purpura (ITP) from the Intercontinental Childhood ITP Study Group. *J Pediatr*. 2003;143(5):605-8.
5. Bolton-Maggs PHB. Idiopathic thrombocytopenic purpura. *Arch Dis Child*. 2000;83:220–222.
6. Wang JD, Huang FL, Chen PY, Wang TM, Chi CS, Chang TK. Acute immune thrombocytopenic purpura in infants: associated factors, clinical features, treatment and long-term outcome. *Eur J Haematol*. 2006;77(4):334-337.
7. Yenicesu I, Yetgin S, Ozyurek E. Vaccination-associated immune thrombocytopenic purpura in five children. *Pediatr Hematol Oncol* 2001;18(8):547–549.
8. Arya LS, Ghai OP, Saraya AK. Thrombocytopenic purpura following DPT vaccination. *Pediatr Hematol Oncol* 1993;10(4):381–383.
9. Poullin P, Gabriel B. Thrombocytopenic purpura after recombinant hepatitis B vaccine. *Lancet* ; 344(8932):1293.
10. Meyboom RHB, Fucik H, Edwards IR. Thrombocytopenia reported in association with hepatitis B and A vaccines. *Lancet* 1995;1638:(8965)345.
11. Jadavji T, Scheifele D, Halperin S. Thrombocytopenia after immunization of Canadian children, 1992 to 2001. *Pediatr Infect Dis J* 2003;22(2):119–122.
12. Conesa V, Nunez ML, Navarro JF, Mompel A, Ruiz J,Gomez A. Thrombocytopenic purpura after recombinant hepatitis B vaccine. A rare association. *Haematologica*. 2001;86(3):E09.
13. Miller E, Waight P, Farrington P, Andrews N, Stowe J, Taylor B. Idiopathic thrombocytopenic purpura and MMR vaccine. *Arch Dis Child* 2001;84(3):227–229.
14. Farrington P, Pugh S, Colville A, Flower A, Nash J, Morgan-Capner P, Rush M, Miller E. A new method for active surveillance of adverse events from diphtheria/ tetanus/pertussis and measles/mumps/rubella vaccines. *Lancet* 1995;345(8949):567–569.
15. Psaila B, Petrovic A, Page LK, Menell J, Schonholz M, Bussel JB. Intracranial hemorrhage (ICH) in children with immune thrombocytopenia (ITP): study of 40 cases. *Blood*. 2009;114(23):4777-83.
16. Zeller B, Rajantie J, Hedlund-Treutiger I, Tedgard U, Wesenberg F, Jonsson OG, Henter JI. Childhood idiopathic thrombocytopenic purpura in the Nordic countries: epidemiology and predictors of chronic disease. *Acta paediatr*.2005;94(2):178-184.
17. Sandoval C, Visintainer P, Ozkaynak MF, Tugal O, Jayabose S. Clinical features and treatment outcomes of 79 infants with immune thrombocytopenic purpura. *Pediatr Blood Cancer*. 2004;42(1):109-12.
18. Ballin A, Kenet G, Tamary H, Rechavi G, Chividalli G, Burstein Y, Tauber T, Nussinovitch M, Meytes D. Infantile idiopathic thrombocytopenic purpura. *Pediatr Hematol Oncol* 1990;7(4):323–328.
19. Hord JD, Whitlock JA, Grossman NJ. Immune thrombocytopenic purpura in infants. *Arch Pediatr Adolesc Med* 1994;148(3):333–334.
20. Roberts I, Murray NA. Neonatal thrombocytopenia: causes and management. *Arch Dis Child Fetal Neonatal Ed* 2003;88(5):F359–F364.
21. King S, Germeshausen M, Strauss G, Welte K, Ballmaier M. Congenital amegakaryocytic thrombocytopenia: a retrospective clinical analysis of 20 patients. *Br J Haematol* 2005;131(5):636–644.
22. Kocak U, Aral YZ, Kaya Z, Ozturk G, Gursel T. Evaluation of clinical characteristics, diagnosis and management in childhood immune thrombocytopenic purpura :A single center's experience. *Turk J Pediatr*. 2007;49(3):250-5.
23. Mossalem M, Yassine N. Immune thrombocytopenic purpura in childhood: A Lebanese perspective. *Mol Immunol*. 2003;39(17-18):1105-7.

24. Blanchette V .Childhood chronic immune thrombocytopenic purpura (ITP). Blood Rev. 2002 Mar;16(1):23-26.
25. Robb LG, Tiedeman K. Idiopathic thrombocytopenic purpura: predictors of chronic disease. Arch Dis Child. 1990 ;65(5):502-6.

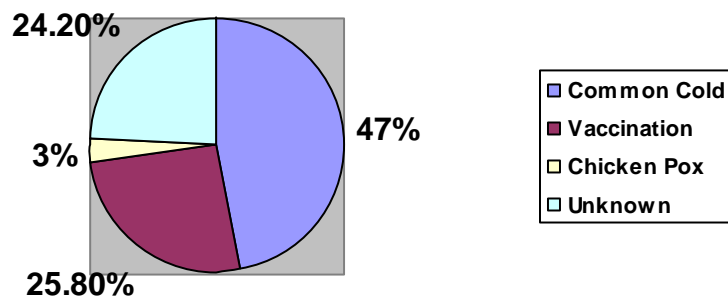


Fig1: The relationship between ITP and Previous History