Original Article *Iran J Ped Hematol Oncol. 2019, Vol 9, No 4, 244-252*

The Effect of Combination Iron Chelating Agents on Reducing the Severity Grading of Heart and Liver Iron Overload in β-Thalassemia Patients

Majid Ghanavat MD[1], Alireza Fazeli Varzaneh MD[2], Nahid Reisi MD[3,*]

1. Department of Pediatric Hematology and Oncology, Faculty of Medicine, Child Growth and Development Research Center, Isfahan University of Medical Sciences, Isfahan, Iran.
2. Department of Pediatric, Assistant of Pediatrics, Imam Hussein Hospital, Isfahan University of Medical Sciences, Isfahan, Iran.
3. Department of Pediatric Hematology and Oncology, Faculty of Medicine, Child Growth and Development Research Center and Isfahan Immunodeficiency Research Center, Isfahan University of Medical Sciences, Isfahan, Iran.
*Corresponding author: Dr Nahid Reisi, Department of Pediatric Hematology and Oncology, Omid hospital, Isfahan University of Medical Sciences, Isfahan, Iran. E-mail: Nahid.reisi136768@gmail.com. Orchid ID: 0000-0002-1240-0330

Received: 17 May 2019 **Accepted:** 21 July 2019

Abstract

Background: Deferasirox (DFX), Deferoxamine (DFO), and Deferiprone (DFP) are iron chelators that can be used in thalassemic patients with iron overload.

Materials and Methods: This clinical trial was performed on 108 thalassemic patients who were randomly divided into group A (n=54) and B (n=54). Group A received combination of DFX and DFP, and group B received DFO and DFP for six months. Serum ferritin level was measured at the beginning of the study, 3, and 6 months after the treatment; The heart and liver iron deposition rates were also measured at the beginning of the study, and 6 months after the treatment in both groups and compared using Magnetic Resonance Imaging T2 plus (MRI T2*).

Results: The mean age of patients in group A and B was 17.29±4.3 and 17.89±5.61 years old, respectively. Serum ferritin level significantly reduced after the treatment (Serum ferritin level at baseline, 3, and 6 months after the treatment in Group A: 2476.25±1289.32, 2089.62±1051.64 and 1290.22±724.78 ng/ml, respectively; in Group B: 2044.63±989.82, 1341.30±887.62 and 1229.41±701.22 ng/ml, respectively) ($p<0.01$, for both groups). MRI T2* heart and liver was also improved at the end of the study in both groups ($p<0.01$, for both groups). However, the combination of DFO/DFP significantly decreased severity grades of liver iron deposition in comparison to DFX/DFP regimen after six months ($p<0.01$).

Conclusion: The results of the present study indicated that both combination therapies of DFO/DFP and DFX/DFP could improve heart and liver MRI T2*. However, DFO/DFP combination therapy was more effective in reducing the severity grades of liver iron deposition.

Keyword: Beta-thalassemia, Heart, Iron chelating agents, Iron overload, Liver

Introduction

β-thalassemia major is the homozygous form of β-thalassemia. This severe and progressive hemolytic anemia begins usually in the second six-month of life when hemoglobin β chains start to synthesize and replace the fetal hemoglobin. Upon the beginning of the hemolytic anemia, these patients require repeated blood transfusions for survival (1-3). In the absence of iron chelators, iron is gradually accumulated in the patients' body (5 gram per year) (4). Therefore, these patients need to iron chelators to prevent hemosiderosis and damage to various organs such as the heart, liver, and endocrine glands (5).

Deferoxamine (DFO) as an iron chelator is the first line of treatment in β-thalassemic patients affected with an increase in iron levels due to the blood transfusion. DFO infuses through a subcutaneous (SC) pump for 8-12 hours at a dose of 20-40 mg/kg and increases urinary iron excretion (5-8). Although DFO is effective in controlling liver iron load, SC injection of DFO is not

[Downloaded from ijpho.ssu.ac.ir on 2026-11-25]

[DOI: 10.18502/ijpho.v9i4.1573]

able to prevent iron deposition in the heart of all patients; and Deferiprone (an oral iron chelator) is more effective than DFO in this regard (5).

Deferiprone (DFP) is an oral iron chelator that induces the excretion of 70-90% of iron through urine (9) and it is more effective in controlling heart iron load than DFO in thalassemic patients (5). Therefore, Due to the higher effect of DFO in reducing liver iron deposition and DFP in reducing heart iron deposition, combination therapy with DFO and DFP is a selective treatment for thalassemic patients with high iron deposition in the heart and liver (10, 11).

Deferasirox (DFX) is another iron chelator that was introduced in 2006. DFX is the oral form of deferoxamine approved by the U.S. Food and Drug Administration (FDA) and European Medicines Agency (EMA) for treatment of iron overload (12-14). DFX induces the excretion of 84% of iron through the stool and 8% of iron through the urine (14). This oral iron chelator is accepted by majority of patients, and has similar effects as DFO on iron removal (15).

These drugs in spite of the therapeutic effects have side effects. They also can increase level of serum creatinine and liver enzymes that should be considered during treatment (10-17).

The effect of combination therapy with DFO and DFP in thalassemic patients with high iron deposition in different organ has been proven in many studies (18). Oral combination therapy with DFX and DFP has been considered in these patients in recent years, but few studies have been carried out in this regard (19, 20), and more details have been needed.

Therefore, the aim of the present study was to compare the effects of DFX and DFP combination therapy with the conventional treatment (DFO and DFP) in reducing the severity grading of the heart and liver iron deposition in β-thalassemia patients with frequent blood transfusion.

Materials and Methods

Study design and population

This clinical trial was carried out on the blood transfusion dependent β-thalassemia patients treated in the thalassemic ward of Omid hospital affiliated with Isfahan University of Medical Sciences. This study was conducted April to October 2018. . In this study, all patients were under blood transfusions every 3/4 weeks.

Methods

The sample size was set as 50 each group considering 80% power and a 5% level of significance and using following equation:

$$n = \frac{\left(Z_{1-\frac{\alpha}{2}} + Z_{1-\beta}\right)^2 (SD_1^2 + SD_2^2)}{d^2} = \frac{(1.96 + 0.84)^2 (10.8^2 + 6.9^2)}{5.3^2} = 50$$

We recruited 108 eligible thalassemia patients in the study and randomly assigned them to group A and B. Two groups were then matched for age and gender, laboratory findings, and pretreatment heart and liver iron load based on Magnetic Resonance Imaging T2 plus (MRI T2*). Demographic characteristics of patients were recorded in a questionnaire. Cell Blood Count (CBC), level of serum ferritin, liver function test, Creatinine (Cr), and a urine sample were measured for each patients at the beginning of the study.

Group A (n=54) were treated with DFX at a dose of 20-40 mg/kg/day/Oral (Tab: 125, 250, 500 mg, Osveah pharma. Iran) half an hour before breakfast and DFP at a dose of 75 mg/kg/day/PO (Tab 500 mg, Avicenna Laboratories Inc. Iran) for six months. Group B (n=54) were also treated with DFO at a dose of 20-50 mg/kg/day (Vial Desfonak 500 mg/ Ronak pharma. Iran) subcutaneously via an infusion pump during 8-12 hr and DFP at a dose of 75 mg/kg/day/PO for six months.

Patients were visited once a month and examined in terms of gastrointestinal side effects, joint pain, skin rash, elevated level of serum AST, ALT, and Cr, proteinuria, neutropenia, agranulocytosis, and thrombocytopenia. Ferritin levels were

[Downloaded from ijpho.ssu.ac.ir on 2026-11-25]

[DOI: 10.18502/ijpho.v9i4.1573]

also measured in the third and sixth month of treatment (Figure 1). Heart and liver iron deposition were measured using MRI T2* at Noor MRI Center in Tehran before and six months after treatment. Based on this method, the heart and liver relaxation time (msec), which indicates the relative amount of iron deposition in the heart and liver, was measured and the severity of iron deposition was graded from normal to severe (Table I) (15).

Serum ferritin level was measured by chemiluminescence immunoassay method (IRMA Kit, Padtan Gostar Isar, Iran). Serum ALT and AST levels were measured by autoanalyzer and Pars Azmoon Kits (Karaj, Iran). Serum creatinine level was measured by Jaffe method (Delta Drman Part, Iran). Cells blood was counted by automated hematology analyzer Sysmex KX-21N.

Inclusion and exclusion criteria

Inclusion criteria

The inclusion criteria were as follows:

1. A confirmed diagnosis of major β-thalassemia (21),
2. age more than 10 years,
3. serum ferritin more than 1000 ng/ml,
4. mild, moderate, or severe iron deposition level in heart or liver according to MRI T2*,
5. not using combination therapy before entering the study,
6. having liver and renal with normal function,
7. and absence of digestive problems before entering in the study.

Exclusion criteria

Exclusion criteria were as follows:

1. Abnormal serum level of AST and ALT,
2. serum creatinine levels more than normal levels,
3. presence of protein in urine sample,
4. having history of gastrointestinal problems,
5. having history of drug sensitivity to iron chelators,
6. and presence of neutropenia (< 1500 per microliter) or thrombocytopenia (Platelet count <150000 per microliter) in CBC.

Ethical consideration

This study was approved by the local Ethics Committee of Isfahan University of Medical Sciences (Ethical code: IR. IUMS. REC. 397106) and registered on the Iranian Registry of Clinical Trials website (IRCT20190106042262N1). In addition, a written informed consent was obtained from each of the participants.

Statistical Analysis

All recorded data were entered into the Statistical Package for Social Sciences version 18.0 (SPSS Inc, Chicago, Illinois, USA). Paired t-test, and independent t-test were used to analyze the difference between the values obtained at baseline and six months after the treatment. Non-parametric test was also used when the assumptions of the t-tests were seriously violated. Changes in serum ferritin level in each group during the study were analyzed using one way repeated measures ANOVA test. Two way repeated measures ANOVA test was used for comparing serum ferritin level and MRI T2* values between two groups. The categorical measures were analyzed with chi-square test. In all tests, $p<0.05$ was considered the significance level.

Results

A total of 107 patients (53 males and 54 female) with a mean age of 17.59±4.9 years (ranging from 10 to 26) were included in this study. Patients were divided to two groups of A and B.

Group A included 54 patients with the age range of 10 to 26 years old. Only one patient in group A did not continue the treatment. Regarding age, 23 patients were males and 30 ones were females. Group B included 54 patients (30 males and 24 females) who aged 12 to 25 years old. Demographic and basic laboratory findings of the patients in two groups are shown in

[Downloaded from ijpho.ssu.ac.ir on 2026-11-25]

[DOI: 10.18502/ijpho.v9i4.1573]

Table II. As seen, the patients had no significant differences at baseline.

Effect of combination therapy on serum ferritin levels

Six months after treatment, mean± SD level of serum ferritin was significantly decreased in comparison with the baseline in both groups (P<0.01) according to one way repeated measures ANOVA test. However, two way repeated measures ANOVA test didn't show any significant difference between two groups in terms of the level of serum ferritin reduction (Figure 2).

Reducing effect of combination therapy on heart and liver iron load

Paired t-test indicated that liver and heart relaxation time in Group A and B significantly increased six months after the treatment (P<0.01 for both groups). However, two way repeated measures ANOVA test did not show significant difference between groups in term of increasing time of heart and liver relaxation (Table III).

Effect of combination therapy on severity grading of the heart and liver iron deposition

As shown in Figure 3, there was no significant difference between two groups (A and B) in terms of the baseline severity grading of iron deposition in the liver (P=0.268) and heart (P=0.694).

At the end of treatment, the severity grading of the liver iron deposition led to significant difference between two groups (P<0.01). However, there was no significant difference between two groups in terms of reducing the severity grading of iron deposition in heart at the end of study (P= 0.558).

Side effects and drug tolerance

The most frequent complaints in group A were gastrointestinal problems, nausea, and abdominal pain (n=7, 13.2%). all of these side effects were transient and patients did not require any further treatments. In group B, injection site problems, including burning, rash, and swelling were the most common complaints (n=21, 38.8%). Two patients (3.7%) had a complaint of gastrointestinal problems in group B. Mild arthralgia was reported in three patients (5.6%) in group A and two patients (3.7%) in group B.

Mild neutropenia developed in two patients (3.7%) of group B at the end of the study, so DFP was discontinued.

Increase level of serum liver enzymes, serum creatinine, proteinuria, thrombocytopenia, and agranulocytosis were not seen in any of the patients.

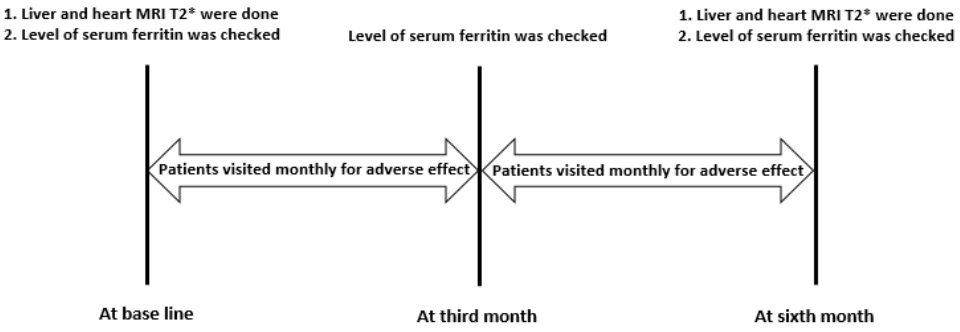

Figure 1. The three-stage study design flowchart.

[Downloaded from ijpho.ssu.ac.ir on 2026-11-25]

[DOI: 10.18502/ijpho.v9i4.1573]

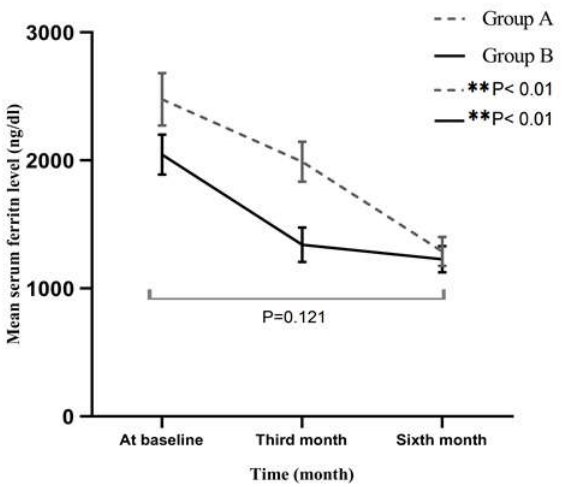

Figure 2. Line graph represent means ± SEM of serum ferritin level in A and B groups (n= 53 in group A and 54 in group B). Group A received Deferasirox and Deferiprone; group B received Deferoxamine and Deferiprone for 6 months. Serum ferritin level was evaluated on: 0, 3 and 6 months after treatment.** P <0.01 significantly different within group A and B. P= 0.121 no significant difference in decreasing the level of serum ferritin between the two groups

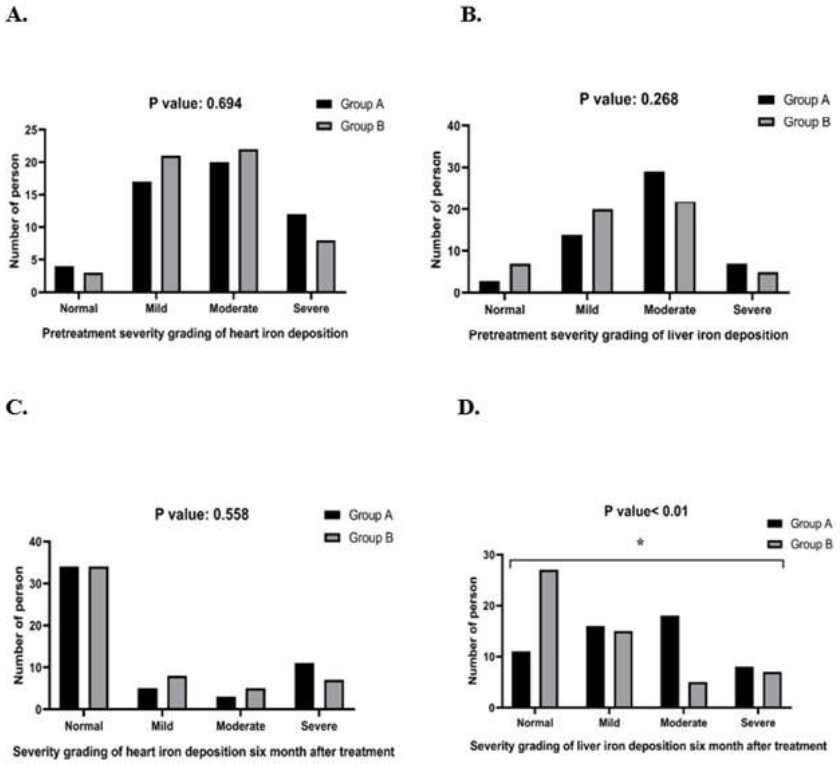

Figure 3. Bars represent severity the Grade of iron deposition in the heart (A) and liver (B) before treatment (n= 53 in group A and 54 in group B)and severity the Grade of iron deposition in the heart (C) and liver (D) six month after treatment (n= 53 in group A and 54 in group B). * P <0.01 significantly different between group A and B

[Downloaded from ijpho.ssu.ac.ir on 2026-11-25]

[DOI: 10.18502/ijpho.v9i4.1573]

TableI: Severity grading in heart and liver iron deposition

Severity grading	Heart T2* MRI value	Liver T2* MRI value
Normal (msec)	>20	>6.3
Mild (msec)	14-20	2.8-6.3
Moderate (msec)	10-14	1.4-2.7
Severe (msec)	<10	<1.4

Table II: Demographic and basic laboratory findings of the patients in two groups

Variable	DFX and DFP Group N=53	DFO and DFP Group N=54	P-Value¥
Age(year) mean±SD	17.29±4.3	17.89±5.61	0.260
Ferritin (ng/ml) mean±SD	2476.25±1289.32	2044.63±989.82	0.104
Aspartate transaminase(U/L) mean±SD	23.48±3.46	23.29±4.53	0.217
Alanine transaminase(U/L) mean±SD	18.32±4.21	17.39±6.7	0.354
Creatinine (mg/dl) mean±SD	0.5±0.2	0.6±0.15	0.221
Heart MRI T2* Value (msec) mean±SD	13.22±6.15	13.18±3.42	0.933
liver MRI T2* Value (msec) mean±SD	2.63±1.35	3.62±3.60	0.155

Abbreviation: DFX, Deferasirox; DFP, Deferiprone; DFO, Deferoxamine; MRI T2*, Magnetic Resonance Imaging T2 Plus,
¥: Resulted from independent sample t-test

Table III: Heart and Liver MRI T2 values at the baseline and six months after treatment*

Variable		Baseline	At Sixth month	P-Value©
Heart MRI T2* value (msec) Mean±SD	**DFX and DFP Group**	13.22±6.15	22.74±10.23	<0.01
	DFO and DFP Group	13.18±3.42	23.89±8.65	<0.01
$P\text{-value}_{Time}$®			0.318	
$P\text{-value}_{Intervention}$®			0.302	
$P\text{-value}_{Time*Intervention}$®			0.240	
Liver MRI T2* value (msec) Mean±SD	**DFX and DFP Group**	2.63±1.35	4.87±3.98	<0.01
	DFO and DFP Group	3.62±3.60	6.23±4.22	<0.01
$P\text{-value}_{Time}$®			0.350	
$P\text{-value}_{Intervention}$®			0.215	
$P\text{-value}_{Time*Intervention}$®			0.150	

[Downloaded from ijpho.ssu.ac.ir on 2026-11-25]

[DOI: 10.18502/ijpho.v9i4.1573]

Discussion

The findings of this study showed combination of DFX/DFP could improve MRI T2* value in liver and heart. This combination therapy reduced the severity grading of heart in thalassemia patients; however, in reducing the severity grading of the liver, DFO and DFP combination therapy was more effective than the other combination.

A previous study demonstrated that DFX (20-40mg/kg/day) exhibited a similar effect to that of DFO (20-50 mg/kg/day) on removing iron (15). However, the effect of the combined therapy was much greater than the effect of each drug alone (22-24). DFX and DFP can be a good alternative to conventional combination of DFO (SC) and DFP (PO) because both of them are oral chelators accepted by the majority of patients. Therefore, DFX and DFP combination therapy was used in the current study. Nevertheless, as far as we know, the effect of combination therapy on the severity grading of the heart and liver iron deposition has not investigated yet. Therefore, this study was attempted to evaluate the effect of DFX and DFP combination therapy on reduction of the severity grading of the heart and liver iron deposition in thalassemic patients.

In previous reports, level of serum ferritin was reduced by using combination therapy with DFX and DFP (14, 19-20). In these studies, the improving effect of DFX and DFP combination on MRI T2* value in the liver and heart of these patients was the same as that of DFO and DFP regimen .The findings of these reports are in accordance with those of current study, revealing that DFX and DFP combination could ameliorate MRI T2* value in the liver and heart.

The adverse reactions of these drugs were also evaluated in previous studies (1, 14) .Gastrointestinal complications with prevalence of 15% were the most common complication in patients treated with DFX (14). In the present study, transient gastrointestinal complication was also observed in patients treated with DFX/DFP combination therapy, but in accordance to pervious study, this complaint did not require any further treatment. In patients treated with DFO/DFP combination, injection site problems, including burning, rash, and swelling were the most common complications.

Gastrointestinal complications and injection site problems were the most common complications in group A and B, respectively. This difference can be attributed to different modes of administrations. However, DFX and DFP combination seems to have a reasonable safety comparison to the DFO and DFP combination, because both of them are oral chelators (25).

Finding of the present study showed that DFO and DFP combination therapy significantly reduced the severity grading of liver iron deposition in comparison with DFX and DFP combination therapy. Pustika et al., (2018) indicated that DFP was more effective than DFX and DFO in controlling heart iron deposition, and DFO was more effective than DFP in controlling the liver iron deposition (13). The effect of DFO was much greater than the effect of DFX and DFP in controlling liver iron deposition (26). The findings off these reports are in accordance with those off current study, demonstrating that DFO and DFP combination therapy significantly decreased severity grading of the liver iron deposition.

Based on the findings of the present study, it seems that DFO and DFP are more effective than DFX and DFP combination therapy in controlling the severity grading of the liver iron deposition, so patients with high-grade liver iron deposition (severe liver iron deposition) may be qualified candidates for DFO and DFP combination therapy.

In the future, more studies should be done investigating the effect of DFX and DFO on the severity grading of the liver iron deposition. Therefore, clinical trials are

[Downloaded from ijpho.ssu.ac.ir on 2026-11-25]

[DOI: 10.18502/ijpho.v9i4.1573]

recommended to determine the effects of combination therapy on the severity grading of heart and liver iron deposition in thalassemia patients.

Conclusion

The findings of the present study indicated that combination therapy with DFX and DFP was effective in reducing the level of serum ferritin and improving MRI T2* value in the heart and liver in β-thalassemia patients. Both combination therapy improved the severity grading of the heart iron deposition; however, in reducing the severity grading of liver DFO and DFP combination therapy dose being more effective than another group. Based on our findings, DFO and DFP combination therapy can be a potential candidate for the improvement of complications induced by iron deposition in the liver of patients with thalassemia.

Acknowledgment

This paper was extracted from a MD thesis approved at Isfahan University of Medical Sciences and the authors would like to give their gratitude to staff working at research center of this university for their financial support and cooperation.

Conflict of interest

The authors declare that there are no conflicts of interest regarding publication of this article.

References

1. Karami H, Kosaryan M, Amree AH, Darvishi-Khezri H, Mousavi M. Combination iron chelation therapy with deferiprone and deferasirox in iron-overloaded patients with transfusion-dependent β-thalassemia major. Clin Pract 2017; 7(1):912-916.
2. Wu HP, Lin CL, Chang YC, Wu KH, Lei RL, Peng CT, et al. Survival and complication rates in patients with thalassemia major in Taiwan. Pediatr blood & cancer 2017; 64(1):135-138.
3. Origa R. β-Thalassemia. Genet Med 2017; 19(6):609-619.
4. Ramadan M, Fouda MMI. Relationship between elevated liver enzymes with iron overload and viral hepatitis in children with b-thalassemia major. Al-Azhar Assiut Med J 2015; 13(2):93-97.
5. Pennell DJ, Berdoukas V, Karagiorga M, Ladis V, Piga A, Aessopos A, et al. Randomized controlled trial of deferiprone or deferoxamine in beta-thalassemia major patients with asymptomatic myocardial siderosis. Blood 2006; 107(9):3738-3744.
6. Xue H, Chen D, Zhong YK, Zhou ZD, Fang SX, Li MY, et al. Deferoxamine ameliorates hepatosteatosis via several mechanisms in ob/ob mice. Ann N Y Acad Sci 2016; 1375(1):52-65.
7. Songdej D, Sirachainan N, Wongwerawattanakoon P, Sasanakul W, Kadegasem P, Sungkarat W. Combined chelation therapy with daily oral deferiprone and twice-weekly subcutaneous infusion of desferrioxamine in children with β-thalassemia: 3-year experience. Acta haematologica 2015; 133(2):226-236.
8. Taghizadeh SR, MoradveisiB, Kompany F, Ghaderi E. Correlation between heart and liver iron levels measured by MRI T2* and serum ferritin in patients with β-thalassemia major. Int J Pediatr 2016; 4(3):1559-1567.
9. Stumpf JL.Deferasirox. Am J Health Syst Pharm 2007; 64(6):606-616.
10. Roberts D, Brunskill S, Doree C, Williams S, Howard J, Hyde C. Oral deferiprone for iron chelation in people with thalassaemia. CDSR 2007; (3):1-5.
11. Elalfy MS, Berdoukas V, Tricta F, Adly A, Hazza N, Awed H, et al. A Randomized Trial on the Safety and Efficacy of Early Start of Iron Chelation Therapy with Deferiprone in Newly Diagnosed Children with Transfusion Dependent Thalassemia. Blood 2016; 128(22):1286-1290.

[Downloaded from ijpho.ssu.ac.ir on 2026-11-25]

[DOI: 10.18502/ijpho.v9i4.1573]

12. Meerpohl JJ, Antes G, Rücker G, Fleeman N, Motschall E, Niemeyer CM. Deferasirox for managing iron overload in people with thalassaemia. CDSR 2012; (2):1-51.
13. Wahidiyat PA, Yosia M, Sari TT. Comparison of Deferiprone to Deferasirox and Deferoxamine to Cardiac and Hepatic T2* MRI in Thalassemia Patients: Evidence-based Case Report. Acta Med Indones 2018; 50(2):168-176.
14. Gomber S, Jain P, Sharma S,Narang M. Comparative efficacy and safety of oral iron chelators and their novel combination in children with thalassemia. Indian pediatrics 2016; 53(3):207-210.
15. Peng CT, Tsai CH, Wu KH. Effects of chelation therapy on cardiac function improvement in thalassemia patients: literature review and the Taiwanese experience. Hemoglobin 2008; 32(1-2):49-62.
16. Porter JB, Elalfy M, Taher A, Aydinok Y, Lee SH, Sutcharitchan P, et al. A. Limitations of serum ferritin to predict liver iron concentration responses to deferasirox therapy in patients with transfusion-dependent thalassaemia. Eur J Haematol 2017; 98(3):280-288.
17. Fisher SA, Brunskill SJ, Doree C, Gooding S, Chowdhury O,Desferrioxaminemesylate for managing transfusional iron overload in people with transfusion-dependent thalassaemia. CDSR 2013; (8):1-50.
18. Voskaridou E, ChristoulasD, Terpos E. Successful chelation therapy with the combination of deferasirox and deferiprone in a patient with thalassaemia major and persisting severe iron overload after single-agent chelation therapies. Br J Haematol 2011; 154(5):654-656.
19. Totadri S, Bansal D, Bhatia P, Attri SV, Trehan A, Marwaha RK. The deferiprone and deferasirox combination is efficacious in iron overloaded patients with β-thalassemia major: a prospective, single center, open-label study. Pediatr Blood Cancer 2015; 62(9):1592-1596.
20. Elalfy MS, Adly AM, Wali Y, Tony S, Samir A, Elhenawy YI. Efficacy and safety of a novel combination of two oral chelatorsdeferasirox/deferiprone over deferoxamine/deferiprone in severely iron overloaded young beta thalassemia major patients. Eur J Haematol 2015; 95(5):411-420.
21. DeBaun MR, Frei-Jones M, Vichinsky EP. Thalassemia syndromes. In: kliegman RM, Stanton BF, St Geme III JW, Schor NF, Behrman RE. Nelson textbook of pediatrics. 20 th ed. USA: Elsevir; 2016: 2348-2353.
22. Bollig C, Schell LK, Rücker G, Allert R, Motschall E, Niemeyer CM,et al. Deferasirox for managing iron overload in people with thalassaemia. CDSR 2017; (8):1-59.
23. Parakh N, Chandra J, Sharma S, Dhingra B, Jain R, Mahto D. Efficacy and safety of combined oral chelation with deferiprone and deferasirox in children with β-thalassemia major: an experience from North India. J Pediatr Hematol Oncol 2017; 39(3):209-213.
24. Ansari S, Azarkeivan A, Miri-Aliabad G, Yousefian S, Rostami T. Comparison of iron chelation effects of deferoxamine, deferasirox, and combination of deferoxamine and deferiprone on liver and cardiac T2* MRI in thalassemia major. CJIM 2017; 8(3):159-164.
25. Prabhu R, Prabhu V, Prabhu RS. Iron overload in beta thalassemia: a review. J Biosci Tech 2009; 1(1):20-31.
26. Pepe A, Meloni A, Capra M, Cianciulli P, Prossomariti L, Malaventura C, et al. Deferasirox, deferiprone and desferrioxamine treatment in thalassemia major patients: cardiac iron and function comparison determined by quantitative magnetic resonance imaging. Haematologica 2011; 96(1):41-47.

[Downloaded from ijpho.ssu.ac.ir on 2026-11-25]

[DOI: 10.18502/ijpho.v9i4.1573]