

## Original Article

# Medullary Breast Carcinoma in a 17 Year- Old Female (Rare Case Report)

Taghipour Zahir Sh MD<sup>1</sup>, Shiryazdi SM MD<sup>2</sup>, Vahidfar MR MD<sup>3</sup>

1-Associate professor of clinical and surgical pathology ,Shahid Sadoughi university of medical sciences, Yazd,Iran

2-Associate professor of General surgery ,Shahid Sadoughi university of medical sciences ,Yazd,Iran

3-Assistant Professor of Hematology and Oncology ,Shahid sadoughi university of medical sciences ,Yazd, Iran

---

Received:9October2011

Accepted:18January2012

## Abstract

### Background

Breast carcinoma is uncommon in women under 25 and very rare in less than 20 years old. Only few cases of infiltrating breast carcinoma have been reported and among them there was no report of medullary subtype. The purpose of this report is to determine clinical, histopathological and sonographic findings of large mass in breast of young female patient that diagnosed as medullary carcinoma.

### Case presentation

A 17 year-old female with large mass in her right breast was referred to our clinic. In clinical examination the mass had a fleshy to firm consistency and the borders were not infiltrative. Ultrasonography findings were highly suggested for fibroadenoma. Histopathological examination demonstrated infiltrating breast carcinoma with medullary feature.

### Conclusion

Although breast carcinoma is very rare in patients under twenty years old, in this age group a differential diagnosis with fibroadenoma should be considered.

### Key words

Carcinoma, Ultrasonography, Breast, Fibroadenoma

---

### Corresponding Author

Shokouh Taghipour Zahir, MD,AP,CP .Email: shokouh\_zahir@yahoo.com

Mobile:00989133531471.Phone:00983518113615.Address:Shahid sadoughi general hospital,pathology ward,Yazd,Iran

## Introduction

Breast carcinoma is the most common carcinoma among women. The incidence is low in most Asian and African population but is high in United states of America, especially North America (1,2). Medullary carcinoma is uncommon and estimated for fewer than 7% of all invasive breast carcinomas but in young women, especially less than 30 years old is rare (1,2,3,4). We present a case of medullary breast carcinoma in a 17-year -old young girl whom was admitted with a lump in her right breast.

## Case presentation

A 17-year- old female was admitted to the surgery clinic with large mass in her right breast. In physical examination it had a fleshy consistency and well circumscribed but non- mobile. She had no family history of breast carcinoma, no history of trauma to her breast or nipple discharge. Her first menstrual period initiated before the age of 12. She was not obese. The clinical and ultrasonographic diagnoses were fibroadenoma, so she underwent lumpectomy. Received specimen consisted of non encapsulated well circumscribed cream- grayish coloured tissue Measuring 5x4x2.5 cm. Microscopic examination of Hematoxylin and Eosin-stained slides revealed tumoral lesion composed of sheets of neoplastic cells, which had a large hyperchromatic nuclei arranged in syncytial pattern and surrounded by dense lymphocytic infiltration. Mitotic figures were conspicuous and some of them were atypical. Areas of necrosis and hemorrhage were also visible. Some of the neoplastic cells had a bizarre shape nucleus, and the tumor had a pushing border (Figures 1, 2). The primary diagnosis was medullary carcinoma and immuno histochemically the cells were strongly positive for vimentin and S-100 markers. Estrogen, progesterone and Her2neu receptors were all negative (Figures 3, 4, 5). Patient underwent conservative

breast surgery with axillary lymph nodes dissection(ten lymph nodes) and in that specimen, there was no residual tumor nor axillary lymph nodes involvement (T2N0M0, stage IIA, based on American joint committee on cancer staging system). So chemotherapy with Adriamycin (60mg/m<sup>2</sup>/24) and Cyclophosphamide (600mg/m<sup>2</sup>/24) were considered for her for four courses followed by Taxol (175/m<sup>2</sup>/3h) for four weeks, and finally radiotherapy for 28 days. At present time that we are reporting the case (after one year) she has no recurrence.

## Discussion

Breast carcinoma is uncommon in women under 40 years old and very rare under 20 years old (3,4,5).Hall et al reported the average incidence of breast carcinoma in women aged between 15-19 years about 1.3 per million. (6) Medullary breast carcinoma is a rare subtype between invasive ductal carcinomas and estimate for about 3-5% of all cases of breast cancer (3) .It can occur at any age but usually affects patients under 50 years old and is more common in those have a BRCA1 mutation (3,4) .Both grossly and radiologically especially in ultrasonography misdiagnosed as fibroadenoma and because in young age groups the breast has a higher density than in older ages, so mammography could not be used as a diagnostic tool. SN Abdul Rashid et al reported young female patient with a lump in her breast that ultrasonographic studying and clinical examination revealed fibroadenoma which contrast –enhanced Magnetic resonance imaging (MRI) suggested for malignant lesion and after biopsy, it was confirmed as medullary carcinoma, so they advised that in young patients this method is useful for differential diagnosis between fibroadenoma and malignancy (7). In our patient also mammography was not done, and ultrasonographic finding was suggestive for

fibroadenoma. Medullary carcinoma has a well circumscribed gross feature and, microscopically the cells are high grade, but they are low grade in behavior (3). The neoplastic cells usually immunohistochemically express markers of ordinary invasive ductal carcinoma but are commonly positive for S-100 protein and vimentin and majority negative for Her 2 neu, ER and PR receptors (3,4,5,6). Therefore, this type of carcinoma usually cannot be treated with hormonal therapies such as Tamoxifen or Aromate inhibitors and Herceptin. Axillary lymph nodes involvement by neoplastic cells is common but fewer than ordinary invasive ductal carcinoma. The prognosis of medullary carcinoma is better than invasive ductal carcinoma but like other invasive ductal carcinoma it depends on the tumor stage. Treatment is based on disease stage, and in early stage's conservative breast surgery, followed by chemotherapy and radiotherapy strongly recommended (3, 4, 5).

### Conclusion

Medullary breast carcinoma is an uncommon type of infiltrative breast carcinoma that usually affects women under 50 years old. It usually misdiagnosed clinically and grossly with fibroadenoma, and we should keep in mind this type of carcinoma in differential diagnosis of fibroadenoma, especially in young patients under 20 years old.

### Acknowledgement

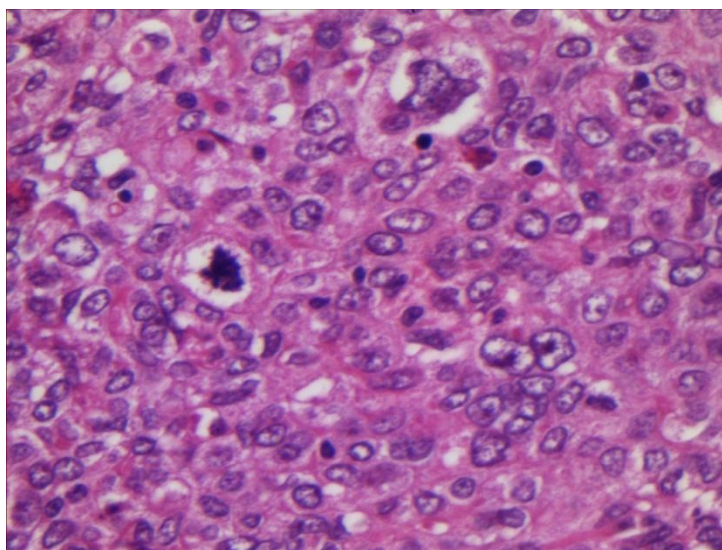
The authors would like to thank Dr goodarzian for his helps in editing the article.

### Conflicts of interest

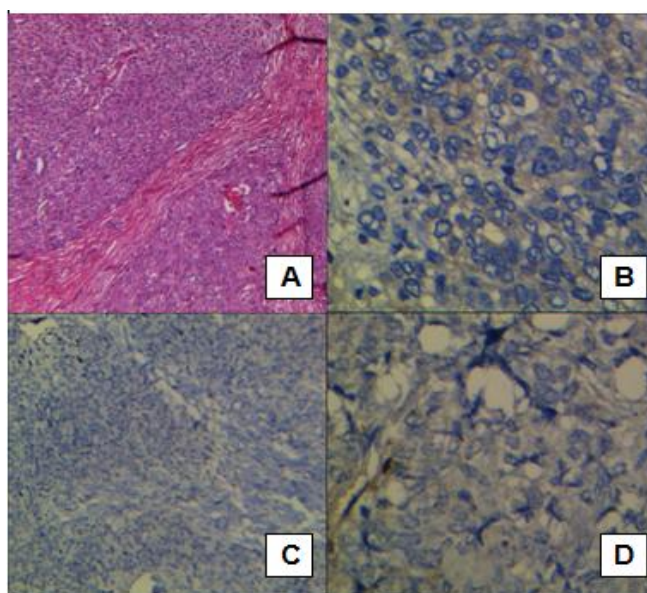
None of the authors have any conflicts of interest to declare.

### References

- 1-Mamoon N, Hassan U, Mustitaq S. Breast carcinoma in young women aged 30 or less in Northern Pakistan, the Armed forces institute of pathology experience. *Asian Pacific J cancer* 2009;10(6):1079-82.
- 2-Altekruse SF, Kosary CL, Krapcho M, Neyman N, Aminu R, Waldron W, et al, editors. SEER Cancer Statistics Review, 1975-2007. Bethesda (MD): National Cancer Institute; 2010.
- 3-Samir SM, Fayaz MS, Elbasmi A, Motavuy MM, Albuzallouf S, George T, et al. Medullary carcinoma of the breast: ten year clinical experience of the Kuwait cancer control centre. *Gulf J oncology* 2011;1(10):45-52.
- 4-Batori M, Ruggier M, Chatelou E, Straniers A, Mariotta G, Palombi L, et al. Breast cancer in young women: case report and a review. *Eur rev Med pharmacol Sci* 2006;10(2):51-2.
- 5-Kothari AS, Beechey-Newman N, D'Arrigo C, Hanby AM, Ryder K, Fentiman IS. Breast carcinoma in women age 25 years or less. *cancer* 2002;94(3):606-14.
- 6-Hall IJ, Moorman PG, Millikan RC, Newman B. Comparative analysis of breast Cancer risk factors among African-American women and White women. *Am J Epidemiol* 2005; 161(1):40-51.
- 7-Abdul Rashid SN, Rahmat K, Jayaprasagam KJ, Alli K, Moosa F. Medullary carcinoma of the breast; Role of contrast-enhanced MRI in the diagnosis of multiple breast lesions. *Biomed imaging Interv J* 2009;5(4):e27.



*Figure1: Medullary carcinoma cells have a large nuclei with multiple mitotic figures*



*Figure2: A. Medullary carcinoma with pushing borders ,B. Her 2 Neu negative Medullary carcinoma cells ,C. Estrogen receptor negative Medullary carcinoma cells. D: Progesterone negative Medullary cell carcinoma cells*