

## Hemophagocytic lymphohistiocytosis secondary to T-cell Acute Lymphoblastic Leukemia with membranous tonsillitis

Priyanka Singh<sup>1</sup>, Kusha Sharma<sup>1\*</sup>, Anu Maheshwari<sup>2</sup>, Sunita Sharma<sup>1</sup>

1. Department of Pathology, Lady Hardinge Medical College & Associated SSK and KSC Hospitals, New Delhi

2. Department of Paediatrics, Lady Hardinge Medical College & Associated SSK and KSC Hospitals, New Delhi

\*Corresponding author: Dr. Kusha Sharma, Department of Pathology, LHMC & Associated SSK & KSC Hospitals, Phone No. 9674031658, Email ID: drkushasharma@gmail.com. ORCID ID: 0000-0001-8376-4628.

Received: 12 August 2021

Accepted: 15 July 2022

### Abstract

Hemophagocytic lymphohistiocytosis (HLH) is a life-threatening syndrome of excessive immune activation, which is characterized by fever, hepatosplenomegaly, cytopenias, hyperferritinemia, hypertriglyceridemia, and/or hypofibrinogenemia, and evidence of hemophagocytosis. Secondary HLH is often seen in adults and categorized based on autoimmune, infections-related, and malignancy-associated etiologies such as A-HLH, I-HLH, and M-HLH, respectively. This study presented a rare case of HLH developing concurrently at the time of diagnosis of T-cell Acute Lymphoblastic Leukemia (T-ALL) with a unique presentation of membranous tonsillitis in a 10-year-old boy. In all of the cases of T-ALL reported in the pediatric age group, HLH develops post-therapy or at the relapse. The first presentation of leukemia as membranous tonsillitis and concurrent clinic laboratory findings of HLH is rare and can mislead the diagnosis. Therefore, prompt diagnosis is the mainstay of therapy and can considerably improve the prognosis.

**Key words:** Hemophagocytic lymphohistiocytosis, Leukemia, Tonsillitis.

### Introduction

Hemophagocytic lymphohistiocytosis (HLH) is a rare autoimmune dysregulation syndrome leading to a progressive multiple-organ failure (1). Secondary HLH is mostly seen in adults, triggered by autoimmune diseases, infections, and malignancy denoted as A-HLH, I-HLH, and M-HLH, respectively (2). Unchecked macrophage activation is linked to the failure of cytotoxic T-cells and NK cells in causing apoptosis of target cells leading to an ineffective hyperinflammatory response (3). Diagnosis can be difficult due to the lack of specific tests and a wide range of symptoms. Prompt diagnosis and treatment are crucial to prevent the devastating outcome. M-HLH has the worst result among all triggers, where the most common cause is adult lymphoma (4). Diagnosis can become challenging as there are various types of malignancies in the pediatric population and considering the

different presentations. Here, we presented a rare case of pediatric T-cell ALL with secondary HLH at the time of diagnosis, which showed membranous tonsillitis and clinically mimicked lymphoma. The present case emphasized the need for complete hematological workup in such patients, as there can be an unrelated concurrence of membranous tonsillitis and HLH with leukemia.

### Case Report

A ten-year-old boy presented with complaints of fever for three months, abdominal distension for one month, and neck swelling for eight days. On examination, he had pallor, generalized cervical lymphadenopathy with sub-centimetric axillary and inguinal lymph nodes, and 12 cm hepatosplenomegaly with membranous tonsillitis. The clinical possibility of lymphoma or tuberculosis was noted. Given membranous tonsillitis,

Albert stain for diphtheria was done, which was negative.

Chest X-ray showed mediastinal widening with clear lung fields. Contrast-enhanced computed tomography (CECT) of the neck, chest, and abdomen was suggestive of lymphoma. Liver and kidney function tests were within normal limits. Complete blood count (CBC) showed pancytopenia (Hb- 6.1g/dl, TLC-  $1.12 \times 10^3/\mu\text{l}$ , White blood cell (WBC) differential count- Polymorph 30%, Lymphocyte 60% Monocyte 8%, Eosinophil 2%. Platelet count -  $8 \times 10^3/\mu\text{l}$ ). Bone marrow aspiration was performed, and in spite of multiple attempts, it was diluted. However, bone marrow biopsy imprint smears were cellular and showed a monomorphic population of lymphoid cells with poorly preserved morphology. Few atypical cells with high nuclear: cytoplasmic (N:C) ratio, round to irregular nuclei, dispersed chromatin, and scant cytoplasm were seen. Erythroid, myeloid, and megakaryocytic series were suppressed. Numerous histiocytes, including a few epithelioid cells, were seen, with few showing haemophagocytosis (Figure 1).

C - reactive protein (CRP) was elevated (280.8mg/l). Prothrombin Time (PT), Activated Partial Thromboplastin Time (aPTT), and D-Dimer were normal. Viral markers were non-reactive. Montoux test, Acid Fast Bacilli (AFB), and Epstein-Barr virus (EBV) serology were negative. There was no neurological finding, and cerebrospinal fluid was negative for blasts (CNS-1). Erythrocyte sedimentation rate (ESR) was increased (50 mm/hr), and serum uric acid and Lactate dehydrogenase (LDH) were elevated (7.2 mg/dl and 512 U/L, respectively). However, serum albumin, calcium, phosphorous, and potassium levels were within the normal range.

Flow cytometry (Figure 2) of the bone marrow showed 86% cells with bright CD45, and low side scatter. The gated population showed moderate expression of CD3, CD4, CD8, CD2, dim to moderate

expression of CD5, CD7, and CD64, dim expression of CD1a and cCD3, and moderate to bright expression of CD99. The gated population was negative for CD19, CD10, CD79a, CD34, HLA-DR, MPO, TdT, and CD11b. Co-expression of CD4 and CD8 was seen in 4% of the population. A diagnosis of T-cell acute lymphoblastic leukemia was suggested. Given increased benign histiocytes with haemophagocytosis on bone marrow imprint smears, a workup for secondary HLH was advised. The latter workup showed raised serum S.ferritin ( $>800\mu\text{g/L}$ ) and triglyceride levels (387 mg/dl). Plasma fibrinogen was reduced (180 mg/dl). Thus, a final diagnosis of T-cell ALL with Secondary HLH was made. The patient died within three days after starting the induction phase.

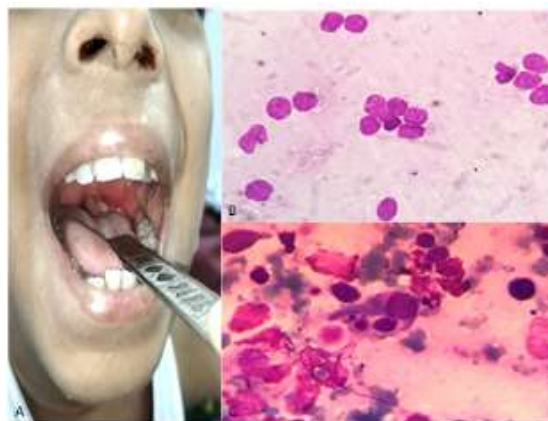


Figure 1. A. Photograph showing membranous tonsillitis, B. Bone marrow imprint smear showing atypical lymphoid cells (1000X, Giemsa stain), C. Focus showing haemophagocytosis (1000X, Giemsa stain).

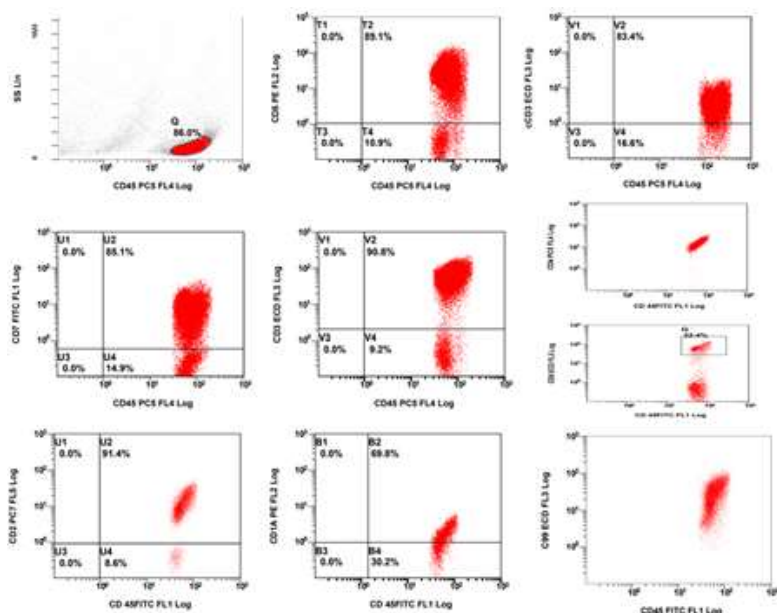


Figure 2. Dot plot between CD45 Vs SS shows 86% cells gated with bright CD45 and low side scatter. The gated population showed moderate expression of CD3, CD4, CD8, CD2, dim to moderate expression of CD5 and CD7, dim expression of CD1a and cCD3 and moderate to bright expression of CD99.

Table 1: Published cases of HLH and T-cell ALL

Age/sex	Reference	HLH Timing Pre/Post ALL (Months)	Infection	Treatment of HLH	Outcome
17/M	12	Post (3)	Not reported	No therapy	HLH at autopsy, death
4/M	13	Post (4)	Not found	No therapy	HLH and relapsed ALL at autopsy: Death
5/F	14	Post (6)	Not found	1,2,4	HLH at autopsy: Death due to ICH
1.5/M	15	Post (3)	Pneumoniae	No therapy	HLH at autopsy: Death due to hemorrhage
12/M	16	Post (second relapse)	E.coli	No therapy	HLH & relapsed ALL at autopsy: Death due to sepsis
15/M	17	Post (third relapse)	CMV, Aspergillosis	No therapy	HLH relapsed ALL, disseminated infection at autopsy: Death
4.5/F	18	Post (16)	Not reported, suspected viral etiology	1	Sepsis, hemorrhage, autopsy refused: Death
2.5/M	19	Post (9)	Prior CMV	8	HLH at autopsy: Death due to HLH
4/M	19	Post (18)	None found	8	HLH at autopsy: Death due to HLH
2/F	19	Post (2.5)	None found	1	HLH at autopsy: Death due to liver failure
5/M	19	Post (14)	Prior EBV	1,5,7	HLH at autopsy: Death due to HLH
2/F	9	Post (induction Ib)	Candida	8	HLH at autopsy: Death due to HLH
10/M	Current report	Concurrent	None found	-	Death due to multisystem organ failure

T-ALL, T acute lymphoblastic leukemia, ICH, Intracranial hemorrhage, BFM, Berlin Frankfurt-Munster. Types of treatment: 1. Steroids, 2. cyclosporine A, 3. Etoposide 4. Vincristine 5. Vinblastine 6. 6-Mercaptopurine, 7. Cyclophosphamide, 8. NHL-BFM95: Cyclophosphamide, dexamethasone, cytarabine, methotrexate, prednisone, ifosamide, etoposide, doxorubicin, vindesine

## Discussion

HLH is primarily a disorder of T cells or NK cells. It is related to the impaired activity of CD8+ cytotoxic T cells in clearing off the antigen. This results in significant interferon-gamma (IF $\gamma$ ) production, leading to hyper immune response and subsequent proliferation of histiocytes that invade tissues. The diagnosis of HLH is based on HLH 2004 guidelines (4). Unless family history or molecular diagnosis consistent with HLH can be established, 5 out of 8 criteria must be fulfilled to diagnose HLH. These include fever, splenomegaly, cytopenias, hypofibrinogenemia or hypertriglyceridemia, hyperferritinemia, elevated soluble CD25, hemophagocytosis in bone marrow, spleen, liver, lymph node, or other tissues, and reduced or absent NK cytotoxicity). Primary HLH is related to perforin, UNC13D, and syntaxin gene mutations and is autosomal recessive (5). Secondary HLH has many causes, M-HLH is mainly seen in adults and is generally misdiagnosed and has high mortality as the symptoms overlap with other illnesses, so its diagnosis is challenging. Its recognition, diagnosis, and treatment are important due to its fatal course (6). In some patients with B and T cell lymphomas, the incidence of HLH has increased to 50% (7). The tumors associated with HLH are mostly hematological neoplasms comprising B-cell lymphoma (31.8%), T or NK cell-lymphoma/leukemia (3.2%), and other non-specified hematological neoplasms (14.4%). Non-specified neoplasms and solid tumors account for 3.2% and 3.1 %, respectively (1). The secretion of pro-inflammatory cytokines like TNF-alpha and IL-6 from malignant cells leads to HLH by activating macrophages (8). The possibility of infection couldn't be ruled out entirely as laboratory investigations showed increased CRP. The literature revealed a total of 13 cases reported as T-ALL and 15 cases as B-ALL

with-associated HLH except in a study done by Celkan (5), where 18 cases of ALL with HLH were seen. However, not sub-categorized into B and T cells. HLH occurred after diagnosis in patients with T-ALL, and all patients had a fatal outcome. Similarly, Singh et al. (9) described M-HLH in two cases of AML, one of Hodgkin's lymphoma, one of B-cell ALL, and one of T-cell ALL were on chemotherapy. Previously, in pediatric ALL, only a single case of B-ALL developing HLH during chemotherapy following bacterial tonsillitis has been reported (10). Thakur et al. reported a case of AML-M2 diagnosed in a child who initially presented with peritonsillitis, which was culture positive for *Streptococcus* (11). Compared to other cases in literature, our case is novel as HLH was diagnosed concurrently at the time of diagnosis of leukaemia and the patient had a unique presentation with membranous tonsillitis (12-19).

## Conclusion

In conclusion, a rare presentation such as membranous tonsillitis can masquerade the actual diagnosis and should alert the clinician for further workup. HLH should be considered in all cases of ALL presenting with pancytopenia and hepatosplenomegaly since the symptoms mimic other illnesses, which may lead to misdiagnosis of the disease. Prompt diagnosis and treatment are the mainstays of therapy. Hematopoietic stem cell transplantation is the only practical option for leukemia-associated HLH.

## Conflicts of Interest

The authors declare that there is no conflict of interests.

## References

1. Ramos-Casals M, Brito-Zeron P, Lopez-Guillermo A, Khamashta M, Bosch X. Adult Hemophagocytic syndrome. *Lancet* 2014; 383(9927):1503-1516.

2. Siena E, Cetica V, Piccin A, Gherlinzoni F, Carlo Sasso F, Rabusin M et al. Familial Hemophagocytic lymphohistiocytosis may present during childhood: Clinical and genetic features of a small series. *PLoS One* 2012; 7(9):e44649-e44653.
3. Usmani GN, Woda BA, Newburger PE. Advances in understanding the pathogenesis of HLH. *Br J Haematol* 2013; 161(5):609-622.
4. Henter JI, Horne A, Aricò M, Egeler RM, Filipovich AH, Imashuku S. et al. HLH 2004: Diagnostic and therapeutic guidelines for Hemophagocytic lymphohistiocytosis. *Pediatr Blood Cncr* 2007; 48(2):124-127.
5. Celkan T, Berrak S, Kazanci E, Ozyurek E, Unal S, Ucar C, et al. malignancy associated Hemophagocytic lymphohistiocytosis in pediatric cases. A multi center study from Turkey. *Turk J Pediatr* 2009; 51(3):207-213.
6. Wang H, Xiong L, Tang W, Zhou Y and Li F. A systematic review of malignancy- associated Hemophagocytic lymphohistiocytosis that needs more attentions. *Oncotarget* 2017; 8(35):59977-59985.
7. Machaczka M, Vaktnas J, Klimkowska M, Hagglund H. Malignancy associated Hemophagocytic lymphohistiocytosis in adults: a retrospective population-based analysis from a single center. *Leuk Lymphoma* 2011; 52(4):613-619.
8. O'Brien M, Lee-Kim Y, George TI, McClain KL, Twist CJ, Jeng M. Precursor B-cell acute lymphoblastic leukemia presenting with hemophagocytic lymphohistiocytosis. *Pediatr Blood cancer* 2008; 50(2):381-383
9. Singh A, Dawman L, Seth R. Malignancy associated hemophagocytic lymphohistiocytosis in children. *J Cancer Res Ther* 2018; 14(3):559-562.
10. Kakihara T, Imai C, Kaneko T, Tanaka A, Uchiyama M. Atypical Hemophagocytic Lymphohistiocytosis Following Bacterial Tonsillitis in Acute Lymphoblastic Leukemia. *Leuk. Lymphoma* 2003; 44(7):1247-1248
11. Thakur JS, Mohindroo NK, Sharma DR, Mohindroo S, Thakur A. Tonsillitis with acute myeloid leukemia: a case series for caution. *Ear Nose Throat J* 2013; 92(4-5): E22-23
12. Clark BS, Dawson PJ. Histiocytosis medullary reticulosis presenting with a leukemia blood picture. *Am J Med* 1969; 47:314-317
13. Chen TK, Nesbit ME, McKenna R, Kersey JH. Histiocytic medullary reticulosis in acute lymphoblastic leukemia of T cell origin. *Am J Dis Child* 1976; 130(11):1262-1264.
14. Karcher DS, Head DR, Mullins JD. Malignant histiocytosis occurring in patients with acute lymphoblastic leukemia. *Cancer* 1978; 41(5):1967-1973.
15. Starkie CM, Kenny MW, Mann JR, Cameron AH, Hill FGH. Histiocytic medullary reticulosis following acute lymphoblastic leukemia. *Cancer* 1981; 47(3):537-544
16. Liang DC, Chu ML, Shih CC. Reactive histiocytosis in acute lymphoblastic leukemia and non-Hodgkin's lymphoma. *Cancer* 1986; 58(6):1289-1294.
17. Takasaki N, Kaneko Y, Maseki N, Sakurai M, Shimamura K, Takayama S. Hemophagocytic T-cell acute lymphoblastic leukemia with a novel t(11:14)(p15:11) chromosome translocation. *Cancer* 1987; 59:424-428.
18. Milkha A, Madan V, Leonids JC, Valderrama E. Liver and spleen MRI findings in virus-associated hemophagocytic syndrome in a patient with acute lymphoblastic leukemia. *Pediatr Radiol* 1998; 28:920-922.
19. Trebo MM, Attarbaschi A, Mann G, Minkov M, Kornmuller R, Gadner H. Histiocytosis following T-acute lymphoblastic leukemia. A BFM study. *Leuk Lymphoma* 2005; 46(12):1735-1741.