Case Report *Iran J Ped Hematol Oncol. 2022, Vol 12, No 1, 68-75*

Therapy-related myeloid leukemia following Pleuropulmonary blastoma: A case report

Nahid Reisi[1,*], Pardis Nematolahy[2]

1. Department of Pediatric Hematology and Oncology, Faculty of Medicine, Child Growth and Development Research Center and Isfahan Immunodefciency Research Center, Seyed Al-Shohada Hospital, Isfahan University of Medical Sciences, Isfahan, Iran.
2. Department of Pathology, School of Medicine, Isfahan University of Medical Sciences, Isfahan, Iran.

*Corresponding author: Dr. Nahid Reisi, Department of Pediatric Hematology and Oncology, Sayed-AL Shohada Hospital, Isfahan, Iran. Tel: 031-32350210, Fax: 031-332363224. E-mail: reisi@med.mui.ac.ir. ORCID ID: 0000 0002 1240 0330.

Received: 12 August 2021 **Accepted:** 30 December 2021

Abstract

The development of secondary malignancy (SM) is the most worrisome long-term complication of childhood cancer. Acute myeloid leukemia is the most prevalent neoplasm that occurs after treatment with alkylating agents and topoisomerase II inhibitors. Pleuropulmonary blastoma (PPB) is a rare lung neoplasm in children. Type II and type III of this cancer are markedly aggressive and have a recurrent nature. Chemotherapy, radiation therapy, and hematopoietic stem cell transplant (HSCT) are treatment modalities that make these patients prone to secondary malignancy. Here was presented and discussed a case of myeloid leukemia 3.5 years after treatment of Pleuropulmonary blastoma in a 5.5-year-old boy who was a candidate for high dose chemotherapy and autologous stem cells transplant (auto-SCT) because of frequent recurrence and lack of response to chemotherapy and radiation therapy. It seems this is the first reported case of therapy-related myeloid leukemia (t-AML) after PPB in children. Awareness of the creation of this complication following administration of cytotoxic therapies in the treatment of solid tumors will increase physician attention in the selection of treatment modality as well as the counseling of patients at the time of diagnosis.

Keywords: Alkylating Agents, Leukemia, Lung Neoplasms, Topoisomerase II Inhibitors

Introduction

With progress in the treatment of pediatric malignancies, the 5-year survival rate for all these cancers has been raised from 58% to greater than 80% over the past 40 years (1). Although it is a great success, it is associated with increased long-term sequels. The creation of secondary malignancy (SM) is the most worrisome long-term complication of childhood cancer (2), mostly within 10 years after a primary cancer diagnosis. The Childhood Cancer Survivor Study (CCSS) shows a 6-fold relative risk (RR) of secondary malignancy in childhood cancer survivors compared to the general population (3). Also, the incidence of therapy-related myeloid leukemia (t-AML) has been reported between 0.5-6% (2, 4).

Factors related to the primary treatment and the host factors (including altered drug metabolism or DNA repair) are both involved in this issue (1, 5). The most known chemotherapy agents that increase the probability of SM are alkylating agents and topoisomerase II inhibitors include epipodophyllotoxins, and anthracyclines (1, 2, 5, 6)

The RR for an SM following administration of alkylating agents is 1.4–2.2 (7) and the incidence following topoisomerase II inhibitors has been reported up to 8.3% (8). Usually, acute myelogenous leukemia (AML) is SM that occurs after treatment with alkylating agents and topoisomerase II inhibitors and it is defined as t-AML (1). Chromosomal deletions or balanced translocation which are induced by these agents like

[Downloaded from ijpho.ssu.ac.ir on 2026-11-25]

[DOI: 10.18502/ijpho.v12i1.8365]

monosomy or partial deletion in chromosomes 5 and/or 7 following chemotherapy with alkylating agents or radiation and balanced translocation that more involve chromosome bands 11q23 or 21q22, PML/RARA genes or t(8;21)(q22;q22) following topoisomerase II inhibitors are responsible for this disease (2, 6). Although rarely 11q23 and 21q23 abnormalities were identified in t- AML following doxorubicin, cyclophosphamide, and radiation therapy (5).

Therapy-related AML often appears within 2–3 years of the first therapy with topoisomerase II inhibitors and, in some cases, within 1 year and 5–7 years after alkylating agents. This different latency is related to the type of DNA damage caused by these agents (1, 2, 5, 9,). Usually, after taking alkylating agents and/or radiotherapy, a preceding myelodysplastic syndrome (MDS) appears before AML. Most following chemotherapy with alkylating agents M1 and M2 subtypes are seen but often subtype M4 and M5 are the most t- AML after topoisomerase II inhibitors or anthracyclines. Although other subtypes such as M2 and M3 can be seen (2). Therapy-related AML following anthracyclines resembles those of epipodophyllotoxins but with other chromosomal abnormalities (1, 5, 6, 9).

Dosage of drugs, treatment schedule, use of other chemotherapy drugs, and supportive therapies are all effective in the development of t-AML (5, 6, 9). In the use of alkylating agents, the high cumulative doses, and the use of epipodophyllotoxins, the schedule of dosing is known as a risk factor in developing t-AML (1, 5, 8).

Every other week schedule versus weekly or twice- weekly and five consecutive days administration versus intermittent schedule is associated with lower incidence of t-AML (1, 8). In the development of t-AML after anthracyclines, although a high cumulative dose is indicated to be a risk factor, the role of dosage and treatment schedule is yet not proven (5).

Clinical manifestations and laboratory findings of therapy-related AML are similar to the new AML and the treatment plan is based on the patient performance status and cytogenetic and molecular features and includes chemotherapy or hematopoietic stem cell transplant (HSCT). Usually, the outcome of this form of myeloid leukemia is poor (6, 10) and etoposide-related cases are poorer than alkylating agents (2). The treatment response in M3 (t: 15-17) and M2 (t: 8-22) subtypes and inv (16) is similar to new cases, but their overall survival is lower (5, 6, 11).

Here was presented and discussed a case of t-AML after PPB in a 5.5-year-old boy who was a candidate for autologous stem cells transplant because of frequent recurrence and lack of response to treatment. According to the author's information, this is the first case of t-AML after PPB treatment.

Case Report

A 26 month-old boy was referred to the Imam Hussein Hospital in Isfahan, Iran, with a complaint of cough, fever, and shortness of breath from 20 days ago in 2013. The chest x-ray showed an extensive right effusion which was confirmed by ultrasound. This fluid drained by placing a chest tube (Figure 1-A). Subsequent ultrasounds revealed a heterogeneous mass measuring 14×10× 3 cm in the right lower lobe, which was also confirmed by a CT scan (Figure 1-B). The mass was partially removed.

The gross findings of the pulmonary mass showed multiple fragile gray color fragments measuring 11× 9 × 2 cm. Some fragments appeared in the cyst wall. Microscopic slides revealed a neoplastic proliferation of small primitive round cells which in some areas were throughout the cystic structures. The above cells showed moderate mitotic activity without area of the differentiated chondrosarcoma or anaplasia and PPB type II was diagnosed (Figure 2). Immunohistochemical staining

[Downloaded from ijpho.ssu.ac.ir on 2026-11-25]

[DOI: 10.18502/ijpho.v12i1.8365]

(IHC) also showed positivity for vimentin and negativity for CD117.

The patient received adjuvant chemotherapy (Table I) and was in remission for a year. In 2014, a new mass measuring 2× 1.6× 0.8 cm in the right lower lung appeared again. The patient underwent surgery for the second time and the recurrence of the disease was confirmed by pathology tests.

He received six courses of chemotherapy again (Table I) and was free of the tumor for eight months. Then two nodules (2×1 cm, 2.5×1.3 cm) in the right middle lobe (RML) appeared in a chest CT scan. The patient underwent third surgery and was referred for radiation therapy but three months later, a new nodule appeared on the right lower lobe (RLL) without the involvement of the other sites. The patient underwent surgery again and was referred to a bone marrow transplant (BMT) in August 2016.

In evaluations of pre- BM transplant, bone marrow aspiration smears showed neoplastic proliferation of blasts with fine chromatin and obvious nucleoli. Some contained granules and about 25% of all nucleated cells with more than 10% maturing granulocytes in nonerythroid series (AML-M2) (Figure 3), which lineage assignment was confirmed by multicolor flow cytometry (Figure 4). Cytogenetic study on marrow sample showed t (8;21) and molecular study for FLT3/ITD mutation was negative.

After chemotherapy with the modified MRC 15 protocol and creating remission, the patient was referred for allogeneic stem cells transplant (allo-SCT). Unfortunately, the patient died a few days after the transplant. The summary of performed treatments and outcomes has been shown in table 1.

A



B

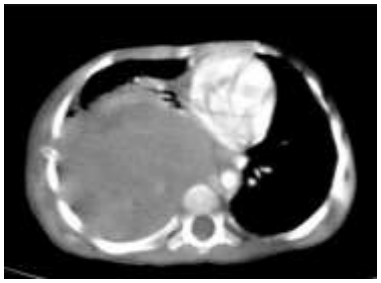

Figure 1.A: Chest radiograph: massive right-sided pleural effusion. B: A contrast-enhanced chest CT scan reveals a large right lower lobe heterogeneous mass (measuring 14× 10× 3 cm) that displaces the great vessels.

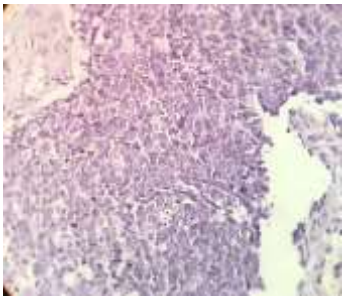

Figure.2: This field displays the proliferation of blastemal cells. X400

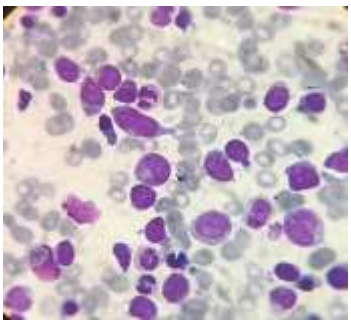

Figure.3: Bone marrow aspiration slides show about 25% blast. X1000

[Downloaded from ijpho.ssu.ac.ir on 2026-11-25]

[DOI: 10.18502/ijpho.v12i1.8365]

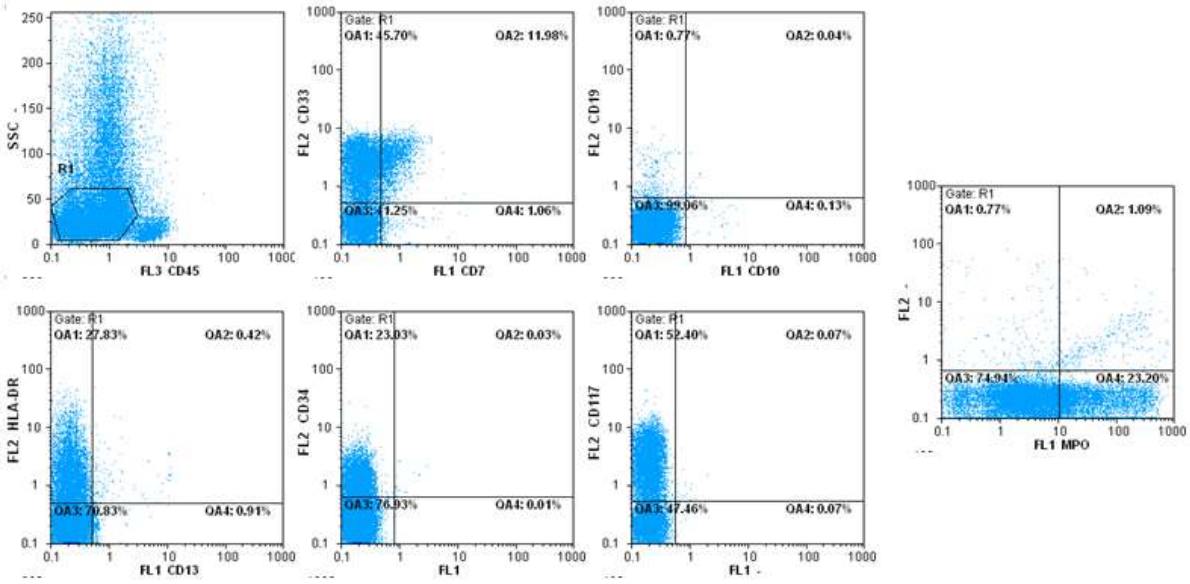

Figure.4: Multicolor flow cytometry dot plots of bone marrow aspiration

Table I: Summary of performed treatments in case of t- AML following pleuropulmonary blastoma

Time of treatment	Type of treatment	Treatment outcome
At the time of diagnosis of PPB (2013)	Surgery (Partial excision) + adjuvant chemotherapy including ifosfamide 1800 mg/m2 × 5 days, doxorubicin 30 mg × 1day alternate with ifosfamide 1800 mg/m2 and etoposide100 mg/m2 × 5 days (IDo/ IE) q 3 week× 6 courses	**One year complete remission**
The first relapse of PPB (2014)	Surgery (Total excision) + Chemotherapy (ICE protocol) including Ifosphamide 1800 mg/m2 × 3days, Carboplatin 400 mg/m2 × 2 days, Etoposide100 mg/m2 × 3days) q 3-4 week× 6 courses	**Remission eight months**
The second relapse of PPB (2015)	Surgery + Radiation therapy (5040 cGy)	**Three months remission**
The third relapse of PPB (2016)	Surgery (Total excision) and referred for high dose chemotherapy+ auto-SCT	**About 25% of myeloblasts (M2 subtype) in bone marrow**
Secondary AML	Modified MRC 15 protocol: course1& 2 including Daunorubicin 50 mg/m2 IV days 1, 3, 5 Cytosine arabinoside 100 mg/m2, IV bolus, q 12 hours days 1-10 Etoposide 100 mg/m2, IV infusion days 1- 5 Intrathecal cytarabine 50 mg at the time of diagnosis Course 2 is similar to course 1 except that cytosine arabinoside lasts for 8 days	**Bone marrow remission after 2 courses of chemotherapy and referred to an Allogeneic stem cells transplant**

[Downloaded from ijpho.ssu.ac.ir on 2026-11-25]

[DOI: 10.18502/ijpho.v12i1.8365]

[DOI: 10.18502/ijpho.v12i1.8365] [Downloaded from ijpho.ssu.ac.ir on 2026-11-25]

Discussion

Secondary or t-AML often occurs following cytotoxic therapy in malignant or nonmalignant patients and is different from "second de novo AML" (5, 12). This complication can occur after treatment of hematologic and non-hematologic malignancies. Smith et al. reported t-AML and MDS in 306 patients (141 males and 165 females) aged 6-86 years at secondary diagnosis. Eighteen patients were without malignancy and 288 patients with different types of hematologic and non-hematologic malignant disease. One hundred seventeen cases of the malignancies were after solid tumors. Nine cases of them had a previous history of lung cancer: five cases were (56%) after chemotherapy, two cases (22%) after radiotherapy, and 2 cases (22%) following combined modality therapy (12).

Primary lung cancers are rare in children and unlike adults, there is usually no history of contact with external predisposing substances. PPB, inflammatory myofibroblastic tumor, and carcinoid tumor are the most common lung tumor types reported in children (13). PPB is one of the rare cancers in children and about 500 patients reported in the literature (14-18). It appears as a pulmonary or pleural mass with three pathological subtypes: entirely cystic (type I), cystic and solid (type II), and entirely solid (type III) (16). Fever and pulmonary symptoms are the most common presenting symptoms of this tumor (17). Types II and III of disease, because of their aggressive nature and tendency to recurrent have poor outcomes with a 5-year survival rate of about 50% (16, 17). About a quarter of cases are associated with heritable tumor syndrome (DICER1 Syndrome). Messinger et al. revealed familial or constitutional association PPB with other malignancies in 30 families and reported other malignant diseases in PPB patients or their young, close relatives (1, 19).

PPB patients, in addition to their heritable predisposition to malignancy, due to their treatment modalities, are also at the risk of developing secondary cancers. Radiation, chemotherapy drugs, and undergoing HSCT are the main therapeutic factors. Cases of PPB are usually treated with chemotherapeutic drugs similar to protocols of rhabdomyosarcoma (20) and more include cyclophosphamide, doxorubicin, ifosfamide, etoposide, and vincristine (21). More of them are predisposing factors for occurring t-AML (22).

Although chemotherapy drugs including alkylating agents, topoisomerase II inhibitors, and anthracyclines are in the head of drugs that induce t-AML, non-chemotherapeutic agents such as granulocyte colony-stimulating factors (23-25), cardioprotectants such as dexrazoxane (a topoisomerase II inhibitor), immunosuppressants (such as azathioprine) and radioimmunotherapeutic agents (like yttrium-90 ibritumomabtiuxetan and iodine-131 tositumomab) are other agents that may be involved (6, 9).

There are contradictory reports about the effect of G-CSF on the increased risk of secondary leukemia in children. Relling et al. showed an increased incidence of t-AML in leukemic children who received G-CSF plus etoposide and anthracyclines ± cyclophosphamide (26). Conversely, Bhatia et al. could not prove this relationship with Ewing sarcoma (27). In adults, although some studies on survivors of breast cancer established this association (5), Patt et al. did not show this association (28). Therefore, it is not clear whether G-CSF can induce therapy-related leukemia, or enhance leukemogenesis associated with chemotherapeutic drugs.

Concomitant administration of chemotherapy agents like epipodophyllotoxin with alkylating agents (5, 9), asparaginase, or antimetabolites

[Downloaded from ijpho.ssu.ac.ir on 2026-11-25]

[DOI: 10.18502/ijpho.v12i1.8365]

(e.g., mercaptopurine or methotrexate) can be associated with an increased incidence of secondary leukemia (5).

Hematopoietic stem cell transplants and rarely solid organ transplants because pre-transplant therapy and immunosuppression caused by transplantation are at risk of myeloid leukemia. Usually, the manifestations of secondary leukemia in transplant survivors are similar to those caused by an alkylating agent (29, 30).

Radiation therapy because of DNA damage within bone marrow cells is another important risk factor for occurring t-AML and especially when added to chemotherapy, it increases the risk even more (5, 6).

In addition to therapy-related factors, certain factors of the host such as specific single nucleotide polymorphisms (SNPs) of detoxification enzymes and polymorphisms of DNA repair genes can also play an important role in occurring t-AML (5, 6, 9).

"Polymorphisms that reduce the enzymatic activity of thiopurine methyltransferase, a variant of CYP3A that affects the production of a DNA-damaging metabolite of epipodophyllotoxins and polymorphisms in glutathione S-transferase P1and NAD (P) H: quinine oxidoreductase (NQO1) are associated with an increased risk of t-AML after chemotherapy" (5).

Attention to rarity and poor outcome of PPB, some patients survive, therefore it seems to occur of t-AML following PPB. Although it is possible, it is a rare condition. The present case regarding the patient's age, the time interval between the primary malignancy (PPB) and appearance of AML (about 3.5 years) and absence of myelodysplasia before the occurrence of AML and presence of t(8;22) in bone marrow cytogenetic studies, It looks like that chemotherapy with topoisomerase II inhibitors (etoposide) has been the main factor for t-AML although the role of concurrent administration of alkylating agents, anthracyclines, G-CSF should not be ignored and due to limitation in genetic studies, the role of host factors was unclear. In general, the prognosis is poor in this case, even with a hematopoietic stem cell transplant.

Conclusion

Awareness of occurring second malignant neoplasm following administration of cytotoxic therapies in the treatment of solid tumors will increase physician attention in the selection of treatment modality as well as the counseling of patients at the time of primary diagnosis.

Acknowledgements

The authors thank the patients' families for their sincere corporation.

Conflicts of Interest

There is no conflict of interest.

References

1. Choi DK, Helenowski I, Hijiya N. Secondary malignancies in pediatric cancer survivors: perspectives and review of the literature. Int J Cancer 2014; 135(8): 1764-1773.

2. Sneha LM, Arockia J, Suman FR, Khethan V. Secondary acute myeloid leukemia in a child treated for retinoblastoma: A case report with review of literature. J Family Med Prim Care 2020; 9(11): 5796-5798.

3. Friedman DL, Whitton J, Leisenring W, Mertens AC, Hammond S, Stovall M, et al. Subsequent neoplasms in 5-year survivors of childhood cancer: the Childhood Cancer Survivor Study. J Natl Cancer Inst 2010; 102(14): 1083–1095.

4. Schwartz JR, Ma J, Kamens J, Westover T, Walsh MP, Brady SW, et al. The acquisition of molecular drivers in pediatric therapy-related myeloid neoplasms. Nat Commun 2021; 12(1): 985.

5. Hijiya N, Ness KK, Ribeiro RC, Hudson MM. Acute leukemia as a

[Downloaded from ijpho.ssu.ac.ir on 2026-11-25]

[DOI: 10.18502/ijpho.v12i1.8365]

secondary malignancy in children and adolescents: current findings and issues. Cancer 2009; 115(1):23-35.
6. Godley LA, Larson RA. Therapy-related myeloid leukemia. Semin Oncol 2008; 35(4):418-429.
7. Mertens AC, Liu Q, Neglia JP, Wasilewski K, Leisenring W, Armstrong GT, et al. Cause- specific late mortality among 5-year survivors of childhood cancer: the Childhood Cancer Survivor Study. J Natl Cancer Inst 2008; 100: 1368–1379.
8. Hijiya N, Hudson MM, Lensing S, Zacher M, Onciu M, Behm FG, et al. Cumulative incidence of secondary neoplasms as a first event after childhood acute lymphoblastic leukemia. JAMA 2007; 297(11):1207-1215.
9. Ezoe S. Secondary leukemia associated with the anti-cancer agent, etoposide, a topoisomerase II inhibitor. Int J Environ Res Public Health 2012; 9(7):2444-2453.
10. Brown CA, Youlden DR, Aitken JF, Moore AS. Therapy-related acute myeloid leukemia following treatment for cancer in childhood: A population-based registry study. Pediatr Blood Cancer 2018; 65(12):e27410.
11. Attarbaschi A, Carraro E, Ronceray L, Andrés M, Barzilai-Birenboim S, Bomken S, et al. Second malignant neoplasms after treatment of non-Hodgkin's lymphoma-a retrospective multinational study of 189 children and adolescents. Leukemia 2021; 35(2):534-549.
12. Smith SM, Le Beau MM, Huo D, Karrison T, Sobecks RM, Anastasi J, et al. Clinical-cytogenetic associations in 306 patients with therapy-related myelodysplasia and myeloid leukemia: the University of Chicago series. Blood 2003; 102(1):43-52.
13. Yu DC, Grabowski MJ, Kozakewich HP, Perez-Atayde AR, Voss SD, Shamberger RC, et al. Primary lung tumors in children and adolescents: a 90-year experience. J Pediatr Surg 2010; 45(6):1090-1095.
14. Dishop MK, Kuruvilla S. Primary and metastatic lung tumors in the pediatric population: a review and 25-year experience at a large children's hospital. Arch Pathol Lab Med 2008; 132(7):1079-1103.
15. Reisi N, Yosefian S, Namatollahi P. Pleuropulmonary blastoma: report of 2 cases. Iran J Ped Hematol Oncol 2017; 7 (1): 63-67.
16. Camilo Neto, Carlos; Kato, Sabrina Hashimoto; Pantoja, Laudreísa da Costa; Costa, Cecília Maria Lima; Cunha, Isabela Werneck. Pleuropulmonary blastoma type II: a case report. Appl Cancer Res 2011; 30(3): 110-113.
17. Abbo O, Pinnagoda K, Brouchet L, Leobon B, Savagner F, Oliver I, et al. Wilms tumor, pleuropulmonary blastoma, and DICER1: case report and literature review. World J Surg Oncol 2018; 16(1):164.
18., Messinger YH, Stewart DR, Priest JR, Williams GM, Harris AK, Schultz KA, et al. Pleuropulmonary Blastoma: A Report on 350 Central Pathology–Confirmed Pleuropulmonary Blastoma Cases by the International Pleuropulmonary Blastoma Registry. Cancer 2015; 121(2):276-285.
19. Messinger Y.H, Dehner L.P, Hill D.A, Williams G, Priest J.R. Pleuropulmonary Blastoma and its association with other childhood neoplasms. J Clin Oncol 2004: 22(14): 8542-8542.
20. Carli M1, Colombatti R, Oberlin O, Bisogno G, Treuner J, Koscielniak E, et al. European intergroup studies (MMT4-89 and MMT4-91) on childhood metastatic rhabdomyosarcoma: final results and analysis of prognostic factors. J Clin Oncol 2004; 22(23): 4787-4794.
21. Paliwal N, Gupta K, Mullick S, Dewan RK, Katiyar S. Pleuropulmonary blastoma in an adult: A case report. Int J Case Rep Imag 2013; 4(1):46–50.
22. Cho HW, Choi YB, Yi ES, Lee JW, Sung KW, Koo HH, et al. Therapy-related myeloid neoplasms in children and adolescents. Blood Res 2016; 51(4):242-248.

[Downloaded from ijpho.ssu.ac.ir on 2026-11-25]

[DOI: 10.18502/ijpho.v12i1.8365]

23. Smith RE, Bryant J, DeCillis A, Anderson S. Acute myeloid leukemia and myelodysplastic syndrome after doxorubicin-cyclophosphamide adjuvant therapy for operable breast cancer: the National Surgical Adjuvant Breast and Bowel Project Experience. J Clin Oncol 2003; 21(7):1195–1204.
24. Hershman D, Neugut AI, Jacobson JS, Wang J, Tsai WY, McBride R, et al. Acute myeloid leukemia or myelodysplastic syndrome following use of granulocyte colony-stimulating factors during breast cancer adjuvant chemotherapy. J Natl Cancer Inst 2007; 99 (3):196–205.
25. Le Deley MC, Suzan F, Cutuli B, Delaloge S, Shamsaldin A, Linassier C, et al. Anthracyclines, mitoxantrone, radiotherapy, and granulocyte colony-stimulating factor: risk factors for leukemia and myelodysplastic syndrome after breast cancer. J Clin Oncol 2007; 25 (3):292–300.
26. Relling MV, Boyett JM, Blanco JG, Raimondi S, Behm FG, Sandlund JT, et al. Granulocyte colony-stimulating factor and the risk of secondary myeloid malignancy after etoposide treatment. Blood 2003; 15; 101(10):3862-3867.
27. Bhatia S, Krailo MD, Chen Z, Burden L, Askin FB, Dickman PS, et al. Therapy-related myelodysplasia and acute myeloid leukemia after Ewing sarcoma and primitive neuroectodermal tumor of bone: A report from the Children's Oncology Group. Blood 2007; 109(1): 46-51.
28. Patt DA, Duan Z, Fang S, Hortobagyi GN, Giordano SH. Acute myeloid leukemia after adjuvant breast cancer therapy in older women: understanding risk. J Clin Oncol 2007; 25(25):3871–3876.
29. Hake C, Graubert T, Fenske T. Does autologous transplantation directly increase the risk of secondary leukemia in lymphoma patients? Bone Marrow Transplant 2007; 39(2): 59–70.
30. Akhtari M, Bhatt VR, Tandra PK, Krishnamurthy J, Horstman H, Dreessen A, Chen PX, et al. Therapy-related myeloid neoplasms after autologous hematopoietic stem cell transplantation in lymphoma patients. Cancer Biol Ther 2013; 4(12):1077-1088.

[Downloaded from ijpho.ssu.ac.ir on 2026-11-25]

[DOI: 10.18502/ijpho.v12i1.8365]