

Successful Treatment of Bilateral Pulmonary Hydatid Cysts in a Child with Acute Myeloid Leukemia

Büşra Topuz Türkcan^{1*}, Zühre Kaya¹, Sevgi Daşdemir¹, Merve Yazol², Merve Şatır Türk³, İsmail Tombul³, Cüneyt Kurul³, Tuğba Bedir Demirdağ⁴, Serap Kirkiz Kayalı¹, Ülker Koçak¹

1. Department of Pediatric Hematology, School of Medicine, Gazi University, Ankara, Turkey

2. Department of Pediatric Radiology, School of Medicine, Gazi University, Ankara, Turkey

3. Department of Thoracic Surgery, School of Medicine, Gazi University, Ankara, Turkey

4. Department of Pediatric Infectious Diseases, School of Medicine, Gazi University, Ankara, Turkey

*Corresponding author: Dr. Büşra Topuz Türkcan, Department of Pediatric Hematology, School of Medicine, Gazi University, Ankara, Turkey, Email: bsrtopuz@gmail.com. ORCID ID: 0000-0002-8941-3754

Received: 02 March 2022

Accepted: 25 Decemebr 2022

Abstract

Few data are available about hydatid cysts in patients with malignancy; however, these have rarely been described in association with leukemia. The purpose of this report was to present an unusual case of coexisting leukemia and pulmonary hydatid cysts. This study presented a 13-year-old boy with acute myeloid leukemia who was diagnosed with bilateral pulmonary hydatid cysts after the completion of chemotherapy and successfully treated with surgery and albendazole. Managing hydatid cysts in patients with leukemia is difficult, and these individuals are also at risk of developing ruptured and infected cysts during chemotherapy. Based on our experience with this case, an oncologist could postpone surgery until the chemotherapy was completed and begin albendazole if hydatid cysts were detected.

Keywords: Acute Myeloid Leukemia, Children, Hydatid Cysts

Introduction

Hydatid cyst is a zoonotic disease that is transmitted to humans by contaminated food with the organism named *Echinococcus granulosus*. The parasite completes its life cycle in animals such as dogs and wolves fed with raw meat-based diets. Most cases have a solitary cyst; however, multiple cysts or multiple organ involvements have also been reported in a few cases (1). It has been reported that the solitary cyst is usually localized in the right side of the lung, and bilateral localization is rarely published (2). Although there are numerous cases of hydatid cysts during the screening of solid tumors, only one case with hydatid cysts is reported in leukemia (3, 4). To our knowledge, this is the first report of successful treatment of bilateral pulmonary hydatid cysts in a child with acute myeloid leukemia (AML).

Case Report

A 13-year-old boy was referred to our hospital for screening for the cause of cytopenia and leukocytosis. He had also a fever and cough on admission. He was found to have splenomegaly and abnormal breathing findings (tachypnea and dyspnea) on his physical examination. Oxygen saturation was decreased on his follow-up. Chest X-ray (CXR) showed two nonspecific well-demarcated nodular lesions (Figure 1A). Unenhanced chest computed tomography (CT) revealed well-defined masses, measuring 2.5 cm round lesions located in the posterior basal segments of both lower lobes (Figure 2A). Diffused non-lobular ground-glass opacities were also detected bilaterally (Figure 2 B). The radiologic findings were considered pulmonary leukemic infiltrations and/or pulmonary infections at diagnosis. Laboratory examinations showed hemoglobin of 9.2 g/dL, leukocyte

count of 84.190/mm³ with a differential of 47 % blasts, platelet count of 66.000/mm³ and no eosinophils. The serum C-reactive protein level was 204 mg/dL. Bone marrow aspiration showed diffuse infiltrations of blastic cells with a rare single Auer rod. The patient was diagnosed with t (8;21) positive AML. After broad-spectrum antibiotics were started for possible pulmonary infections, respiratory distress improved gradually in a couple of days. Chemotherapy with AML-MRC-12 protocol was commenced after the regression of pulmonary symptoms. The patient who had good risk criteria for AML received a total of 4 cycles of chemotherapy according to the AML-MRC-12 protocol. All febrile neutropenic episodes were treated with broad-spectrum antibiotics. Liposomal amphotericin B for empirical therapy was used in only two febrile neutropenic episodes. Over the next 18 months of the end of chemotherapy, he continued to be in complete remission. However, in the 18th month of follow-up, he presented with fever, cough, and dyspnea. CXR was performed at the emergency department and showed a large well-defined thick-walled cystic lesion with an air-fluid level in the right lower lobe. Also, another large, well-defined, rounded homogeneous mass was observed in the left lower lobe (Figure 1 B). Chest CT revealed a thick-walled cyst measuring 9x6 cm in the right lower lobe, containing fluid, air, and a floating membrane, indicating a complicated cyst rupture and communication with bronchioles. There were also adjacent inflammatory pulmonary opacities and pleural effusion. The cyst in the left lower lobe measured 8x6 cm and contained only fluid, with no cavitation or rupture (Figure 2C-2D). The lesions in the lower lobes of the lungs were thought to be compatible with pulmonary hydatid cysts or leukemic infiltration. It was decided to perform bilateral thoracic surgery. Both pathology reports indicated a hydatid cyst. Abdominal ultrasound and cranial CT

revealed no cystic lesions. Before being diagnosed with leukemia, the patient was living on a farm and had frequent contact with dogs. Cystotomy-capitonnage was performed on the left lung via thoracotomy after the patient's clinical condition improved and hypoxia resolved. Following three weeks of antibiotic treatment, a thoracotomy was used to perform a cystotomy on the right lung. The ruptured cystic region was then irrigated with saline solution and diluted with 10% povidone-iodine solution. Wedge resection was used to remove the destroyed lung parenchyma. On the cyst cavity, capitonnage was performed. Following surgery, albendazole was prescribed. The patient's initial chest X-ray and chest CT at the time of admission were reevaluated. On radiography, two radiopaque nodular lesions in the right retro-diaphragmatic region were barely visible. Furthermore, the median CT density of all nodular lesions was less than 13 Hounsfield units, which represents a cyst. At the time of diagnosis, bilateral hypodense cystic masses in the lower lobes on chest CT were thought to be compatible with hydatid cysts. Endobronchial spread or pulmonary edema could be associated with diffused ground-glass opacities. The patient underwent two successful surgical procedures to remove the cysts. He had no reactivation in a ruptured cyst under albendazole therapy for more than 6 months at the time of the study.

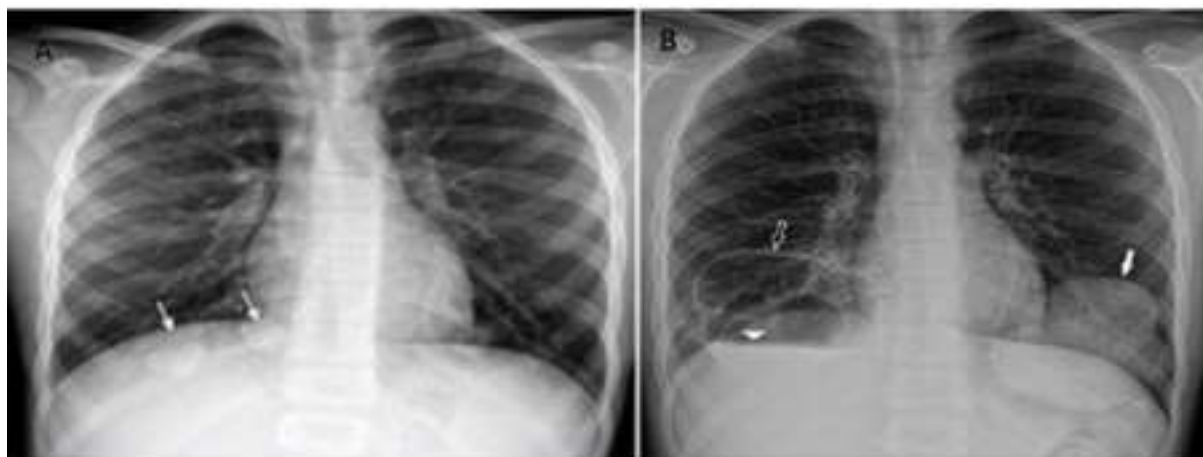


Figure 1. Chest X-ray: Right retro-diaphragmatic nodular lesions at diagnosis (A). Large well-defined thick-walled cystic lesions with an air-fluid level in both lobes in remission (B).

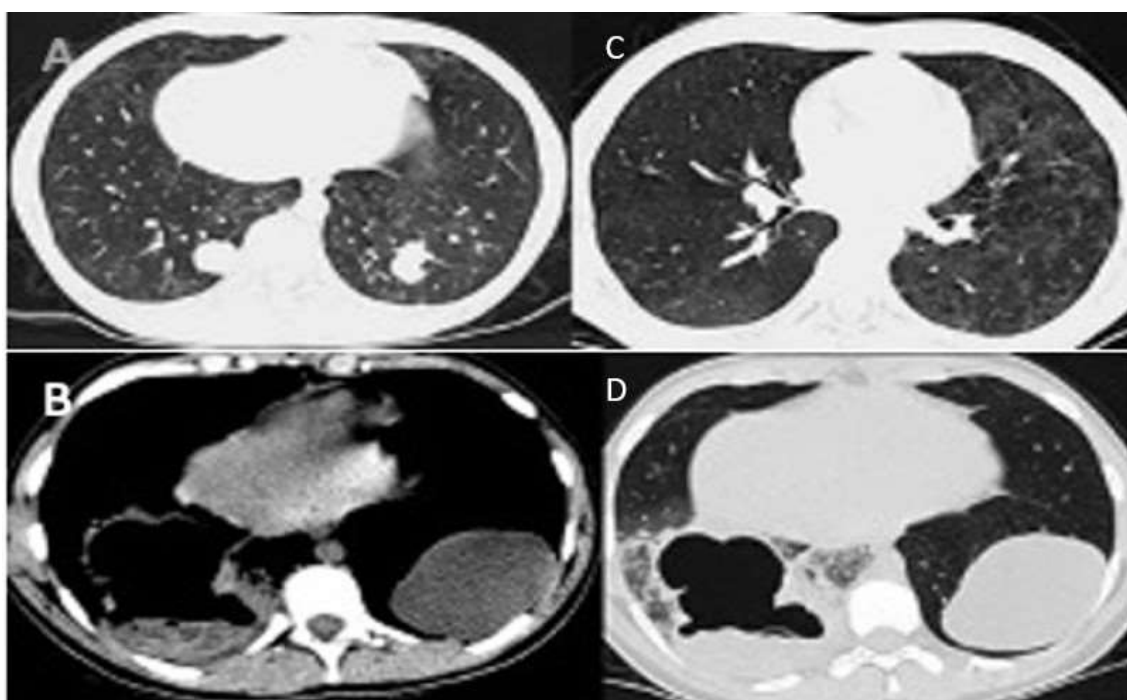


Figure 2. Chest tomography: Well-defined masses, measuring 2.5 cm round lesions in both lungs at diagnosis (A). Bilateral ground glass opacities in both lungs at diagnosis (B). Thick-walled cyst in the right lower lobe measuring 8x6 cm; contained fluid, and air with a floating membrane in remission (C-D).

Discussion

Hydatid cyst is a common and important public health problem in our country (2). In a comprehensive study, hydatid cysts were coincidentally identified in 0.2% of cancer patients and 2% of traumatic patients (3). It has been reported that the cause of the lower frequency occurrence of hydatid cysts in cancer patients can be explained by the antigenic similarity between malignant cells and cysts. Besides this study indicates that these features of cysts may have a protective effect against cancer by causing macrophage activation and inhibiting angiogenesis (3). There is also evidence of antigenic similarity between *Echinococcus granulosus* and pulmonary carcinoma (5). The literature contains little information about the relationship between *Echinococcus granulosus* and malignancy (6). However, hydatid cysts in patients with AML revealed only one case, a 19-year-old boy who had a refractory AML and liver hydatidosis. It has been reported that a hydatid cyst was detected in the liver at the first diagnosis in this patient with AML, however, surgery could not be performed due to leukemia, and antiparasitic drugs could not be given due to toxicity, nevertheless, no increase in cyst size was observed during the treatment (4). Similarly, in our case, although the hydatid cysts were diagnosed after the completion of AML treatment, complications such as cyst infection, growth, or rupture were not observed in all febrile neutropenic episodes during chemotherapy protocol. We assumed that cystic lesions had been camouflaged in the subdiaphragmatic region of the CXR at diagnosis and during each febrile neutropenic episode. A Hydatid cyst of the lung should be operated on as soon as it is diagnosed. The best rates of surgical success, with minimal postoperative morbidity, are achieved when patients are in stable condition at the time of the operation (7). The diagnosis of the hydatid cyst was delayed in our patient; however, two

successful cyst surgeries could have been performed because of the patient's remission status.

Medical treatment before surgery is not recommended in cases with pulmonary hydatid disease unless the inoperable multiple cysts (8). It is indicated only to prevent secondary recurrence in patients if there was a potential risk after the operation (9-11). In our patient, albendazole was started in the postoperative period. Our experience with this case suggested that the delayed diagnosis of the hydatid cyst in our case had no negative effect on the patient's outcome and that diagnosis during the remission period even contributed positively to the success of medical and surgical treatment. Furthermore, leukemia-treating physicians should be cautious in the differential diagnosis of subtle cystic lesions in the subdiaphragmatic region on Chest X-ray.

Ethical approval

Informed consent was obtained from the patient and his family members.

Conflict of interest

The authors had no conflict of interest to declare.

References

1. Rawat S, Kumar R, Raja J, Singh RS, Thingnam SKS. Pulmonary hydatid cyst: Review of literature. J Family Med Prim Care 2019; 30; 8(9):2774-2778.
2. Öztörün Cİ, Demir S, Güney D, Ertürk A, Bayram İlkan G, Karabulut B, Azılı MN, Şenel E. An unsolved problem in developing countries: hydatid cysts in children. Pediatr Surg Int 2021;37(9):1235-1241.
3. Akgül H, Tez M, Unal AE, Keşkek M, Sayek I, Özçelik T. Echinococcus against cancer: why not? Cancer 2003; 98(9):1999-2000.
4. Ali R, Ozkalemkas F, Ozkocaman V, Ozcelik T, Akalin H, Ozkan A,

- Altundal Y, Tunali A. Hydatid disease in acute leukemia: effect of anticancer treatment on echinococcosis. *Microbes Infect* 2005;7(9-10):1073-1076.
5. Yong WK, Heath DD, Savage T. Possible antigenic similarity between pulmonary carcinoma and cysts of *Echinococcus granulosus*. *Br Med J* 1979;1(6176):1463-1464.
 6. van Knapen F. *Echinococcus granulosus* infection and malignancy. *Br Med J* 1980 ; 281(6234):195-6.
 7. Topçu S, Kurul IC, Taştepe I, Bozkurt D, Gülhan E, Cetin G. Surgical treatment of pulmonary hydatid cysts in children. *J Thorac Cardiovasc Surg* 2000;120(6):1097-101.
 8. Kaya Z, Gursel T. A pediatric case of disseminated cystic echinococcosis successfully treated with mebendazole. *Jpn J Infect Dis* 2004; 57(1):7-9.
 9. Kurul IC, Topcu S, Altinok T, Yazici U, Tastepe I, Kaya S, Cetin G. One-stage operation for hydatid disease of lung and liver: principles of treatment. *J Thorac Cardiovasc Surg* 2002;124(6):1212-1215
 10. Aytekin İ, Tülüce K, Demiöz SM, Sayan M, Kurul IC, Demircan S. One-stage operation for hydatid disease of right lung and liver; analysis of the 21 patients. *J. Clin. Anal. Med* 2015;6:316-19.
 11. Kurul IC, Kaya Z, Aslan AT, Celik A. Surgery and Interventional treatments in a child with hydatid cyst. *Gazi Med J* 2011; 22:85-87.