

A Compound Heterozygous of Hb E and Beta Thalassemia Independent of Transfusion: A Rare Case Report

Anju Khairwa MD^{*1}, Mrinalini Kotru MD¹, Pooja Dewan MD¹

1. Departments of Pathology, University College of Medical Sciences & GTB hospital, Delhi- 110095.

*Corresponding author: Dr. Anju Khairwa, Assistant professor, Department of Pathology University College of Medical Sciences & GTB hospital, Delhi- 110095, India. Email: anjukhairwa@gmail.com. ORCID ID: 0000-0001-8514-422X

Received: 12 September 2023

Accepted: 26 May 2024

Abstract

Hemoglobinopathy is now a worldwide problem. Mainly described in Southeast Asian countries. A compound heterozygous form of hemoglobin (Hb) E & β thalassemia was reported to be 50% of all severe forms of thalassemia. Clinical presentation of HbE/ β thalassemia is reported to be moderate to severe anemia. The children usually present at the age range of 7 months to 6.9 years. The clinical severity is affected by genetic factors, including mutation in a chain (β thalassemia), alpha-chain (α thalassemia), amount of adult Hb, and co-inheritance of another hemoglobinopathy. Here, we present a rare case of compound heterozygous of HbE/ β thalassemia, who survived without transfusion and complication until eight years of age. Peripheral blood smears and complete blood count showed microcytic hypochromic anemia. High-performance chromatography showed a compound heterozygous of HbE/ β thalassemia.

Keywords: β thalassemia, Compound, Hemoglobin E, Heterozygous, Transfusion

Introduction

Hemoglobinopathy is now a worldwide problem. They are primarily described in Southeast Asian countries (1). A compound heterozygous form of hemoglobin (Hb) E & β thalassemia was reported to be 50% of all severe forms of thalassemia (1). Minnich et al. first described HbE/ β thalassemia in "Mediterranean Anaemia" from Thailand (2). In India, HbE/ β thalassemia is more prevalent in the Northeast region (3). Clinical presentation of HbE/ β thalassemia reported very severe and fluctuating anemia (4). The clinical severity and variable anemia presentation are affected by genetic factors, including mutation in a chain (β thalassemia), alpha-chain (α thalassemia), amount of adult Hb, and co-inheritance of another hemoglobinopathy (4). Here, we are presenting a rare case of compound heterozygous of HbE/ β thalassemia, who was transfusion independent till the age of eight.

Case Report

An 8-year-old male child has a history of recurrent jaundice (on/off) for one year and took some Ayurvedic medicine for the same. The patient also had paleness for one year, fatigue, and malaise with weight loss for one and a half years. On physical examination, the child had hemolytic facies, malar prominence, high arched upper lip, hepatomegaly 5cm, and splenomegaly 4cm below the costal margin. In his past medical history, the patient did not have a blood transfusion from birth to the age of eight years. The patient was absolutely fine last year. The patient did not have any similar or other significant history. The clinical diagnosis was hemolytic anemia to rule out glucose 6 phosphate dehydrogenase deficiency (G6PD) deficiency. We received samples for laboratory investigation. The complete blood count (CBC) included Hb of 6.5 g/dL, red blood cell count (RBC) of $3.47 \times 10^{12}/L$, total leukocyte count (TLC) of $16.5 \times 10^9/L$, mean corpuscular hemoglobin (MCH) of 18.7 pg, mean corpuscular

volume (MCV) of 63.6 fL, hematocrit (HCT) of 22%, platelet count of $160 \times 10^9/L$, and a corrected reticulocyte count of 9.9%. Biochemical tests revealed lactate dehydrogenase (LDH) of 395 U/L, serum bilirubin of 2.9 mg/dL, alkaline phosphatase (ALP) of 227 U/L, erythrocyte sedimentation rate (ESR) of 23.5 mm/hr, blood urea of 40 mg/dL, serum glutamic-oxaloacetic transaminase (SGOT/AST) of 26 U/L, and serum glutamic-pyruvic transaminase (SGPT/ALT) of 42 U/L. Peripheral blood smear (PS) examination revealed a moderate degree of anisopoikilocytosis comprising predominantly microcytes with plenty of leptocytes, elliptocytes, target cells, and few pencil-shaped, teardrop cells, schistocytes, and polychromatophils with moderate hypochromia (Figure 1a & b). Mentzer index was 18(MCV/RBC). Workup for microcytic hypochromic anemia was advised. Other investigations of the patient, like 1) Sickling test was negative, 2) G6PD screening test was negative, and 3) Iron studies were within normal limits (rule out other differential diagnoses of microcytic hypochromic anemia iron deficiency, anemia due to chronic disease, thalassemia trait, and

sideroblastic anemia, no basophilic stippling on blood smear examination). Hb high-performance liquid chromatography (HPLC) of the patients showed increased Hb A2 (64.5 %) and increased Hb F (26.2%) levels, along with a retention time (RT) of 3.73 and 1.17 minutes, respectively (Figure 2). The findings were consistent with compound heterozygous Hb E/ β thalassemia. The case was suspected on PS for hemoglobinopathy and confirmed with HPLC. The patient's parents were screened for iron studies and HPLC on follow-up. Both parents had normal iron studies. His father is 28 years old, and his HPLC graph showed HbE (29.9%) peak with RT-3.72 minutes, and his mother is 25 years old, and her HPLC graph revealed Hb A2 (5.7%) with RT 3.7 minutes. PS of both parents revealed microcytic and hypochromic anemia. His father was diagnosed as heterozygous for HbE, and his mother was diagnosed as heterozygous for thalassemia. The patient was treated with blood transfusion and chelation therapy after confirmation of diagnosis.

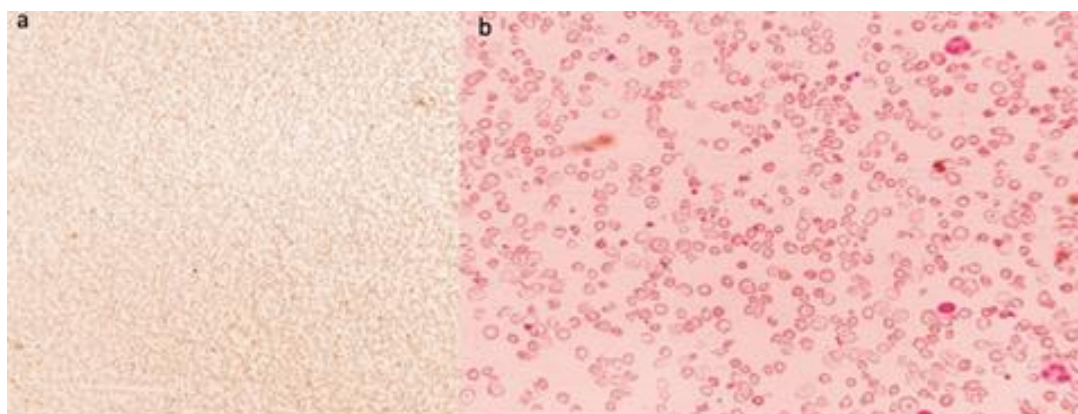


Figure 1. A panel of microphotographs of Microcytic Hypochromic Anaemia; (a) Scanner view (Leishman Stain, x40), (b) revealed a moderate degree of anisopoikilocytosis comprising predominantly microcytes with plenty of leptocytes, elliptocytes, target cells and few pencil-shaped, teardrop cells, schistocytes and polychromatophils with moderate hypothermia (Leishman stain, x400).

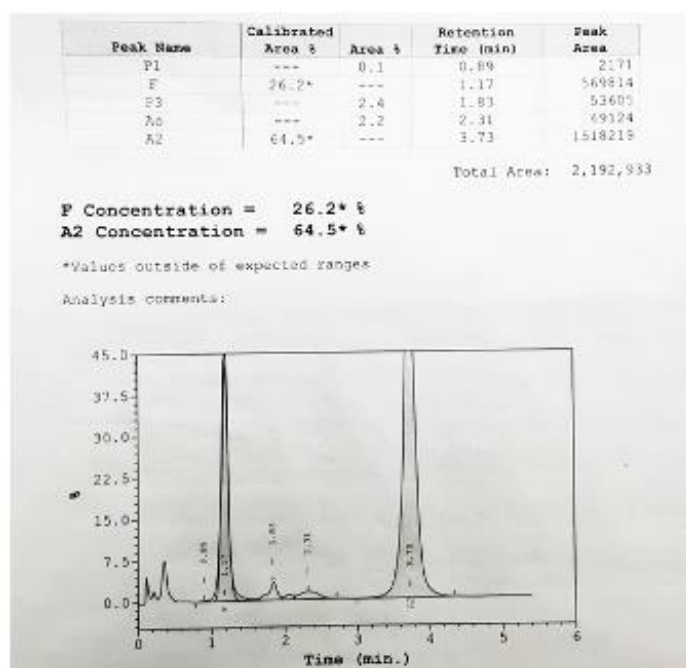


Figure 2. The patient's high-performance liquid chromatography (HPLC) graph revealed Compound Heterozygous Hb E/ β thalassemia.

Discussion

Hb E/ β thalassemia significantly affect health in Southeast Asia. Few studies reported the pathophysiology of Hb E/ β thalassemia. The clinical severity and variability of anemia depend on the instability of Hb E shown in Dapsone-associated Heinz body hemolytic anemia in Cambodian women with HbE traits (5). Ress et al. reported the stability of Hb E in various conditions like globin-chain synthesis analysis with [3 H] leucine at 37°C for two hours (6). They reported that specific activity of the ratio of newly synthesized, tritiated globin chains to old, unlabelled chains should increase linearly with time if the Hb is stable (3). Suppose the new chain of the Hb molecules is unstable. In that case, incorporating radioactive molecules in the Hb chain will lead to a plateau, and the new chains will be precipitated and proteolyzed (6). Chem et al. reported point mutations in both double α - and β -globin chains (Hb Stanleyville II and Hb A2-Stanleyville II)

by Deoxyribonucleic Acid (DNA) sequencing in compound heterozygous HbE/ β^0 thalassemias in a 41-year-old female (7). So, the pathophysiology of compounds heterozygous of Hb E/ β thalassemia depends on the type of mutations. In the index case, molecular investigation was required for further work-up, so we referred the case for molecular investigation. There were few case reports from India of compounds heterozygous of Hb E/ β thalassemia. One case study from South India reported two family members with compound heterozygosity for Hb E & beta-thalassemia from Kerala (8). In comparison to the index case (which has only one case symptomatic and survived without transfusion), in this study, all family (mother and siblings) members were symptomatic and frequently required blood transfusion (8). Parents of index patient were heterozygous of HbE (father) and β thalassemia trait (mother); both were asymptomatic. The range of age presentation is 7 months to 6.9 years

compound heterozygous (HbE/ β thalassemia) (4). In contrast, the index case presented an age of eight years. Anu et al. reported Hb E/ β thalassemia in a child whose mother had β thalassemia trait, whose father had Hb A/E, and one sibling had β thalassemia from North India (9). In this study, the patient was symptomatic at the age of 2 years and required regular blood transfusions (9). Index case had a history of symptoms for the last year and still did not require a blood transfusion. HbE/ β thalassemia is associated with multiple complications like jaundice, cholecystitis, and cholelithiasis related to hemolysis, hypersplenism, infections, thromboembolism, cardiac and pulmonary related, due to repeated blood transfusion leads to iron overload which of diabetes mellitus and infertility (1). Routine screening programs will pick up in the early life of these cases and can avoid complications. Perinatal screening is also essential to the management of these cases. On follow-up index case on regular blood transfusion and chelation therapy, he was well.

Conclusion

Despite various complications associated with hemoglobinopathy, we present an unusual case of compound heterozygous (HbE/ β thalassemia) who survive without transfusion and complications until age eight years.

Ethical Considerations

As per IEC routine case treated in OPD with their benefits and with their consent, further ethical approval not mandatory.

Acknowledgements

None

Author's contributions

Dr Anju Khairwa- collect data, analysed data and write manuscript.

Prof. Mrinalini Kotru- Give opinion and editing manuscript.

Prof. Pooja Dewan- Sent case for workup and wrote all investigations.

Funding

None

Conflict of interest

The authors had no conflict of interest to declare.

References

1. Fucharoen S, Weatherall DJ. The haemoglobin E thalassemias. *Cold spring harb perspect med* 2012; 2(8): a011734 2012-2018.
2. Minnich V, Na-Nakorn S, Chongchareonsuk S, Kochaseni S. Mediterranean anaemia: A study of 32 cases in Thailand. *Blood* 1954; 9: 1–23.
3. Rees DC, Styles L, Vichinsky EP, Clegg JB, Weatherall DJ. The Hemoglobin E Syndromes. *Ann N Y Acad Sci* 1998; 850:334-343.
4. Olivieri NF, Pakbaz Z, Vichinsky E. et al. Hb E/beta-thalassaemia: A common & clinically diverse disorder. *Indian J Med Res* 2011;134: 522-531.
5. Lachant NA, Tanaka KR. Case report: Dapsone-associated Heinz body haemolytic anaemia in a Cambodian woman with haemoglobin E trait. *Am J Med Sci* 1987; 294(5): 364–368.
6. Rees DC, Rochette J, Schofield C, Green B, Morris M, Parker NE et al. A novel silent post-translational mechanism converts methionine to aspartate in haemoglobin Bristol [β 67(E11) Val-Met-Asp]. *Blood* 1996; 88(1) 341–348.
7. Chen L, Liang L, Liao S, Huang Y, Liang L, Li Y. Compound heterozygotes of Hb Constant Spring and Hb Stanleyville

II in Hb E/ β 0-thalassemia. *Lab Med* 2021;59: e374-e376.

8. Jazeera S, Feroze M. Compound heterozygosity for hemoglobin E & B thalassemia: A family study from kerala. *IJMSDR* 2019; 2(3): 34-38.

9. Singh A, Kumar V, Singh M, Sahu P, Marwah S, Baweja G. A Rare case presentation of HbE/ β thalassemia. *APALM* 2020; 7(10): C-129-132.